

Is the inferior ST-segment elevation in anterior myocardial infarction reliable in prediction of wrap-around left anterior descending artery occlusion?

Emrah Bozbeyoğlu, Özlem Yıldırım Türk, Emre Aslanger¹, Barış Şimşek, Can Yücel Karabay, Olcay Özveren¹, Muzaffer Murat Değertekin¹

Department of Cardiology, Dr. Siyami Ersek Thoracic and Cardiovascular Surgery Training and Research Hospital; İstanbul-Turkey

¹Department of Cardiology, Yeditepe University Hospital; İstanbul-Turkey

ABSTRACT

Objective: In a subgroup of patients with the anterior wall myocardial infarction (MI), the electrocardiogram (ECG) records a concomitant inferior ST-segment elevation (STE), which is generally explained by a “wrap-around” left anterior descending (LAD) artery occlusion. However, recent evidence indicates that this may be due to a distal LAD occlusion, which may be irrelevant to the LAD length. We investigated the relationship between inferior ST-T changes in anterior MI and the presence of a wrap-around LAD.

Methods: Consecutive patients diagnosed with anterior MI due to an acute LAD occlusion were enrolled into the study. All ECGs were measured manually by a cardiologist, who was blinded to the angiographic outcomes. The site of the LAD occlusion was determined using multiple angiographic views. A wrap-around LAD was defined as a LAD artery from a post-reperfusion coronary angiogram that perfused at least one-fourth of the inferior wall of the left ventricle in the right anterior oblique projection.

Results: A total of 379 anterior MI cases were enrolled, and the final study population consisted of 259 patients. The presence of a wrap-around LAD was more frequent in patients presenting with inferior STE compared with patients without inferior STE (62.1% vs. 30.4%, $p=0.001$), however, this relationship was weak ($\Phi=0.211$). Inferior STE was more frequent in distal occlusions (22.9% vs. 4.3%, $p<0.001$), which showed a stronger relationship ($\Phi=0.285$). The polarity of the T-wave in lead III did not give any clues about the LAD anatomy.

Conclusion: Contrary to the popular acceptance, our results indicate that a wrap-around LAD cannot be reliably diagnosed by ECG. (*Anatol J Cardiol* 2019; 21: 253-8)

Keywords: coronary occlusion, electrocardiogram, myocardial infarction, ST segment elevation, wraparound

Introduction

In a subgroup of patients with anterior wall acute myocardial infarction (MI), the electrocardiogram (ECG) records concomitant inferior ST-segment elevation (STE) in addition to anterior STE. This phenomenon is generally explained by a “wrap-around” left anterior descending (LAD) artery occlusion, which also supplies the inferior wall of the left ventricle (1). The identification of patients with this anatomic substrate is clinically important because it has been shown that patients with wrap-around LAD artery occlusion have higher mortality and morbidity rates, both short term and long term (2-5). However, the traditional teaching that links the ischemic injury location

and several lead groups, such as inferior ischemia with inferior STE, is intuitive rather than evidence based, and this view has been challenged by recent studies (6, 7). For example, proximal LAD occlusions may cause anterior-lateral ST-segment depression, despite the extensive anterior wall involvement, due to the injury vector pointing to dominant basal septal segments (2, 6). On the other hand, distal LAD lesions may cause inferior STE without the inferior wall involvement due to the injury vector directed left and downwards (6, 7). Therefore, the assumption that inferior STE in patients with anterior MI is able to identify the wrap-around LAD occlusion representing the inferior wall involvement needs clarification. Other investigators proposed that inferior T-wave changes may indicate a larger infarct extending

Address for correspondence: Dr. Emre Aslanger, Yeditepe Üniversitesi Hastanesi, Kardiyoloji Anabilim Dalı; İçerenköy Mahallesi, Hastane Yolu Sokak, No: 102-104 Ataşehir, İstanbul-Türkiye
Phone: +90 532 510 97 96 E-mail: mr_aslanger@hotmail.com

Accepted Date: 21.01.2019 **Available Online Date:** 04.03.2019

©Copyright 2019 by Turkish Society of Cardiology - Available online at www.anatoljcardiol.com
DOI:10.14744/AnatolJCardiol.2019.09465



to the apical inferior wall, but there is no consensus on this (8). In the present study, we investigated the relationship between inferior ST-T changes in anterior wall MI and the presence of a wrap-around LAD.

Methods

The study was conducted at Dr. Siyami Ersek Training and Research Hospital, which has a large local transfer network with approximately 1500 patients with STEMI per year referred for primary percutaneous coronary intervention. Institutional review board approval was obtained; the study was judged to be exempt from a formal evaluation because it only involved the analysis of existing records.

All patients who were admitted with the diagnosis of acute anterior STEMI and underwent coronary angiography revealing acute occlusion of the LAD artery or its branches with thrombolysis in MI 0/1 flow from May 2017 to January 2018 were enrolled. Patients with a history of coronary artery by-pass grafting, left bundle branch block, or any other secondary repolarization abnormality (left ventricular hypertrophy with strain, the Wolff–Parkinson–White pattern, etc.), and a subacute ECG pattern with anterior T-wave inversion were excluded. For multiple ECGs on the same patient, the earliest ECG with maximum ST-segment deviation was used. ST-segment elevation was measured at 60 milliseconds after the J point (STE60) and approximated to closest 0.5 mm. Inferior ST-segment elevation was defined as the STE60>0 relative to the PQ segment in the all of three inferior leads. Terminal T-wave positivity in lead III was defined as at least >0.1 mm positive.

T-wave following ST-segment depression

A T-wave–QRS discordance in lead III was defined as the T-wave polarity opposite to the QRS polarity. All ECGs were measured manually by a cardiologist (E.A.), who was blinded to the angiographic and clinical outcomes.

The relation of the site of occlusion of the LAD artery and the origin of its first diagonal and septal branch was determined using multiple angiographic views. Any stenosis >70% (>50% for the left main coronary artery) affecting non-infarct-related arteries was defined as significant for the purpose of detecting a multivessel disease. A wrap-around LAD was defined as a LAD artery from a post-reperfusion coronary angiogram that perfused at least one-fourth of the inferior wall of the left ventricle in the right anterior oblique projection (9). Post-reperfusion ECG reports were reviewed, and ejection fraction measurements were noted. The peak troponin level was defined as the maximum troponin level recorded during hospital stay.

All measurements were presented as the mean and standard deviation. Baseline characteristics were summarized using standard descriptive statistics. The normal distribution of data was checked by the Shapiro–Wilk test and visual inspection

of histograms. For the comparison of baseline characteristics according to the wrap-around status of LAD, Student's t-test and the Mann–Whitney U test were used, as appropriate. Continuous ECG variables were compared using the Mann–Whitney U test. The comparisons among the presence of a wrap-around LAD, inferior STE, T-wave negativity in lead III, and occlusion site were undertaken by a chi-squared and Fischer's exact tests, as appropriate. The strength of association was represented with the phi (ϕ) coefficient. The predictive power of individual parameters was calculated by standard 2x2 tables using a chi-squared test, and sensitivity, specificity, likelihood ratios were presented. For continuous variables, specificity and sensitivity were calculated with respect to cut-off defined by the highest Youden's index obtained from a receiver operating characteristics curve analysis. Statistical analyses were performed with the SPSS (version 24.0; SPSS Inc., Chicago, IL, USA).

Results

A total of 379 anterior MI cases were enrolled during the study period. One hundred and five patients were excluded because one of the several reasons, including the left bundle branch block (n=19); secondary ST-T abnormalities, such as left ventricular hypertrophy, preexcitation syndrome (n=24); subacute ECG changes (n=41); and a history of coronary artery by-pass grafting (n=21). The presence of a wrap-around LAD could not be assessed in 15 patients due to insufficient post-reperfusion angiographic views. Therefore, the final patient population consisted of 259 patients. Baseline clinical characteristics are presented in Table 1. Electrocardiographic parameters are presented in Table 2.

In the whole study population, there were 88 patients with wrap-around LAD (34.3%), and 29 patients (11.5%) had STE in all inferior leads. Of these 29 patients with inferior STE, 13 had both a wrap-around LAD and distal occlusion combination (44.8%), nine had only distal LAD occlusion (31.0%), and five had only wrap-around LAD (17.2%). In the whole population, the presence of a wrap-around LAD was more frequent in patients presenting with inferior STE compared to patients presenting without inferior STE [18/29 (62.1%) vs. 70/230 (30.4%)]. Conversely, 20.5% of the patients (18/88) with wrap-around LAD had inferior STE, while only 6.4% of the patients (11/171) without wrap-around LAD had inferior STE ($p=0.001$, $\phi=0.211$).

When the LAD occlusion after first septal (S1) and diagonal artery (D1) take off was compared with more proximal occlusion sites, inferior STE was more frequent in distal occlusions [22/96 (22.9%) vs. 7/163 (4.3%)]. Distal occlusion was more frequent in patients with inferior STE compared to patients without inferior STE [22/29 (75.9%) vs. 74/230 (32.2%), $p<0.001$, $\phi=0.285$]. When the occlusion level was classified according to S1 [23/28 (82.1%) vs. 105/231 (45.4%), $p<0.001$, $\phi=0.217$], or D1 [22/28 (78.6%) vs.

Table 1. Baseline characteristics

	All (n=259)	Patients with wrap-around LAD (n=88)	Patients without wrap-around LAD (n=171)	P-value*
Demographic parameters				
Age, years	59±12	59±12	59±13	0.969
Male, n (%)	194 (75)	65 (74)	129 (75)	0.782
Hypertension, n (%)	113 (44)	34 (39)	79 (46)	0.245
Diabetes, n (%)	70 (27)	20 (23)	50 (29)	0.264
Smoker, n (%)	135 (52)	52 (59)	83 (49)	0.107
Prior MI, n (%)	32 (12)	9 (10)	23 (14)	0.455
Prior PCI, n (%)	32 (12)	9 (10)	23 (14)	0.455
Clinical parameters				
Heart rate, bpm	86±20	85±20	86±20	0.837 [†]
SBP, mm Hg	139±30	138±31	142±29	0.411
Hgb, g/dL	13.8±1.8	13.7±1.8	13.9±1.8	0.278 [†]
Creatinine, mg/dL	0.9±0.4	0.9±0.4	0.9±0.2	0.796 [†]
Peak troponin, ng/mL	34±50	36±60	34±45	0.528 [†]
LVEF, %	42±11	42±11	42±11	0.865 [†]
Time to ECG, minutes	95±116	97±103	95±120	0.641 [†]
Angiographic involvement				
LMCA, n (%)	5 (2)	1 (1)	4 (2)	0.505
LAD, n (%)	259 (100)	88 (100)	171 (100)	1.000
RCA, n (%)	72 (28)	23 (27)	47 (26)	0.485
Cx, n (%)	61 (24)	19 (24)	41 (22)	0.350
Occlusion distal to D1, n (%)	133 (51)	43 (52)	90 (55)	0.647
*P-value for comparison according to the presence or the absence of a wrap-around LAD artery anatomy. [†] Compared with the Mann-Whitney U test. Bpm - beats per minute; Cx - circumflex; D1 - first major diagonal artery; Hgb - hemoglobin; LAD - left anterior descending; LMCA - left main coronary artery; LVEF - left ventricular ejection fraction; MI - myocardial infarction; PCI - percutaneous coronary intervention; RCA - right coronary artery; SBP - systolic blood pressure				

111/231 (48.0%), $p=0.005$, $\phi=0.177$], or only the proximal segment and distal segment were compared [23/28 (82.1%) vs. 72/159 (45.3%), $p<0.001$, $\phi=0.263$], inferior STE was again significantly more frequent in distal compared to proximal occlusions, but associations were weaker. For all of the analyses mentioned above, taking STE in at least one of the inferior leads instead of the presence of STE in all inferior leads gives similar results with lower association values.

We also analyzed if there was a repeating pattern responsible for inferior ST-segment changes according to the occlusion site with reference to D1 and the presence of a wrap-around LAD as proposed by Sasaki et al. (1). In patients with a LAD occlusion proximal to D1, the presence of a wrap-around LAD did not have any effect on inferior STE; there was inferior STE in 12.5% (5/40) of the patients with wrap-around LAD and 11.0% (25/228) of the patients without it ($p=0.786$; $\phi=0.017$). Also, it does not have any effect on the ST deviation amplitude in any lead. In patients with a LAD occlusion distal to D1, the presence of a wrap-around LAD

had a significant effect on inferior STE; there was inferior STE in 31.0% (13/42) of the patients with wrap-around LAD and 11.1% (10/90) of the patients without it ($p=0.005$; $\phi=0.244$). Also, when the ST deviation is taken as a continuous variable, the absence compared with the presence of a wrap-around anatomy caused a more positive ST-segment in lead I (0.4 ± 0.8 vs. -0.2 ± 0.6 millimeters, respectively; $p<0.001$) and a more negative ST-segment in lead III (-0.3 ± 0.9 vs. 0.1 ± 0.9 millimeters, respectively; $p=0.005$) and aVF (-0.1 ± 1.1 vs. 0.4 ± 1.1 millimeters, respectively; $p=0.001$). Taking STE in any of the inferior leads instead of all inferior leads gave similar results.

To dissect the effects of the presence of a wrap-around LAD and distal LAD occlusion, we repeated analyses in patients with either wrap-around LAD or distal LAD occlusion. The presence of a wrap-around LAD predicted inferior STE with a sensitivity and specificity of 17.9% and 84.2%, respectively ($p=0.882$, $\phi=0.018$). On the other hand, distal LAD involvement predicted inferior STE with a sensitivity and specificity of 10.5% and 87.9%,

Table 2. Baseline electrocardiographic parameters

	All	Patients with wrap-around LAD*	Patients without wrap-around LAD*	P-value*
STE lead I, mm	0.3±0.8	0.1±0.7	0.4±0.7	0.008
STE lead II, mm	-0.2±1.0	-0.1±0.8	-0.3±0.9	0.033
STE lead III, mm	-0.5±1.2	-0.2±0.9	-0.7±1.2	0.001
STE aVR, mm	0.1±0.7	0.1±0.5	0.1±0.5	0.732
STE aVL, mm	0.4±1.0	0.1±0.7	0.5±1.0	0.012
STE aVF, mm	-0.4±1.2	-0.1±0.9	-0.6±1.1	0.005
STE V1, mm	0.8±1.0	0.8±1.0	0.8±0.9	0.753
STE V2, mm	2.5±2.2	2.3±2.1	2.5±2.1	0.365
STE V3, mm	2.2±2.6	2.4±2.2	2.2±2.4	0.372
STE V4, mm	2.4±2.6	2.4±2.7	2.3±2.3	0.775
STE V5, mm	1.6±2.4	1.6±2.3	1.5±2.1	0.553
STE V6, mm	0.7±1.8	0.7±1.7	0.7±1.5	0.621
Terminal positive T-wave in lead III, n (%)	82 (30)	23 (26)	57 (33)	0.235
Negative T-wave in lead III, n (%)	95 (34)	25 (28)	65 (39)	0.088
Discordant T-wave in lead III, n (%)	132 (48)	43 (49)	84 (51)	0.792

*P-value for comparison according to the presence or the absence of a wrap-around LAD artery anatomy.
STE - ST-segment elevation; LAD - left anterior descending

Table 3. Sensitivity, specificity, likelihood ratio, and association strength of individual parameters in predicting the presence of a wrap-around LAD

	Sensitivity	Specificity	Likelihood Ratio	95% CI	Φ coefficient	P-value
STE in lead II*	58.6	52.8	0.65	0.38-1.09	-0.101	0.108
STE in lead III*	31.0	86.5	0.57	0.32-1.04	-0.115	0.067
STE in AVF*	81.6	34.4	0.57	0.29-1.12	-0.103	0.101
STE in all inferior leads	20.5	93.4	3.62	1.62-8.07	0.207	0.001
STE in any inferior lead	43.2	71.3	1.88	1.09-3.22	0.145	0.020
Negative T-wave in lead III	28.4	60.8	0.61	0.35-1.07	-0.107	0.088
Terminal positive T-wave in lead III	26.1	66.7	0.70	0.40-1.25	-0.074	0.235
Occlusion distal to D1	51.8	45.1	0.88	0.52-1.50	-0.029	0.647

*Sensitivity, specificity, and Φ coefficient values were calculated with reference to cut-offs defined by the highest Youden's index (-0.25, 0.25, -0.75 for STE in lead II, lead III, and aVF, respectively).
CI - confidence interval; D1 - first major diagonal artery; STE - ST-segment elevation

respectively ($p=0.702$, $\phi=-0.025$). But when patients with both findings were compared with patients who had one or none of two findings, the sensitivity and specificity increased to 30.2% and 92.5%, respectively ($p<0.001$, $\phi=0.272$). Taking STE in any of the inferior leads instead of all inferior leads gave similar results.

The polarity of the T-wave in lead III also did not give any clues about the presence of a wrap-around LAD; only 28.4% (40/65) of the patients with a negative T-wave in lead III had a wrap-around LAD compared with 38.4% (63/164) of the patients without wrap-around LAD ($p=0.088$, $\phi=-0.107$). This was also true for discordant polarity of the QRS complex and T-wave in lead III [50.6% (84/166 vs. 48.8%) (43/88); $p=0.078$; $\phi=0.170$]. However, when the patients with a LAD occlusion proximal to D1

were compared to the patients with a LAD occlusion distal to D1, a slightly higher number of patients had a negative T-wave in lead III [45.6% (57/125) vs. 25.8% (34/132); $p=0.001$; $\phi=0.207$]. This was independent of the QRS-T-wave polarity discordance. Also, when patients with a ST-segment depression in lead III were compared to patients without this finding, a terminal positive T-wave did not predict the presence of a wrap-around LAD [28.8% (23/80) vs. 36.3% (65/179), $p=0.235$; $\phi=-0.074$], contrary to what was suggested by Porter et al. (8).

The sensitivity, specificity, likelihood ratio, and association strength of individual parameters in predicting the presence of a wrap-around LAD are presented in Table 3. Positive and negative predictive values of inferior STE for the presence of a

wrap-around LAD were 62.1% and 68.9%, respectively. For comparison, sensitivity, specificity, positive and negative predictive value, and the likelihood ratio of distal LAD occlusion for inferior STE were 17.4%, 95.2%, 79.3%, 52.0%, and 4.15 (95% confidence interval, 1.62–10.57, $p=0.001$, $\phi=0.198$), respectively.

Discussion

Our results show that the combination of a distal LAD occlusion and the presence of a wrap-around LAD is the most common scenario when there is concomitant inferior STE in anterior STEMI. This is followed by only distal LAD occlusion and lastly by only-wrap-around LAD anatomy. Distal occlusion showed a stronger association with inferior STE among these two factors, but the strength of association was moderate at best.

Several previous studies tried to explain inferior STE with inferior ischemia. Lew et al. (9) were first to report that a less inferior ST-segment depression is seen in patients with concomitant inferior ischemia due to wrap-around LAD or jeopardized collaterals supplying the inferior wall. Sapin et al. (10) found that a distal LAD occlusion and the presence of a wrap-around LAD was associated with inferior STE, but there were only seven patients with inferior STE in this study, and five had both of these findings. Similarly, Tamura et al. (11) reported that inferior STE was observed only in patients with both a distal LAD occlusion and wrap-around LAD, but again, there were only 12 patients with these findings. Sasaki et al. (1) suggested that the inferior lead ST-segment depression in the anterior wall AMI is more likely to occur in the absence of inferior MI due to a wrap-around LAD artery, which results in STE in the inferior leads. Alternatively, inferior STE may be caused by infarction of the inferior wall due to occlusion of a wrap-around LAD artery with an infarct-related lesion in LAD is distal to D1 (no reciprocal change caused by a high lateral wall, which may mask the ST-segment elevation). If a distal LAD lesion with a non-wrap-around anatomy or proximal LAD occlusion with wrap-around anatomy is present, no STE is expected in inferior leads due to the dominance of anteriorly directed injury vector in the former and cancellation of the opposing ischemia vectors in the latter.

Despite this appealing theoretical framework, many other factors may also combine to produce hardly predictable results. Ischemic myocardium subtended by the infarct-related artery may not exhibit a uniform degree of ischemia due to a heterogenous collateral network or differences in myocardial demand. The position of the heart in the thoracic cavity, the location of the ischemic area relative to Wilson's central terminal, the presence of previously infarcted areas, asymmetric distribution of the myocardial mass, or timing of the ischemic process may all influence the magnitude and the direction of the ischemic vector.

Indeed, our findings confirm and extend previous findings by reflecting this heterogeneity. The current study scanned a patient population approximately equal to the sum of the all of the previously mentioned studies (1, 9-11) and had a final population at least as twice as big as the largest one, which allowed dissecting

individual contributions of distal occlusion and the wrap-around anatomy. Inferior ischemia was not necessarily the primary cause of the inferior STE in at least some of the patients; rather, it is possibly caused by the ST vector directed inferiorly, anteriorly, and leftwards due to the mid-to-apical involvement of anterior and lateral walls (Fig. 1). In contrast to the suggestion by Sasaki et al. (1), the effect of basal parts seems to be so dominant whether LAD extends to inferior wall or does not affect inferior STE. When the LAD occlusion is distal, the presence of a wrap-around LAD seems to direct the ST vector more downward and cause more inferior STE. However, it was not possible to distinguish a wrap-around LAD from a non-wrap-around LAD by the ECG itself.

Finally, Porter et al. (8), claimed that a terminal positive T-wave following ST-segment depression in lead III represents inferior wall ischemia caused by proximal obstruction of a wrap-around LAD. Our data did not support this theory. Conversely,

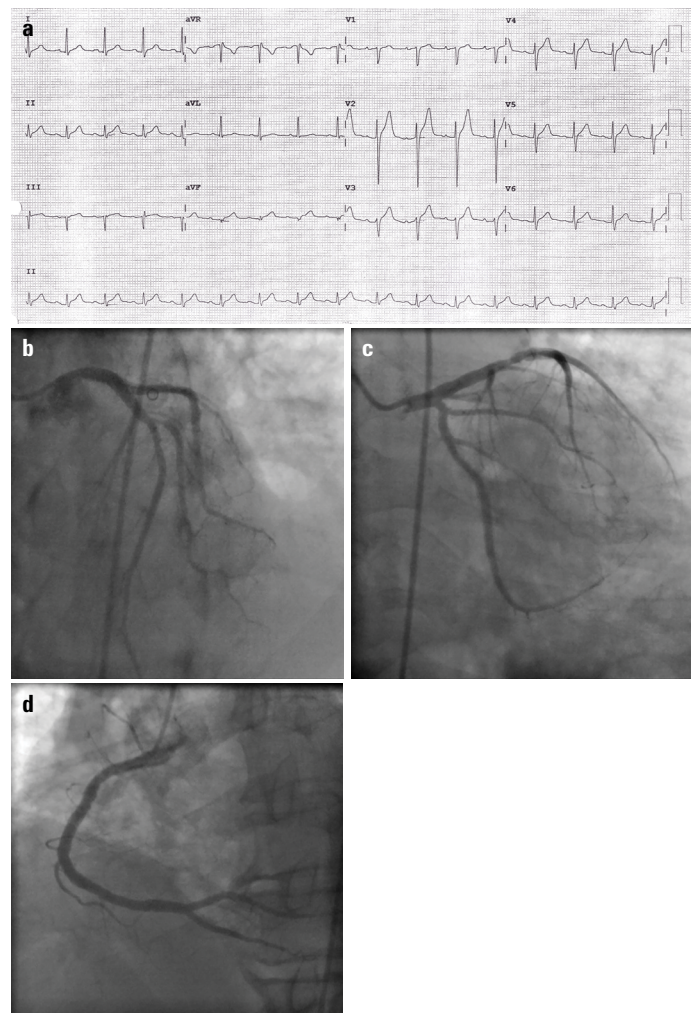


Figure 1. An example of concomitant inferior ST-segment elevation in anterior MI (a), which is not related to a wrap-around LAD artery causing inferior ischemia. Actually, LAD was not the wrap-around type (b), neither it was the culprit artery. Rather, the culprit artery was a diagonal artery (c), which is most possibly responsible for inferior ST-segment elevation caused by the injury vector directed toward inferior, anterior, and leftwards. The right coronary artery was normal (d)

patients with a proximal LAD occlusion seem to have a more frequent T-wave negativity in lead III, but the association was weak.

Study limitations

Our study is a retrospective chart review study, with all known limitations associated with bias. Because of the retrospective nature of the study, standard lead placement could not be confirmed. Although the determination of the presence or absence of the ST-segment elevation and the direction of T-wave is quite straightforward, an intra- or inter-rater variability analysis would have increased the reliability of ECG measurements. Some patients also had Cx and RCA stenoses, which might have some effect on ECG findings, but as the distribution of these lesions was homogenous in patients with and without a wrap-around LAD, we believe this effect is possibly ignorable. A direct indicator of inferior ischemia was not used in our study, which might be of value.

Conclusion

Concomitant inferior STE in anterior MI can be caused by the presence of a wrap-around LAD anatomy, distal LAD occlusion, or both. However, it is not possible to distinguish these three scenarios from ECG with confidence. Also, T-wave polarity does not have a sufficient diagnostic accuracy to identify a wrap-around LAD anatomy.

Conflict of interest: None declared.

Peer-review: Externally peer-reviewed.

Authorship contributions: Concept – E.A.; Design – E.A.; Supervision – E.B., Ö.Y., B.Ş., C.Y.K.; Fundings – None; Materials – None; Data collection &/or processing – E.B., Ö.Y., B.Ş., C.Y.K.; Analysis &/or interpretation – E.B., E.A.; Literature search – E.A., O.Ö.; Writing – E.A.; Critical review – E.A., O.Ö., M.M.D.

References

1. Sasaki K, Yotsukura M, Sakata K, Yoshino H, Ishikawa K. Relation of ST-segment changes in inferior leads during anterior wall acute myocardial infarction to length and occlusion site of the left anterior descending coronary artery. *Am J Cardiol* 2001; 87: 1340-5. [\[CrossRef\]](#)
2. Kobayashi N, Maehara A, Brener SJ, Généreux P, Witzensichler B, Guagliumi G, et al. Usefulness of the Left Anterior Descending Coronary Artery Wrapping Around the Left Ventricular Apex to Predict Adverse Clinical Outcomes in Patients With Anterior Wall ST-Segment Elevation Myocardial Infarction (from the Harmonizing Outcomes With Revascularization and Stents in Acute Myocardial Infarction Trial). *Am J Cardiol* 2015; 116: 1658-65. [\[CrossRef\]](#)
3. Kobayashi N, Maehara A, Mintz GS, Wolff SD, Généreux P, Xu K, et al. Usefulness of the Left Anterior Descending Artery Wrapping Around the Left Ventricular Apex to Predict Adverse Clinical Outcomes in Patients With Anterior Wall ST-Segment Elevation Myocardial Infarction (an INFUSE-AMI Substudy). *Am J Cardiol* 2015; 115: 1389-95. [\[CrossRef\]](#)
4. Ilija R, Weinstein JM, Wolak A, Gilutz H, Cafri C. Length of left anterior descending coronary artery determines prognosis in acute anterior wall myocardial infarction. *Catheter Cardiovasc Interv* 2014; 84: 316-20. [\[CrossRef\]](#)
5. Sönmez O, Vatankulu MA, Kayrak M, Karaarslan Ş, Altunbaş G, Özdemir K, et al. Effect of termination of the left anterior descending coronary artery (wrapped or non-wrapped property) on tissue Doppler echocardiography findings in patients with anterior myocardial infarction: an observational study. *Anatol J Cardiol* 2012; 12: 465-71. [\[CrossRef\]](#)
6. Fiol M, Carrillo A, Cygankiewicz I, Velasco J, Riera M, Bayés-Genis A, et al. A new electrocardiographic algorithm to locate the occlusion in left anterior descending coronary artery. *Clin Cardiol* 2009; 32: E1-6.
7. Bayés de Luna A. *Clinical Electrocardiography: A Textbook. Ischemia and necrosis*. 4th ed. West Sussex: Wiley-Blackwell Publishing; 2012. p.216-76. [\[CrossRef\]](#)
8. Porter A, Sclarovsky S, Ben-Gal T, Herz I, Solodky A, Sagie A. Value of T-wave direction with lead III ST-segment depression in acute anterior wall myocardial infarction: electrocardiographic prediction of a "wrapped" left anterior descending artery. *Clin Cardiol* 1998; 21: 562-6.
9. Lew AS, Hod H, Cercek B, Shah PK, Ganz W. Inferior ST segment changes during acute anterior myocardial infarction: a marker of the presence or absence of concomitant inferior wall ischemia. *J Am Coll Cardiol* 1987; 10: 519-26. [\[CrossRef\]](#)
10. Sapin PM, Musselman DR, Dehmer GJ, Cascio WE. Implications of inferior ST-segment elevation accompanying anterior wall acute myocardial infarction for the angiographic morphology of the left anterior descending coronary artery morphology and site of occlusion. *Am J Cardiol* 1992; 69: 860-5. [\[CrossRef\]](#)
11. Tamura A, Kataoka H, Nagase K, Mikuriya Y, Nasu M. Clinical significance of inferior ST elevation during acute anterior myocardial infarction. *Br Heart J* 1995; 74: 611-4. [\[CrossRef\]](#)