

An infant with severe mitral insufficiency and collapse of the left lung due to hammock mitral valve: emergency mitral valve replacement

Hamak mitral kapağa baęlı ağır mitral yetersizlięi ve sol akcięer kollapsı gelişen bir infant: Acil mitral kapak replasmanı

F.Sedef Tunaoęlu, Velid Halid, Rana Olguntürk, Nazan Özbarlas**, Serdar Kula, Volkan Sinci**

From Departments of Pediatric Cardiology and *Cardiovascular Surgery, Medical Faculty, Gazi University, Ankara, Turkey

** Department of Pediatric Cardiology, Medical Faculty, Çukurova University, Adana, Turkey

Introduction

Congenital mitral valve disease is uncommon in children. It has a wide spectrum of morphologic abnormalities and is frequently associated with other cardiovascular anomalies (1). A small percentage of patients with valve stenosis or insufficiency become severely symptomatic during early infancy and need surgical intervention (2). Usually surgical therapy for congenital mitral valve disease is always delayed until severe symptoms develop despite ongoing medical therapy. Although results are improved in recent years, surgical treatment is still a last resort (3).

We report a case with severe mitral regurgitation and mild mitral stenosis due to hammock mitral valve. Because of the progression of the symptoms of heart failure and collapsed left lung while on the digoxin, diuretic and angiotensin converting enzyme inhibitors therapy, she underwent valve replacement.

Case report

A 6-month-old girl was admitted to hospital because of dyspnea. She had been treated with digoxin and furosemide for heart failure since two months of age. Despite the anticongestive therapy, pericardial effusion and collapse of the left lung developed, and she was transferred to our hospital. There was no parental consanguinity in her family history, and she has two healthy brothers.

Her physical examination revealed: weight of 5.7 kg (<3 centile), height of 67cm (10 centile), heart rate:168/min, respiratory rate:40/min, intercostal retractions, Gallop rhythm, down and leftward rotated apex.

On auscultation an accentuation in the pulmonary component of the S2, high frequency pansystolic murmur at the apex

with radiation to axilla and back, low frequency apical diastolic murmur and third heart sound were heard. The breath sounds were absent over the left thorax, and crackling rales were heard at the right middle and lower zones. Her liver was palpated 3 cm below the right costal margin.

Her electrocardiogram demonstrated left atrial dilatation and biventricular hypertrophy. Chest X-ray (Fig. 1) and tomography showed the collapsed left lung, cardiomegaly, severe left atrial dilatation, left sided pleural effusion.

Echocardiographic examination (Fig. 2a and 2b) revealed an increase in left ventricular systolic function (Fractional shortening: 52.29 %, Ejection fraction: 92.00%), increased left atrial (3.98 cm, normal ranges: 1.50-2.10 cm) and left ventricular dimensions (2.79 cm, normal ranges:1.80-2.30 cm), thickened anterior mitral leaflet, very short chordae tendinea, severe mitral regurgitation, mild mitral stenosis, enlarged pulmonary artery and pericardial fluid in the pericardial space. Cardiac catheterization and angiography confirmed the presence of a large left atrium and abnormal mitral valve and elevated pulmonary wedge pressure of 20 mm Hg with left ventricle end diastolic pressure (18 mmHg).

Despite intensive medical management of heart failure including digoxin, diuretic, angiotensin converting enzyme inhibitor, carnitine and respiratory support, she was still symptomatic. Due to the intractable heart failure and the collapse of her left lung, surgical therapy was applied.

Surgical technique

Through median sternotomy incision, cardiopulmonary bypass and circulatory arrest using cold crystalloid cardioplegic solution, the left atrium was opened. The mitral valve was deformed with hypertrophied anterior papillary muscle and short posterior papillary muscle with very short chordae tendinea (Fig. 3).

It was considered not feasible to repair such a valve and after resection of the valve No.18 Carbomedics bileaflet metallic valve was replaced. Intra- and postoperative courses were uneventful. To keep her INR values in the range of 2 to 2.5, warfarin was given for anticoagulation. Her chest X-ray (Fig. 4) showed regression of the left atrial dilatation and cardiomegaly, and bilateral equally ventilated lungs. Echocardiographic examinations demonstrated regression of the left atrial and ventricular dimensions, competent prosthetic mitral valve and no regurgitation. She was discharged on the seventh post operative day, while on digoxin and warfarin.

Discussion

Isolated mitral valve disease is uncommon in children. Congenital mitral valve diseases commonly associated with obstructive malformation of left ventricular outflow tract, valvular and subvalvular aortic stenosis and coarctation of aorta (4). Our pa-

tient's mitral valve structure was determined as hammock valve at echocardiography, and the diagnosis was proven by the operation. In this pathology, mitral valve leaflets are thickened with shortened or absent chordae tendinea and they appear as directly connected to papillary muscles resulting in limited coaptation of mitral valve leaflet and predominant mitral insufficiency, however mitral stenosis may be present. The management of such a condition is difficult, so mitral valve replacement is often required (3). Our patient had severe mitral insufficiency and mild mitral stenosis. Usually surgical treatment for congenital mitral valve disease is delayed until severe symptoms develop despite medical treatment. Unfortunately this period was very short in our case. Although our case had isolated mitral valve anomaly (hammock valve), this anomaly caused severe mitral insufficiency and left atrial dilatation. The reasons for her early operation are intractable heart failure due to severe mitral insufficiency and respiratory failure due to the left lung collapse by the compression of the huge left atrium. Uva et al (5) reported 20 patients less than 1 year of age (mean 6.6 ± 3.4 months) who were operated for congenital mitral insufficiency or mitral stenosis. They have only one baby aged 8.5 months old who underwent mitral valve replacement because of hammock mitral valve causing mitral stenosis. There are some reports about the mitral valve replacement in the first year of life (2,6-8). However, the cases in these studies have wide spectrum of cardiac malformations and usually have severe mitral stenosis.

Mitral valve replacement has special technical and clinical difficulties in infants. One of them is the small annular size of the valve, and the other is the maintenance of the adequate anticoagulant therapy (7,9). Our patient's mitral valve annulus was suitable for the No.18 Carbomedics bileaflet prosthetic valve. We preferred to use the mechanical valve because of their durability that enabled a widespread acceptance for left-sided valve replacement in children (10). Tissue valve prostheses are no longer preferred because of their early degenerative calcification resulting in valve failure (6,9).

Mechanical valve prostheses require additional therapy in order to reduce the incidence of thromboembolism and such

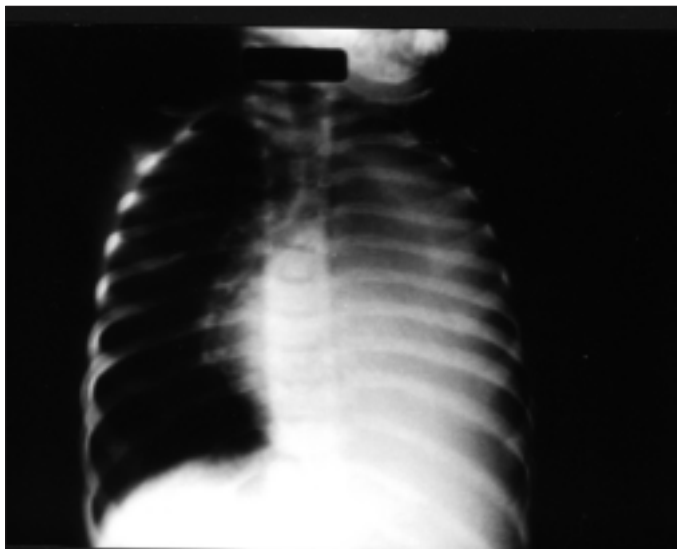


Figure 1. Preoperative chest X-ray

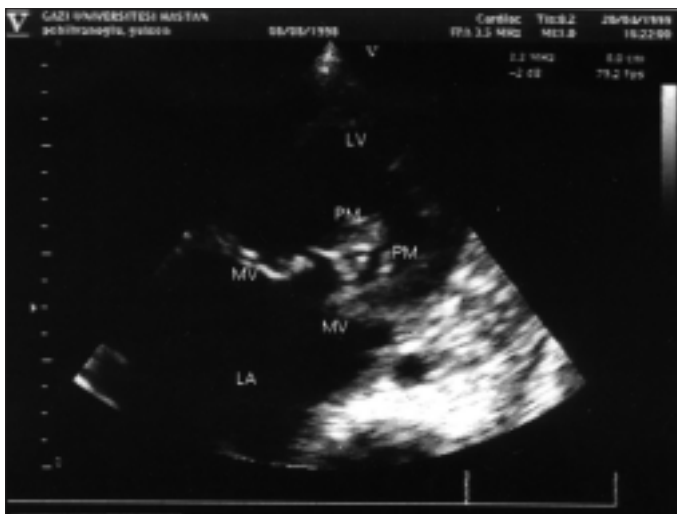

Figure 2a. Parasternal long axis view of hammock mitral valve. Anterior papillary muscle is hypertrophic. The mitral leaflets are dense. The chordae tendinea of mitral leaflets are very short

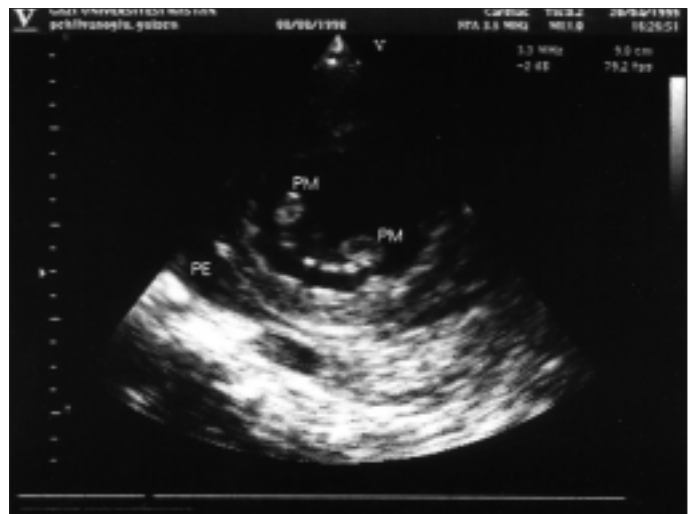

Figure 2b. Short axis view of hammock valve. Two papillary muscles are seen

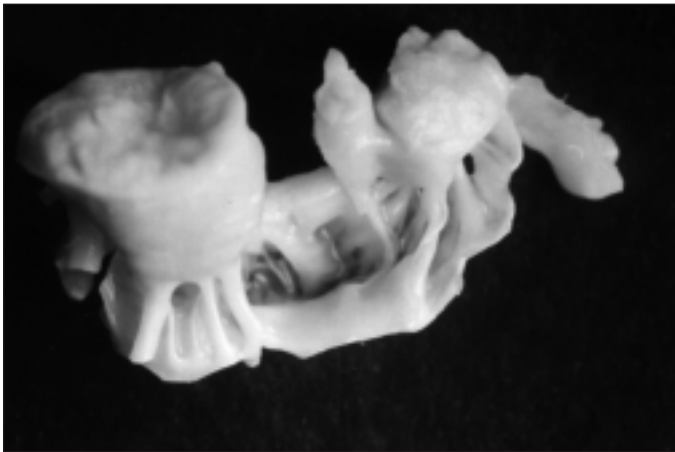


Figure 3. Resected mitral valve of patient

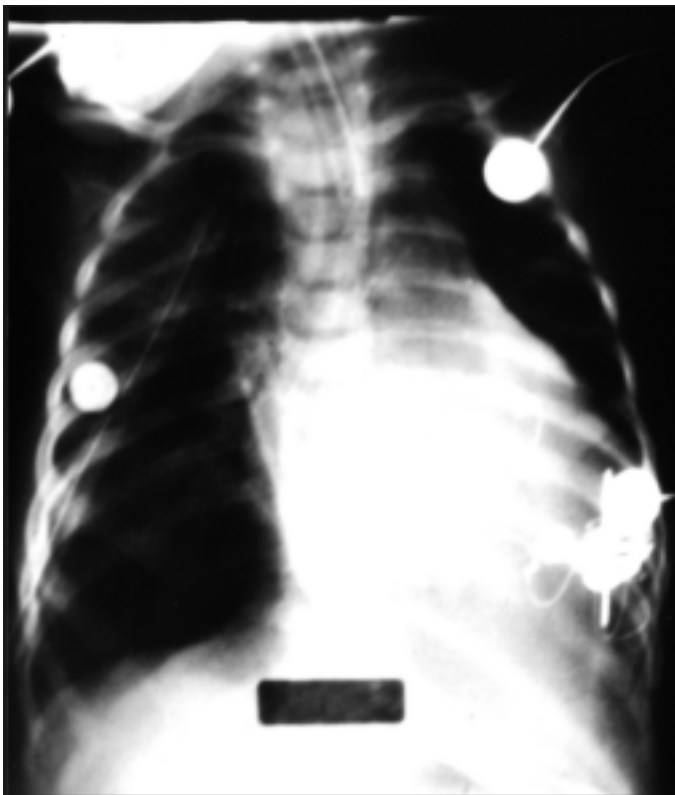

Figure 4. Postoperative chest X-ray

therapies create potential problems such as the development of serious haemorrhages that are more frequent in children. Our patient was anticoagulated with warfarin. We will decide further the type of therapy according to patient's follow-up.

Although results have improved in recent years, surgical treatment is still the last resort. The technique would have been easier by the availability of a better variety and size range of implantable prostheses.

However, when the indications like intractable heart failure develops, surgical treatment must be applied without delay (3). Late functional results of surgery are good, and most patients lead a normal life afterwards (2).

In our case the need for second mitral valve replacement should be considered to select an appropriate valve size in the future as she grows up.

References

1. Smallhorn J, Macartney FJ. Mitral valve anomalies and supravulvar mitral ring. In: Anderson RH, Baker EJ, Macartney FJ, Rigby ML, Shinebourne EA, Tynan M, editors. *Pediatric Cardiology*. Edinburgh: Churchill Livingstone; 2002. p. 1135-77.
2. Duncan WJ, Bharadwaj B, Tyrell MJ. Mitral valve replacement in the neonate: a report of two cases. *Pediatr Cardiol* 1984; 5: 307-12.
3. Baylen BG. Congenital mitral insufficiency. In: Allen HD, Clark EB, Gutgesell HP, Driscoll DJ, editors. *Moss and Adams Heart Disease in Infants, Children, and Adolescents Including the Fetus and Young Adult*. Baltimore: Williams&Wilkins; 2001. p. 924-37.
4. Park MK. *The Pediatric Cardiology Handbook*. Saint Louis; Mosby Year book: 1991. p. 243.
5. Uva MS, Galletti L, Gayet FL, Piot D, Serraf A, Bruniaux J, et al. Surgery for congenital mitral valve disease in the first year of life. *J Thorac Cardiovasc Surg* 1995; 109: 164-76.
6. Zweng TH, Bluett MK, Mosca R, Callow LB, Bove EL. Mitral valve replacement in the first 5 years of life. *Ann Thorac Surg* 1989; 47: 720-4.
7. Kadoba K, Jonas RA, Mayer JE, Castaneda AR. Mitral valve replacement in the first year of life. *J Thorac Cardiovasc Surg* 1990; 100: 762-8.
8. Zias EA, Mavroudis C, Backer CL, Kohr LM, Gotteiner NL, Rocchini AP. Surgical repair of the congenitally malformed mitral valve in infants and children. *Ann Thorac Surg* 1998; 66: 1551-9.
9. Solymar L, Rao S, Mardini MK, Fawzy ME, Guinn G. Prosthetic valves in children and adolescents. *Am Heart J* 1991; 121: 557-68.
10. de Luca L, Vitale N, Giannolo B, Cafarella G, Piazza L, Cotrufo M. Mid-term follow-up after heart valve replacement with CarboMedics bi-leaflet prostheses. *J Thorac Cardiovasc Surg* 1993; 106: 1158-65.