

Myocardial infarction caused by compression of the left coronary artery by an aortic pseudoaneurysm

Jan Roček*, Michal Smetana**,¹ Hana Línková**,¹,
 Jakub Sulženko**,¹ Petr Kačer*.¹

Departments of *Cardiac Surgery, and **Cardiology, University Hospital Královské Vinohrady; Prague-Czech Republic
¹3rd Faculty of Medicine, Charles University; Prague-Czech Republic

Introduction

Aortic pseudoaneurysm is most commonly seen as a complication of ascending aorta replacement, appearing several years after the operation (1). Pseudoaneurysm after cardiac catheterization, on the other hand, is very unusual. We present a rare case of successful management of a myocardial infarction caused by aortic pseudoaneurysm more than 50 years after surgical closure of a ventricular septal defect.

Case Report

A 64-year-old woman who had undergone surgical closure of a congenital ventricular septal defect at the age of 11 years was examined in our cardio center for long-term worsening exertional dyspnea. Echocardiography revealed a residual hemodynamically insignificant left-to-right shunt after the ventricular septal defect closure. Both ventricles had normal function without wall motion abnormalities, and no significant valve disease was found. Computed tomography (CT) angiography was performed, which revealed an aneurysm of the left aortic sinus (27×22×25 mm) compressing the pulmonary artery and slightly elevating the left coronary artery trunk. The patient was hospitalized for comprehensive investigations, including selective coronarography.

A few weeks later the patient was acutely admitted for an anterior ST-segment elevation myocardial infarction. Selective coronarography was performed, which showed pseudoaneurysm of the left aortic sinus caused significant compression and 90% stenosis of the left coronary artery (Fig. 1a) (2). Echocardiography showed moderate left ventricular dysfunction with an ejection fraction of 30%–35% and severe hypokinesis of the apex and apical part of the anterolateral wall of the left ventricle. At this point, we had to decide whether to perform a high-risk acute cardiac surgery (redo after the ventricular septal defect closure) at the risk of delaying the treatment of ongoing myocardial ischemia or perform a high-risk endovascular intervention. Finally, ad hoc percutaneous coronary intervention of the left coronary artery with stent implantation was performed (3).

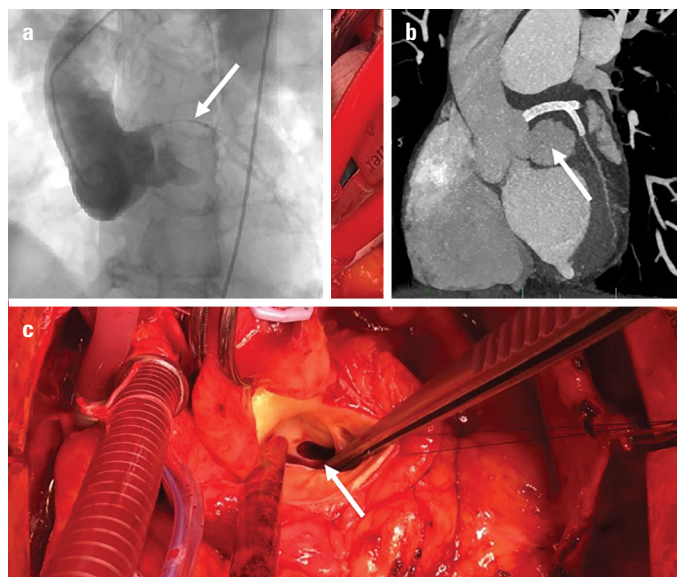


Figure 1. (a) (Coronarography)-pseudoaneurysm of the left coronary sinus causes significant stenosis of the left coronary artery. (b) (CT angiography)-pseudoaneurysm of the left coronary sinus, stented left coronary artery. (c) (Perioperative)-entry to the pseudoaneurysm with smooth edges

After stabilization, CT angiography was performed on the patient, and a partially thrombosed pseudoaneurysm of 28×24×27 mm in size compressing the left coronary artery was found. Ten days later, the patient developed a transient chest pain without a change in the levels of cardiac markers or echocardiography changes. A follow-up CT angiography revealed progressive increase in the size of pseudoaneurysm to 42×33×34 mm (Fig. 1b). Echocardiography showed normal function of both ventricles, an ejection fraction of 60%, and no wall motion abnormalities. For these reasons, early surgical treatment was scheduled.

The heart was approached through a median sternotomy, and after releasing its adhesions, total cardiopulmonary bypass was initiated, and after an aortic cross-clamp, a dose of del Nido cardioplegia solution was administered. After aortotomy, the aortic root was revised. The stent used in the previous percutaneous coronary intervention was found protruding 3 mm from the orifice of the left coronary artery. A partially thrombosed pseudoaneurysm opening into the left aortic sinus was identified. Its orifice was located between the left and right cusps and had a diameter of about 12 mm and surprisingly smooth edges characteristic of an old puncture site (Fig. 1c). A small residual ventricular septal defect was identified under the right cusp. However, its closure was not possible without the cusp retraction. An aortic valve replacement had to be performed. A mechanical prosthesis was used for its low profile to avoid stent dislocation in the left coronary artery. Bovine pericardium was used for closure of the orifice of the pseudoaneurysm (Fig. 2) (4). Another dose of cardioplegia solution was administered into the right coronary artery and into the coronary sinus to avoid

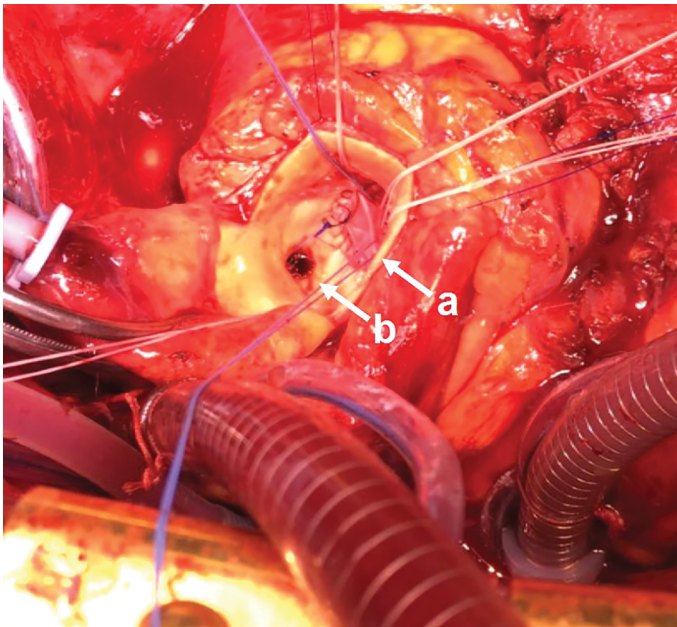


Figure 2. Perioperative. (a) Closure of the pseudoaneurysm using bovine pericardium. (b) Orifice of the left coronary artery with protruding implanted stent

dislocation of the stent in the left coronary artery. The operation and primary wound closure were performed successfully. The postoperative course was uncomplicated, and the patient was discharged after two weeks.

Discussion

The main question in this case is why the pseudoaneurysm occurred. The morphology of its orifice in the coronary sinus resembled a chronic aortic wall defect. The patient told us that she had undergone a cardiac catheterization several days after the closure of the ventricular septal defect because of a persistent murmur and a residual shunt. We assume that injury during this catheterization in the patient's childhood, together with the development of arterial hypertension and loss of aortic elasticity that occurred later in the patient's life led to the development of the pseudoaneurysm. The surrounding fibrous adhesions of the aorta as a result of the previous surgery may have limited the rupture of the aortic wall and prevented potentially catastrophic outcomes (5).

Conclusion

Occlusion of the coronary artery by a pseudoaneurysm can lead to myocardial infarction. In a patient with pericardial adhesions after cardiac surgery, percutaneous coronary intervention should be considered before surgical revascularization (1-3). The risk of delaying surgical treatment of the myocardial ischemia is higher than the risk of performing endovascular procedure.

Acknowledgement: The authors would like to thank Dr. Adam Whitely for proofreading the manuscript.

Funding: This work was supported by Charles University Research Programme UNCE-MED 02.

Informed consent: The patient has given informed consent to the publication of this case report, including the posting of images taken during the operation and the results of imaging methods.

References

1. Yalçın AA, Kahraman S, Yıldırım A, Erkanlı K. An uncommon percutaneous treatment of aortic pseudoaneurysm. *Anatol J Cardiol* 2018; 20: 132-3. [CrossRef]
2. Nemeč J, Garratt KN, Schaff HV, Goodwin M, Morrow D, Brown A, Khandheria BK. Asymptomatic occlusion of the left main coronary artery by an aortic pseudoaneurysm. *Mayo Clin Proc* 2000; 75: 1205-8.
3. Mishra A, Sirasena T, Slaughter R, Pohliner P, Walters DL. Percutaneous treatment of an occlusive left main pseudoaneurysm: a role for multimodality imaging. *Cardiovasc Revasc Med* 2011; 12: 133.
4. Yue H, Qin X, Zhang T, Wu Z. Chronic aortic pseudoaneurysm of aortic root with occluded right coronary artery after trauma: A case report. *Anatol J Cardiol* 2018; 20: E1-2. [CrossRef]
5. Lacalzada-Almeida J, De la Rosa-Hernández A, Izquierdo-Gómez MM, García-Niebla J, Hernández-Betancor I, Bonilla-Arjona JA, et al. Compression of the right coronary artery by an aortic pseudoaneurysm after infective endocarditis: an unusual case of myocardial ischemia. *Clin Interv Aging* 2017; 13: 9-11. [CrossRef]

Address for Correspondence: Petr Kačer, MD,

Department of Cardiac Surgery,
University Hospital Královské Vinohrady;
Prague-Czech Republic

Phone: +420 726 773 422/260

E-mail: petr.kacer@fnkv.cz

©Copyright 2020 by Turkish Society of Cardiology - Available online

at www.anatoljcardiol.com

DOI:10.14744/AnatolJCardiol.2020.01564



A proximal right coronary artery occlusion presenting with ST-segment depression in leads II, III, and aVF

İD Göktuğ Savaş, İD Selçuk Yazıcı, İD Sait Terzi
Department of Cardiology, Siyami Ersek Thoracic and Cardiovascular
Surgery Training and Research Hospital; İstanbul-Turkey

Introduction

The first electrocardiogram (ECG) finding during myocardial ischemia is the deviation of the ST-segment. The overall ST vector is usually shifted in the direction of the ischemic zone that can be localized by the 12-lead ECG. However, in some cases, it is subject to limitations and exceptions (1). We present a patient