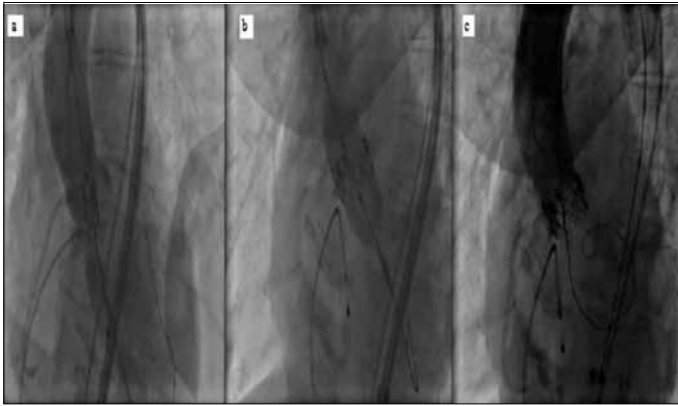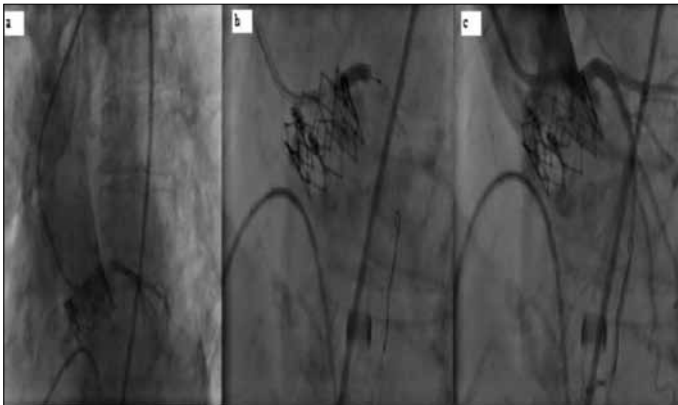


**Figure 1.** This figure shows positioning of bioprosthetic aortic valve in the mid-line of native aortic valve (a), opening phase of the valve (b) and missing of left main coronary artery on control aortography (c)



**Figure 2.** This figure shows cannulation of left main coronary artery (a), stent placement (b) and final patency of left main coronary system (c)

descending artery. After the balloon predilatation, the patient became hemodynamically stable and 4.0x15mm Zotarolimus eluting stent was implanted in the LMCA (Fig. 2 and Video 3, 4). PredischARGE echocardiography showed normal left ventricular contractility and ejection fraction and normal functioning prosthetic valve. The patient was discharged at fifth day after procedure without cardiovascular and cerebral complication.

Although CoreValve ReValving system has been hopefully expected to protect coronary ostium due to its large stent's gap and shape, this dreadful complication may be seen with this system (3). In addition, trans-apical aortic valve replacement may cause LMCA occlusion as well as transfemoral system (4). All types of acute LMCA occlusion following TAVI must be immediately treated with stent implantation, and sometimes it may require Tandem Heart support (5).

**Sinan Dağdelen, Hasan Karabulut\*, Cem Alhan\***  
From Departments of Cardiology and \*Cardiovascular Surgery,  
Faculty of Medicine, Acibadem University, Istanbul-Turkey

## References

1. Lefèvre T, Kappetein AP, Wolner E, Nataf P, Thomas M, Schächinger V, et al. One- year follow-up of the multi-centre European PARTNER transcatheter heart valve study. *Eur Heart J* 2011; 32: 148-57. [CrossRef]
2. Stabile E, Sorropago G, Cioppa A, Cota L, Agrusta M, Lucchetti V, et al. Acute left main obstructions following TAVI. *EuroIntervention* 2010; 6: 100-5. [CrossRef]

3. Saia F, Marrozzini C, Marzocchi A. Displacement of calcium nodules of the native valve as a possible cause of left main occlusion following transcatheter aortic valve implantation. *J Invasive Cardiol* 2011;23:E106-9.
4. Crimi G, Passerone G, Rubartelli P. Trans-apical aortic valve implantation complicated by left main occlusion. *Catheter Cardiovasc Interv* 2011;78:656-9. [CrossRef]
5. Kapadia SR, Svensson L, Tuzcu EM. Successful percutaneous management of left main trunk occlusion during percutaneous aortic valve replacement. *Catheter Cardiovasc Interv* 2009;73:966-72. [CrossRef]

**Address for Correspondence/Yazışma Adresi:** Dr. Sinan Dağdelen

Acibadem Üniversitesi Tıp Fakültesi, Acibadem Cad. Tekin Sok. No:18, Kadıköy  
Acibadem Hastanesi, İstanbul- Türkiye

Phone: +90 216 544 41 23 Fax: +90 216 325 87 59

E-mail: sinandagdelen@hotmail.com

**Available Online Date/Çevrimiçi Yayın Tarihi:** 03.12.2011

©Telif Hakkı 2011 AVES Yayıncılık Ltd. Şti. - Makale metnine [www.anakarder.com](http://www.anakarder.com) web sayfasından ulaşılabilir.

©Copyright 2011 by AVES Yayıncılık Ltd. - Available on-line at [www.anakarder.com](http://www.anakarder.com)  
doi:10.5152/akd.2011.204

## Emergency double-valve repair during acute aortic dissection type A operation

### *A tipi akut aort disseksiyonu onarımı sırasında acil çift-kapak tamiri*

Acute aortic dissection type A (AADTA) is a life-threatening disease. Complications such as aortic rupture, cardiac tamponade and acute aortic regurgitation require immediate surgical intervention. Replacement of the aortic valve (AV), root and ascending aorta with a composite graft carrying a mechanical valvular prosthesis is one of the most used treatment option especially if the aortic root is severely impaired, but it is accompanied by disadvantages of mechanical valve prostheses, such as thromboembolic events and hemorrhage due to lifetime anticoagulation. There are several AV sparing operations for replacement of the ascending aorta to overcome the shortcomings of mechanical prosthesis. The Cabrol type of commissure sutures with or without resuspension of the valve is one of them, which are perfectly suited for patients with AADTA (1).

The advantages of mitral valve (MV) repair over prosthetic valve replacement such as better preservation of left ventricular function and lower incidence of valve-related events are also well-documented. Nowadays, the procedure is the gold standard especially for degenerated MI. In contrast to MV repair, AV repair still poses significant technical challenges. Svensson et al. (1) reported 388 aortic root preserving procedures that 140 (36.1%) of them were after AADTA. They performed 197 leaflet repair procedures which 158 (80.7%) of them were Cabrol/Trusler type of commissure sutures with excellent early results. Kallenbach et al. (2) reported results of 22 emergency valve sparing aortic root reconstruction by reimplantation technique with %14 perioperative deaths and excellent results during follow-up. 36 patients with valve-sparing aortic root remodeling/reimplantation for AADTA was reported by Erasmi et al. (3) with excellent midterm aortic valve function. There was no concomitant MV repair in any above reports.

In contrast, mitral insufficiency is present in 68%-91% of patients with Marfan's syndrome who are more prone to aortic dissection. Forteza et al. (4) reported 37 aortic valve-sparing procedures in Marfan's syndrome with good short and midterm results where 6 (16%) concomitant mitral valve repairs were done. In their series, none of them were under the diagnosis of AADTA. Another report by Kallenbach et al. (5)

described 59 aortic valve sparing procedures in Marfan's syndrome patients of whom 7 had mitral repair. There were also 4 AADTA patients in the report but they did not mention the concomitant double valve repair in any of acute dissection patient (5).

There are only a few papers, which report combined aortic and mitral valve repair and durability even under elective conditions. Gillinov et al. (6) reported an acceptable late survival, an excellent freedom from valve-related morbidity, but limited long-term durability with ten-year-freedom from reoperation of 65%. The risk factors for valve-related reoperation they reported were aortic stenosis, rheumatic valve disease, and anterior mitral leaflet pathology. Kazui et al. (7) reported excellent early results with the 30-day survival rate were 100% and there were no valve related morbidity during a one-year follow-up.

In our institution, mitral valve repair is attempted first regardless to the etiology of mitral insufficiency and the Cabrol commissure sutures have been the mainstay of aortic valve repair especially after AADTA.

Surgeons are generally more familiar with valve replacement then reconstruction. Prolonged operation time with expansion of aortic cross clamp and extracorporeal circulation time is another potential drawback for application of reconstructive techniques especially under AADTA. The benefits of double-valve repair should overcome the ongoing discussions and surgeons should increase their experiences with reconstructive techniques in elective cases. In conclusion, we believe that valve repair should be tried even in emergency conditions and double valve involvement whenever it is possible.

**Altuğ Tuncer, Taylan Adademir**  
**From Clinic of Cardiovascular Surgery, Kartal Koşuyolu Yüksek**  
**İhtisas Education and Research Hospital, İstanbul-Turkey**

## References

1. Svensson LG, Deglurkar I, Ung J, Pettersson G, Gillinov AM, D'Agostino RS, et al. Aortic valve repair and root preservation by remodeling, reimplantation, and tailoring: technical aspects and early outcome. *J Card Surg* 2007; 22: 473-9. [CrossRef]
2. Kallenbach K, Pethig K, Leyh RG, Baric D, Haverich A, Harringer W. Acute dissection of the ascending aorta: first results of emergency valve sparing aortic root reconstruction. *Eur J Cardiothorac Surg* 2002; 22: 218-22. [CrossRef]
3. Erasmi AW, Stierle U, Bechtel JFM, Schmidtke C, Sievers HH, Kraatz EG. Up to 7 years' experience with valve-sparing aortic root remodeling/reimplantation for acute type A dissection. *Ann Thorac Surg* 2003; 76: 99-104. [CrossRef]
4. Forteza A, De Diego J, Centeno J, López MJ, Pérez E, Martín C, et al. Aortic valve-sparing in 37 patients with Marfan syndrome: midterm results with David operation. *Ann Thorac Surg* 2010; 89: 93-6. [CrossRef]
5. Kallenbach K, Baraki H, Khaladj N, Kamiya H, Hagl C, Haverich A, et al. Aortic valve-sparing operations in Marfan syndrome: what do we know after a decade? *Ann Thorac Surg* 2007; 83: 764-8. [CrossRef]
6. Gillinov AM, Blackstone EH, White J, Howard M, Ahkrass R, Marullo A, et al. Durability of combined aortic and mitral valve repair. *Ann Thorac Surg* 2001; 72: 20-7. [CrossRef]
7. Kazui T, Kin H, Izumoto H, Nakajima T, Ishihara K, Kawazoe K. Combined aortic and mitral valve repair. *Asian Cardiovasc Thorac Ann* 2003; 11: 319-22.

**Address for Correspondence/Yazışma Adresi:** Dr. Altuğ Tuncer  
Denizer Caddesi, Cevizli Kavşağı No:2 Cevizli Kartal İstanbul-Türkiye  
Phone: +90 216 459 44 40 Fax: +90 216 459 63 21  
E-mail: matuncer@gmail.com

**Available Online Date/Çevrimiçi Yayın Tarihi:** 03.12.2011

©Telif Hakkı 2011 AVES Yayıncılık Ltd. Şti. - Makale metnine [www.anakarder.com](http://www.anakarder.com) web sayfasından ulaşılabilir.

©Copyright 2011 by AVES Yayıncılık Ltd. - Available on-line at [www.anakarder.com](http://www.anakarder.com)  
doi:10.5152/akd.2011.205

## Diagnostic importance of aVR derivation in exercise stress testing for interpreting of multivessel and proximal LAD disease

*Çok damar ve proksimal LAD lezyonlarının tanınması için yapılan egzersiz stres testinde aVR derivasyonunun tanınma önemi*

Exercise stress testing (EST) is the most frequently used diagnostic method for diagnosing stable coronary artery disease (CAD). EST has some deficiencies due to its relatively low specificity and sensitivity. Many studies have been performed to improve the diagnostic accuracy of EST. The other occupation has become definition the localization of ischemia. Herein electrocardiographic parameters especially ST segment elevation in aVR derivation have been evaluated for this subject. The importance of ST elevation in aVR has been demonstrated in the setting of acute coronary syndrome (1, 2) and latest studies investigated value of aVR derivation in EST. In a retrospective screening study reported that exercise-induced ST-segment elevation in lead aVR is a sensitive (92.9%), but not specific (48.6%), electrocardiographic finding of significant left main coronary artery (LMCA) disease (3). Michaelides et al. (4) reported that exercise-induced ST elevation in aVR and concomitant ST depression in V5, may detect left anterior descending artery (LAD) significant stenosis in patients with single vessel disease. In an another larger study, Uthamalingam et al. (5) reported that sensitivity for LMCA or ostial LAD stenosis was 75%, specificity was 81%, overall predictive accuracy was 80% for 1-mm ST elevation in lead aVR.

At this point, we want to share EST findings in terms of ST elevation in lead aVR of our study, which is going to be published at this journal and issue. The title of our study was "Relationship between Heart-type Fatty Acid-Binding protein levels and coronary artery disease in Exercise Stress Testing: an observational study". Our study enrolled 45 patients, while 19 of those having normal coronary anatomy were accepted as the control group; the remaining 26 patients had coronary lesions over 70% in at least in one major coronary artery. Treadmill EST was applied to all patients in accordance with Bruce's protocol. None of them had LMCA disease because LMCA stenosis is a relative contraindication for performing EST. Interpretations of conventional electrocardiographic parameters are summarized in Table 1. ST segment depression  $\geq 1$ mm occurred in 19 patients in the CAD group and in 10 patients in the control group and the characteristic of ST depression was more prominently downsloping in the CAD group (Table 1). Calculated sensitivity, specificity, positive and negative predictive values (according to ST segment depression  $\geq 1$ mm) in our study were 73%, 74%, 79% and 67%, respectively and these results were compatible with meta-analysis results. Our study was not designed to determine the diagnostic accuracy of ST elevation in lead aVR, so we selected the patients after coronary angiography as control and CAD group and then EST was applied. In our study, although we investigated the relation of the biochemical marker utilized in the study with myocardial ischemia parameters during EST, we also tried to evaluate the association between elevation in aVR and significant CAD in a secondary analysis.

Thirteen patients (50%) had ST segment elevation at least 1 mm in the aVR derivation in the CAD group and only one (5.3%) patient had in the normal coronary group. Sensitivity, specificity, positive and negative predictive value of ST elevation of in lead aVR were 50%, 94%, 92%, 58%, respectively. In our study, 8 of 13 patients having multivessel ( $\geq 2$ ) disease and 5 of 7 patients having proximal LAD stenosis had ST elevation in aVR in the CAD group.

As a result, even though there is limited number of patients enrolled in our study, these results call attention that the interpretation of ST