

Kounis syndrome not induced but prevented by the implantation of a drug-eluting stent: a case report

Kadriye Terzioğlu, Dane Ediger, Raziye Tülümen Öztürk, Eda Durmuş, Mehmet Fethi Alışır¹

Department of Allergy and Immunology, Faculty of Medicine, Uludağ University; Bursa-Turkey

¹Department of Cardiology, Anadolu Hospital; Bursa-Turkey

Introduction

Kounis syndrome is an allergy-associated acute coronary syndrome, which develops secondary to mast cell activation in coronary arteries due to hypersensitivity or anaphylactoid reaction (1). The triggering factors may be various drugs, food, environmental exposure, and intracoronary stents (2–4).

In this case report, an extraordinary case of Kounis syndrome (acute myocardial infarction with concomitant allergic reaction to paracetamol/propyphenazone) has been presented.

Case Report

The patient was a 65-year-old male with a history of coronary artery bypass graft surgery, hypertension, and diabetes mellitus.

A year ago, the patient had taken a paracetamol/propyphenazone tablet, and in the following 10 min, he experienced dyspnea, itching, swelling of hands, and retrosternal chest pain, leading to a state of syncope. The patient was admitted to our emergency service, and initial vital parameters and physical examination were as follows: blood pressure 90/50 mm Hg and pulse rate 100/min, with an unremarkable cardiac and pulmonary

auscultation. He had mild edema in his hands (prominent in the distal phalanx). A 12-lead ECG was obtained in the first 10 min due to ongoing burning chest pain (Fig. 1).

Non-ST-elevated myocardial infarction was diagnosed based on the clinical findings, ECG, and blood tests [CK: 142 U/L (30–100 U/L), CKMB: 33 U/L (0–24 U/L), and troponin I: 0.84 ng/mL (0–0.3 ng/mL)], and the patient was transferred to the intensive care unit. Coronary angiography showed (Fig. 2a, b) that 90% stenosis was present in the middle portion of the left circumflex artery. Percutaneous coronary intervention was performed, and at the same time, a paclitaxel-eluting coronary stent was implanted (Fig. 2a, b).

In the following 10 months, the patient was asymptomatic on regular follow-ups. Two months ago, he took the paracetamol/propyphenazone combination again for common cold, and in 10 min following the intake, he developed urticaria, angioedema, and dyspnea. The patient was again admitted to our emergency service, and this time, no cardiac involvement was observed. He had no chest pain and showed no ST-segment-T wave changes on ECG and no elevation in the cardiac biomarkers CK (55 U/L), CKMB (20 U/L), and troponin (0.15 ng/mL); therefore, he was treated only for his allergic symptoms.

The patient was referred to our tertiary centre with an initial diagnosis of drug allergy. Skin tests and oral drug provocation tests were performed to include IgE-mediated anaphylaxis caused by a single drug (5). The results of prick and intradermal tests were negative. Oral provocation tests with aspirin were performed to exclude COX-1-mediated cross hypersensitivity and with meloxicam to determine tolerance/intolerance to alternative nonsteroidal anti-inflammatory drugs; both the tests were showed negative results. The patient was advised not to use any drug containing paracetamol and/or propyphenazone.

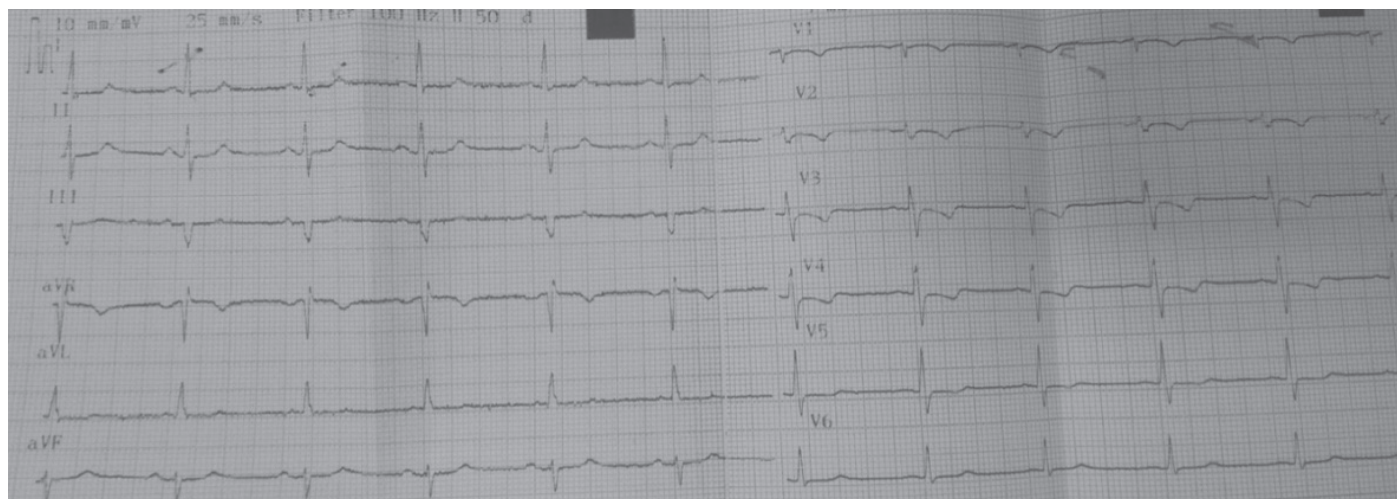


Figure 1. ECG image obtained after the first drug reaction. A 1-mm ST-segment depression in DI, DII, aVL, and aVF and T-wave negativity in V1–V4 were observed

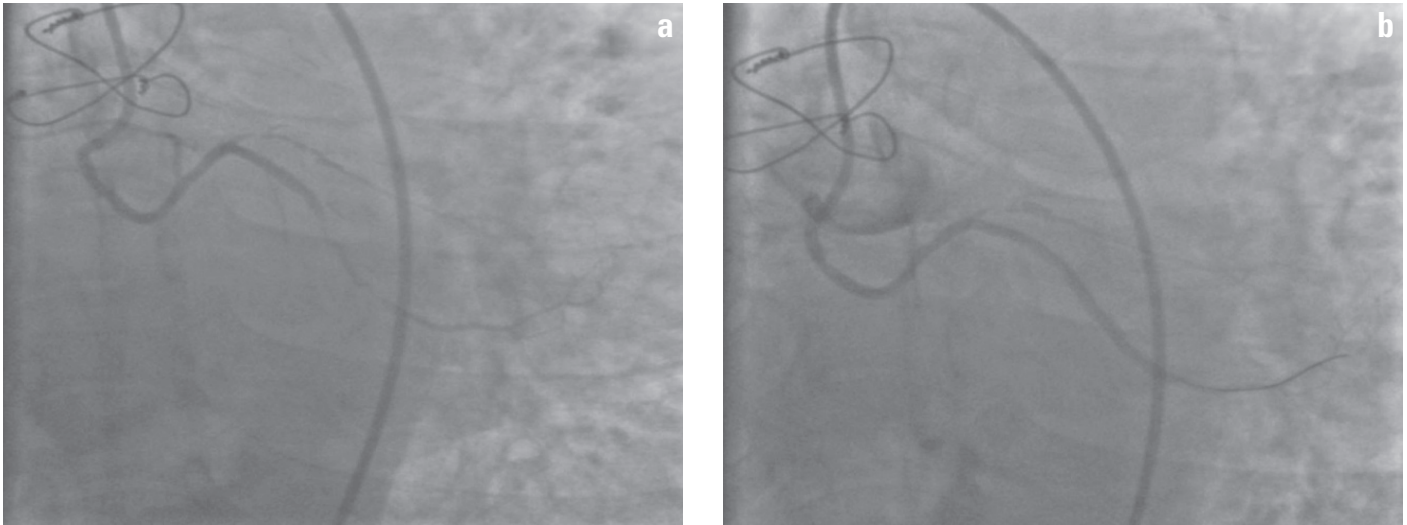


Figure 2. (a) Circumflex (CX) coronary artery. Overall, 90% stenosis in the middle portion was observed. (b) CX coronary artery completely opened after stent implantation

Discussion

Our case was diagnosed with the type 2 variant of Kounis syndrome because the patient already had an underlying coronary artery disease and first exposure to the responsible drug induced allergic reaction that resulted in myocardial infarction. However, following the intake of the same drug for the second time, the patient developed anaphylaxis without cardiac involvement. It is likely that coronary artery disease was treated effectively and active, vulnerable plaques were stabilized; therefore, Kounis syndrome did not occur during the second drug reaction with the anaphylaxis following a mild course. Likewise, Çakar et al. (6) reported a case of diclofenac-induced allergy that presented with urticaria, hypotension, and myocardial infarction. A significant coronary artery stenosis was detected and treated with stent implantation. Two months later, the patient received diclofenac injection and had a transient ST-segment elevation. Nevertheless, no myocardial ischemia was detected in his myocardial perfusion scintigraphy (6). This patient also initially experienced a severe course of anaphylaxis (in case of untreated coronary artery disease) and then a milder course during the second reaction following the treatment for coronary artery disease.

Mueller reported that 10 of 12 patients who died of bee-sting anaphylaxis had coronary artery disease. This report supports the assumption that an underlying coronary artery disease may have a negative impact on the course of anaphylaxis (7).

Conclusion

Not only cardiologists but also allergists should follow-up with the patients diagnosed with allergic and coronary heart dis-

eases, especially those allergic to drugs or bee venom, i.e., those at an increased risk of developing anaphylaxis.

References

1. Kounis NG. Kounis syndrome: an update on epidemiology, pathogenesis, diagnosis and therapeutic management. *Clin Chem Lab Med* 2016; 54: 1545-59. [CrossRef]
2. Keskin M, Hayiroğlu Mİ, Onuk T, Keskin Ü, Ekmekçi A. Kounis syndrome presenting with acute inferior wall myocardial infarction and cardiogenic shock secondary to intravenous ampicillin/sulbactam administration. *Anatol J Cardiol* 2016; 16: 893-94. [CrossRef]
3. İnci S, Aksan G, Doğan A. Bonsai-induced Kounis Syndrome in a young male patient. *Anatol J Cardiol* 2015; 15: 952-4. [CrossRef]
4. Kounis NG. Coronary hypersensitivity disorder: the Kounis syndrome. *Clin Ther* 2013; 35: 563-71. [CrossRef]
5. Kowalski ML, Asero R, Bavbek S, Blanca M, Blanca-Lopez N, Bochenek G, et al. Classification and practical approach to the diagnosis and management of hypersensitivity to nonsteroidal anti-inflammatory drugs. *Allergy* 2013; 68: 1219-32. [CrossRef]
6. Çakar MA, Gündüz H, Kocayığıt I, Binak DF, Vatan MB, Tamer A. Acute coronary syndrome due to diclofenac potassium induced anaphylaxis: two Kounis syndrome variants in the same patient. *Anadolu Kardiyol Derg* 2011; 11: 88-9.
7. Mueller UR. Cardiovascular diseases and anaphylaxis. *Curr Opin Allergy Clin Immunol* 2007; 7: 337-41. [CrossRef]

Address for Correspondence: Dr. Kadriye Terzioğlu
Uludağ Üniversitesi Tıp Fakültesi Göğüs Hastalıkları
Allerji ve İmmunoloji Bilim Dalı, Bursa-Türkiye
E-mail: dr.kadriyete@gmail.com

©Copyright 2017 by Turkish Society of Cardiology - Available online at www.anatoljcardiol.com

DOI:10.14744/AnatolJCardiol.2017.7690

