

A comprehensive review of the diagnosis and management of mitral paravalvular leakage

 *Mustafa Ozan Gürsoy*,  *Ahmet Güner*¹,  *Macit Kalçık*²,  *Emrah Bayam*³,  *Mehmet Özkan*³

Department of Cardiology, İzmir Katip Çelebi University, Atatürk Training and Research Hospital; İzmir-Turkey

¹Department of Cardiology, University of Health Sciences, Mehmet Akif Ersoy Thoracic and Cardiovascular Surgery Training and Research Hospital; İstanbul-Turkey

²Department of Cardiology, Faculty of Medicine, Hitit University; Çorum-Turkey

³Department of Cardiology, Koşuyolu Kartal Heart Training and Research Hospital; İstanbul-Turkey

ABSTRACT

Mitral paravalvular leaks (PVLs) commonly occur in patients with prosthetic valves. Paravalvular defects may be clinically inconsequential and may aggravate hemolysis or cause heart failure through regurgitation. Accordingly, patients may eventually require intervention such as redo surgery or a transcatheter closure of the defects. The introduction of purpose-specific closure devices and new steerable catheters has opened a new frontier for the transcatheter PVL closure. This mode of treatment is an initial therapy in most centers with experienced structural heart team. However, head-to-head data comparing two treatment modalities (surgery and transcatheter closure) are limited, and the world-wide experience is based on nonrandomized studies. Multimodality imaging, including three-dimensional transesophageal echocardiography, facilitates the delineation of mitral PVLs and provides essential data that aids the communication between the members of the structural heart team. In the near future, the success of interventional therapies will most probably increase in patients with mitral PVLs with the introduction of hybrid imaging modalities (echocardiography, cardiac computed tomography, and fluoroscopy). In conclusion, this paper summarizes the etiopathogenesis, clinical characteristics, diagnosis, and treatment of mitral PVLs. (*Anatol J Cardiol* 2020; 24: 350-60)

Keywords: mitral valve, echocardiography, transcatheter closure, cardiac surgery

Introduction

Despite the recent advances in valve replacement techniques, paravalvular leaks (PVLs) continue to be a life-threatening complication in patients with prosthetic heart valves (1). The incidence of mitral PVL after valve surgery is reported to be 2.2% and may increase to 17% (mechanical valve) and 9% (bioprosthetic valve) in a >10-year follow-up (2). PVLs are twice as likely to occur with mitral than with aortic prosthesis (3, 4), and the risk of PVL increases with mechanical heart valves than with bioprosthetic valves (5). Furthermore, compared with index procedures, redo surgeries are associated with a high rate of PVL recurrence and a higher mortality rate. Although most PVLs after surgical valve replacement are trivial to mild and have a benign course in the first year, moderate-to-severe PVLs may aggravate hemolysis or cause heart failure through regurgitation.

Therefore, patients may eventually require surgical closure (SC) or transcatheter closure (TC) of the defects.

In conclusion, this study summarizes the etiopathogenesis, clinical characteristics, diagnosis including multimodality imaging, and treatment of mitral PVLs.

Pathogenesis of surgical paravalvular leaks

PVLs occur due to a separation of the prosthetic valve or ring from the adjacent tissue of the valve annulus. PVLs may develop during the early period after a heart valve surgery and up to several years after a surgery (6). Moreover, the risk factors for PVL development include annular calcification, tissue friability, prior endocarditis, active corticosteroid therapy, type of prosthesis (mechanical implants pose a greater risk than bioprosthetic implants), and surgical technique (continuous sutures pose a greater risk than interrupted sutures for mitral prostheses) (1, 7).

Address for correspondence: Dr. Ahmet Güner, Sağlık Bilimleri Üniversitesi, Mehmet Akif Ersoy Göğüs ve Kardiyovasküler Cerrahi Eğitim ve Araştırma Hastanesi, Kardiyoloji Kliniği, Turgut Özal Bulvarı No: 11, Küçükçekmece, 34303, İstanbul-Türkiye
Phone: +90 212 692 20 00 E-mail: ahmetguner488@gmail.com

Accepted Date: 03.09.2020 **Available Online Date:** 15.10.2020

©Copyright 2020 by Turkish Society of Cardiology - Available online at www.anatoljcardiol.com
DOI:10.14744/AnatolJCardiol.2020.10018



The risk of PVL is not the same in all parts of the prosthetic ring. Several studies have revealed that mitral PVLs more frequently occur at the anterolateral and posteromedial segments of the mitral valve annulus (8, 9). Multiple theories have highlighted the predisposing factors for PVL development in these areas. A study has indicated that collagen fibers in the mitral valve annulus are not homogeneously distributed (10). The mitral annulus does not exhibit a uniformly well-formed chord-like fibrous structure, especially along the posterior segment. This feature may render the posterior annulus vulnerable to mechanical injuries, thereby resulting in PVL (11). Furthermore, the posterior annulus is longer than the anterior region; sutures may separate easily, and annular dilation particularly affects this region (12, 13). Komoda et al. (14) described the altered dynamics of the mitral valve annulus following mitral valve replacement. They stated that following valve replacement, the annulus becomes rigid and exhibits an anti-physiological tilting of the anterior portion of the mitral valve annulus toward the left ventricular base during the systolic phase. The posterior portion exhibits a normal angle of movement. The changes in these aforementioned dynamics may increase the mechanical stress on both posteromedial and anterolateral segments, thereby leading to PVL in these areas.

Clinical presentation and laboratory findings

The majority of PVLs are clinically insignificant and have a benign course in the absence of endocarditis. Early mild PVL may spontaneously resolve during wound healing process, whereas new PVLs may develop as a late complication of valve operation (15). Large PVLs may be hemodynamically significant, resulting in heart failure and posing an increased risk of infectious endocarditis. Furthermore, large PVLs may result in clinically significant hemolytic anemia characterized by jaundice and/or choloria necessitating repeated blood transfusions. Moreover, PVL is the most common cause of hemolytic anemia in patients with prosthetic heart valves, especially in mitral prostheses related to the high velocity of the regurgitant jet that occurs due to the larger pressure gradient of the systolic phase. Turbulent flow through the PVL increases red blood cell shear stress, thereby resulting in mechanical trauma and the fragmentation of red blood cells. Notably, the severity of hemolysis does not always correlate with the size of PVL. A small defect with a high-velocity jet may also cause clinically significant hemolysis, especially in eccentric jets that hit the limbus (Marshall ligament) (9, 15).

Upon physical examination, a holosystolic murmur, usually at the left sternal border or in the midaxillary line, may be heard with the mechanical heart sound (6). The location, pitch, and intensity of the murmur may vary with the position and extension of the mitral regurgitant jet. Large mitral PVLs are usually associated with a murmur, but an eccentric PVL jet may be inaudible.

Laboratory analysis is an essential part of cardiac assessment in patients with suspected mitral PVL. First, hemoglobin and hematocrit should be evaluated. Significant hemolysis may still be present despite a normal hemoglobin level if the bone marrow

is capable of compensating for the peripheral red blood cell destruction. Accordingly, the calculation of a reticulocyte production index may lead to correct diagnosis. Furthermore, serum lactate dehydrogenase, haptoglobin, iron and folic acid levels, and peripheral blood smear examination for schistocytes (fragmented red blood cells) should be evaluated (1, 16). Overall, symptomatic hemolysis is defined as hemolytic anemia (hemoglobin ≤ 10 g/dL, lactate dehydrogenase ≥ 600 mg/dL, and haptoglobin ≤ 10 mg/dL) requiring >2 U of blood transfusions and/or erythropoietin injections within 90 days to maintain hemoglobin ≥ 10 g/dL without any other source of blood loss (17). The possibility of endocarditis should also be considered when new PVL is detected, and blood cultures should be obtained as appropriate. White blood cell count and C-reactive protein should also be evaluated. Moreover, B-type natriuretic peptide or N-terminal pro-BNP might be helpful in assessing and monitoring patients with heart failure.

Evaluation of paravalvular leaks using multimodality imaging

An eccentric turbulent jet with its origin beyond the edge of the sewing ring was considered to indicate PVL, whereas a laminar low-velocity regurgitant jet with its origin within the orifice of the prosthetic ring was considered to be transvalvular (5, 9). Multimodality imaging is crucial for evaluating prosthetic valves and related complications. The major diagnostic tools are transthoracic echocardiography (TTE), two-dimensional (2D) and three-dimensional (3D) TEE, intracardiac echocardiography (ICE), computed tomography (CT), magnetic resonance (MR), and cinefluoroscopy (CF).

Echocardiography

Echocardiography is central to any integrated imaging approach for evaluating mitral PVLs. TTE is the initial imaging modality. Increased transmitral flow compared with left ventricular outflow tract flow in the setting of a normal pressure halftime may indicate a mitral prosthetic valve dysfunction secondary to regurgitation. Atrial and ventricular size and function, pulmonary artery systolic pressure, and concomitant native valvular disease should also be evaluated (18). Furthermore, any mobile masses/vegetation on either the prosthetic or native valves should be considered as PVL may be associated with endocarditis.

Imaging with TTE is often limited by the acoustic shadowing of prosthetic valves. Acoustic shadowing may also result in the absence of color Doppler signal, with a potential underestimation of the degree of PVL. Therefore, delineating valvular vs. paravalvular regurgitation becomes difficult. This is especially true for the assessment of mitral valve prostheses wherein PVL may only be detected in off-axis imaging (e.g., subcostal views) or not seen at all (19). In most cases of PVL, additional imaging with TEE is required to confirm the presence and severity of PVL and distinguish it from transvalvular regurgitation. With TEE, the left atrium becomes the near-field chamber and mitral regurgitation can be more easily depicted (20). Color-flow imaging helps in the localization of the PVLs as well as assessment of the sever-

ity. The entire mitral prosthetic ring should be carefully examined by sweeping the prosthesis from 0° to 180° during TEE study as the PVL defect might occur at any location around the ring. The PVL jet is usually eccentric, and the quantification of the severity may become difficult. Therefore, the echocardiographic measures used to grade PVL are semi-quantitative and have limited validation (21). Table 1 summarizes the echocardiographic assessment of mitral PVL.

Although 2D TEE may differentiate several potential pathologies responsible for PVL, including the separation of sutures, fistulas, perivalvular abscess, and dehiscence, PVL origin and the length of the defect cannot be shown anatomically (13). Multiple jets may also appear as a single broad jet on 2D TEE. Moreover, 2D imaging cannot distinguish whether it is a crescentic or oval defect (22). In the last 15 years, real-time three-dimensional (RT-3D) TTE has played an incremental role in evaluating prosthetic valves, especially mitral prosthesis. RT-3D TEE permits the visualization and understanding of the anatomy of the PVL, including the defect size and shape, entry and exit points, tunnel length, relation with the prosthetic ring, presence of retained sutures, and number of PVLs (23). 3D TEE has a superior diagnostic accuracy in the assessment of the leak compared with 2D TEE, particularly for complex and multiple defects. Further, dropout artifacts may

lead to inappropriate diagnoses of PVL when no such defect exists. Therefore, integrating 2D and 3D imaging is essential for an accurate PVL diagnosis and should be considered as complementary imaging tools.

PVL is defined as “small” if the defect is lower than 10% of the circumference of the annular ring, “moderate” if the defect is between 10% and 20%, and “large” if the defect exceeds 20%. Moreover, the rocking motion of the prosthesis with the large paravalvular defect exceeding 25% of the circumference of the annular ring indicates dehiscence (9). Multiple types of PVLs include crescentic, oval/round, slit-like, and slope tunnel shaped with variable sizes (Fig. 1).

Crescentic: The curved defect around the annular ring is defined as “crescentic.” It may be divided by tight sutures and defined as “multi-fenestrated” crescentic PVL.

Slit-like: In this type of defect, the length of the PVL is much larger than the width of the defect.

Oval/round: The length of the defect is close to the width of the defect in oval/round defects.

Slope tunnel shaped: It is an oblong-shaped defect with a wide atrial orifice.

The contour of PVLs can be regular or irregular. The regurgitant jets may be “central” or “eccentric” (laterally or medially).

Table 1. Echocardiographic parameters to assess the degree of paravalvular leak for mitral valve prostheses

Parameters	Mild	Moderate	Severe
LV size	Normal	Normal to moderately dilated	Moderately or severely dilated
Prosthetic valve	Normal	Abnormal	Abnormal
RV size and function	Normal	Normal to moderately dilated	Moderately or severely dilated
Color flow jet area	Small, central jet (usually <4 cm ² or <20% of LA area)	Variable	Large, central jet (usually >8 cm ² or >40% of LA area)
Proximal flow convergence	None or minimal	Intermediate	Large
Jet density	Incomplete or faint	Dense	Dense
Jet contour	Parabolic	Variable	Early peaking, triangular, holosystolic
Pulmonary venous flow	Normal	Systolic blunting	Systolic flow reversal
Mean gradient	Normal	Increased	≥5 mm Hg
Diastolic PHT	Normal (<130 ms)	Normal (<130 ms)	Normal (<130 ms)
PASP	Normal	Variable, usually increased	Increased (TR velocity ≥3 m/s, PASP ≥50 mm Hg at rest or with exercise)
Vena contracta width (mm)	<3	3–6.9	≥7
Circumferential extent of PVL, %	<10	10–29	≥30
MVPR: LVOT flow	Approximately 1	Intermediate	≥2.5
RVol, mL/beat	<30	30–59	≥60
RF, %	<30	30–49	≥50
EROA, mm ²	<20	20–39	≥40

PVL - paravalvular leak

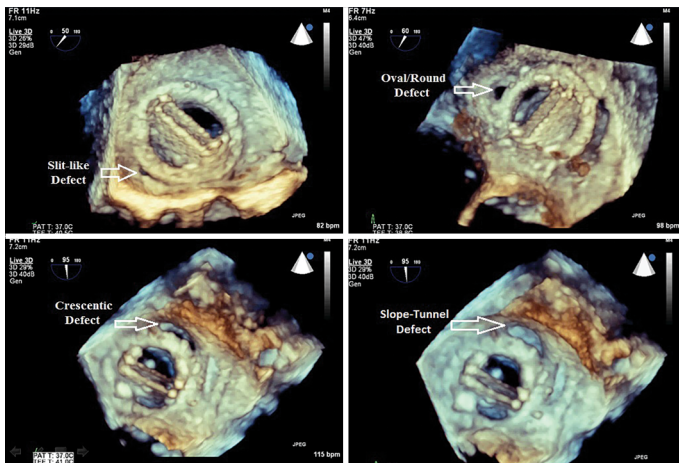


Figure 1. Multiple types of PVLs demonstrated by real-time three-dimensional transesophageal echocardiography

A standardized orientation and nomenclature has been used to define PVLs for the communication between the echocardiographer and the interventionalist. The location of PVLs is best defined in relation to internal landmarks such as the left atrial appendage and aortic valve. On the 3D imaging of mitral valve prostheses, the aortic valve is located anteriorly at the 12 o'clock position, the interatrial septum medially at the 3 o'clock position, and the left atrial appendage laterally at the 9 o'clock position. This type of description is also known as the “surgeon’s view.” Figure 2 depicts the special landmarks on the mitral prosthesis from a “surgeon’s view.”

Multiple studies have investigated the distribution of PVLs in the mitral prosthetic ring. Our group indicated that severe

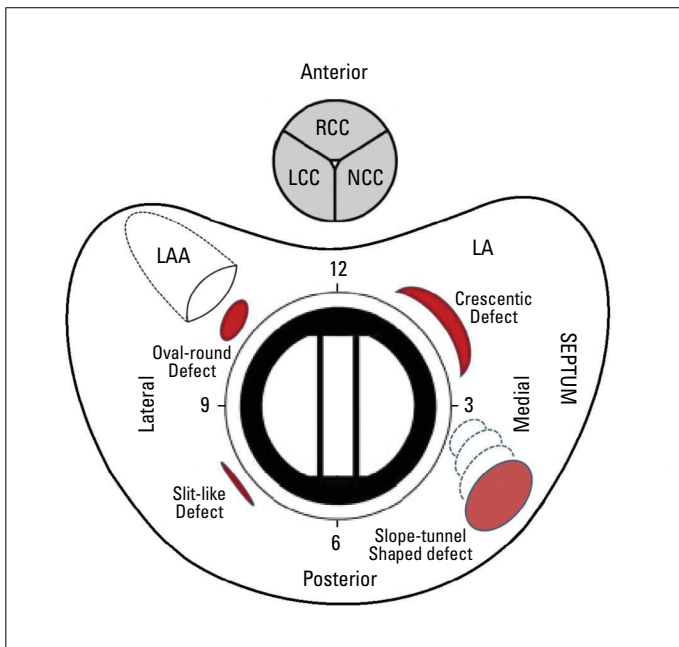


Figure 2. Schematic figure indicates the mitral prosthesis and the relation between the cardiac structures from the atrial side on clockwise format in surgical view

PVLs are mainly located at the antero-lateral and postero-medial commissures and postero-lateral region. Furthermore, the most common observed defect types are “oval/round” and crescentic (9). These findings are consistent with the previous data (8, 17); mitral PVLs are more frequently located at the antero-lateral and postero-medial segments of the mitral valve annulus. As described in the “Pathogenesis of surgical PVLs” section, these heterogeneities concerning the localization of PVL may be attributed to the altered dynamics of the mitral valve annulus and related artificial valve ring as described by Komoda et al. (14).

3D imaging is crucial in the periprocedural assessment of PVLs. For patients undergoing valve surgery, the intraoperative localization of the PVL may be difficult due to low hemodynamics and poor exposure, especially in small defects (24). RT-3D TEE provides the “en face” view of the mitral prosthesis and directly contributes to the successful SC of PVLs (25). During TC, RT-3D TEE provides essential guidance for all procedural steps: the determination of the transeptal puncture site, navigation of the passage of wires and catheters across the PVL, appreciation of the correct number and the irregular shape of PVLs, and adequate device selection and positioning (26).

RT-3D TEE has several limitations: artifacts of ultrasound imaging such as acoustic shadowing and reverberation artifacts as well as reduced temporal and spatial resolution (27).

Furthermore, it is a time-consuming process. Unobstructed visualization is not always possible, necessitating cropping features to remove obstructive anatomy to an en face view.

A major concern is tissue dropout due to undergained image. Dropout may mimic an anatomic defect, leading to the speculation of nonexistent pathology (28); therefore, confirmation with color mapping should be performed to avoid misdiagnosis.

Other imaging modalities used in patients with paravalvular leaks

CF, an essential modality in the catheterization laboratory during closure, is rarely needed in the preprocedural evaluation of PVL. It provides limited data regarding the diagnosis of PVL location and severity, unless a significant rocking motion (dehiscence) of the prosthetic ring is observed. During intervention, fluoroscopic views can provide complementary data to echocardiographic views; the two modalities are mirrored and upside-down views of each other. Anterolateral PVLs are best approached with fluoroscopy in the posteroanterior view with cranial angulation, posteroseptal PVLs in the right anterior view, and lateral PVLs in the lateral view (29).

Nuclear studies, such as labeled leukocyte scintigraphy and positron emission tomography with 18F-fluorodeoxyglucose, may play an additive role in the diagnosis of endocarditis after 3 months of prosthetic valve implantation as it may be the cause of PVL (30). This may be crucial in daily clinical practice as the presence of endocarditis may significantly alter the management of PVLs (31).

CT, which provides images with improved spatial resolution, is useful for the differential diagnosis of prosthetic valve obstruction (pannus/thrombus) (32) and assessment of endocarditis-related complications (valve dehiscence and pseudoaneurysm). Although CT has been reported to have no clear advantage over echocardiography in the detection of vegetations or PVL, it can be invaluable in the anatomical characterization of PVL in patients with significantly limited echocardiographic images and can help define optimal fluoroscopic angles of the prosthetic annular plane to be used for the TC of PVLs (33). However, CT requires ionizing radiation and intravenous contrast. Furthermore, it cannot demonstrate blood flow, and cardiac gating becomes difficult in patients with rapid or irregular heart rates (1).

Cardiac magnetic resonance (CMR) may be particularly useful for assessing the severity of PVL in cases where echocardiography remains inconclusive and/or when discordance is found between the echocardiographic findings and the patient's symptoms. CMR measures regurgitant volumes for multiple valve types, irrespective of the regurgitant jet number or morphology; TTE and TEE have failed to adequately do so due to acoustic shadowing (34). In daily clinical practice, CMR compatibility is frequently consulted to cardiologists; all prosthetic valves (including mechanical valves in the last three decades) can be imaged by CMR. However, CMR may provide limited data in the setting of arrhythmia and may overestimate the degree of PVL compared with echocardiography due to the incorporation of coronary flow (35).

The Echo Navigator; EchoNavigator® facilitates TC of PVLs. It enables real-time image synchronization and fusion of 2D or 3D-TEE images with fluoroscopic images. In addition, it depicts the position of the PVL on the fluoroscopic view and facilitates the precise steering of the guidewire through the PVL (36).

Intracardiac echocardiography can guide the TC of PVLs. It is feasible, safe, and associated with acceptable procedural success rates. It has several advantages over TEE during interventions: it eliminates the need for general anesthesia; provides clearer imaging; and reduces procedure time, hospital stays, and radiation doses. However, the procedural success with this approach is limited in lateral mitral PVLs (37).

Treatment

The treatment includes medical and interventional therapy. Medical therapy may be considered in symptomatic patients with mild-to-moderate PVL. It includes diuretic therapy and afterload reduction to treat heart failure. Hemolysis may be managed with a combination of iron, folate, and vitamin B12 supplements as well as packed-red blood cell transfusions in severe cases (1). However, these therapies may be unsuccessful to relieve the symptoms completely, and patients may suffer from progressive heart failure and/or continued hemolysis, necessitating further management.

The two main types of interventions include SC and the TC of PVLs. Each strategy has its own pros and cons. Figure 3 depicts the algorithm for the diagnosis and treatment of PVLs.

Repeat heart valve surgery has been performed for years due to expected high rates of complete success, but it may also lead to suboptimal long-term outcomes as technical or anatomic factors that could have led to the development of these PVLs often persist. Therefore, in the last two decades, TC has emerged as a relatively less invasive therapy.

According to the 2017 American College of Cardiology/American Heart Association Focused Guidelines Update for the management of valvular heart disease, SC is a Class IB recommendation for operable patients with mechanical heart valves with intractable hemolysis or heart failure due to PVL. Furthermore, the TC of PVLs is a Class IIa recommendation in patients with prosthetic heart valves and intractable hemolysis or New York Heart Association (NYHA) Class III/IV heart failure who are at high surgical risk and have suitable anatomic features for TC in an experienced center (38). In the 2017 ESC guidelines for the management of valvular heart disease, SC and TC have been considered as a Class IC and IIb recommendation, respectively (39). The two interventional strategies are described in greater detail below.

Surgery

Before the introduction of the TC of PVLs, SC has been used for decades as the main mode of treatment. In most reoperation cases, the exposure of the mitral valve is difficult due to severe adhesions. It is also challenging to evaluate a mitral PVL in a nonphysiologic state. When the left ventricle is decompressed, the surrounding anatomy becomes distorted, making PVLs difficult to detect or localize (40). Therefore, perioperative real-time 3D TEE imaging would be a great guide for surgeons to identify the location of PVL (24). Surgical options include PVL repair or prosthesis replacement. The type of surgery depends on the size and extent of the PVL, the condition of the native valve ring, and the patient's surgical history.

Repair of PVL includes several techniques such as direct suturing in case of small and well-seated PVLs, use of patches, and incorporation of healthy full-thickness autologous tissue (41, 42). They can be technically demanding due to the presence of friable tissue, fibrosis, and calcification from a previous infection. This may be associated with uncorrected annulus and unstable sutures left, leading to clinically significant residual PVL after surgery (23).

The Canadian and Swiss experiences have revealed that patch or pledgeted suture repair is utilized in 75% and 65% of the patients, respectively (41, 43). Furthermore, valve re-replacement is performed in 50%, 51%, and 90% of the patients in three largest US states (44-46).

Although the current literature does not allow outcome comparison by the type of surgical technique, the decision to repair PVLs or replace the prosthesis depends on the experience of the operators and the surgical volume as well as the anatomical characteristics of PVL (47).

Transcatheter closure

TC was initially performed in inoperable patients as an alternative to medical treatment, but in the last decade, it has been

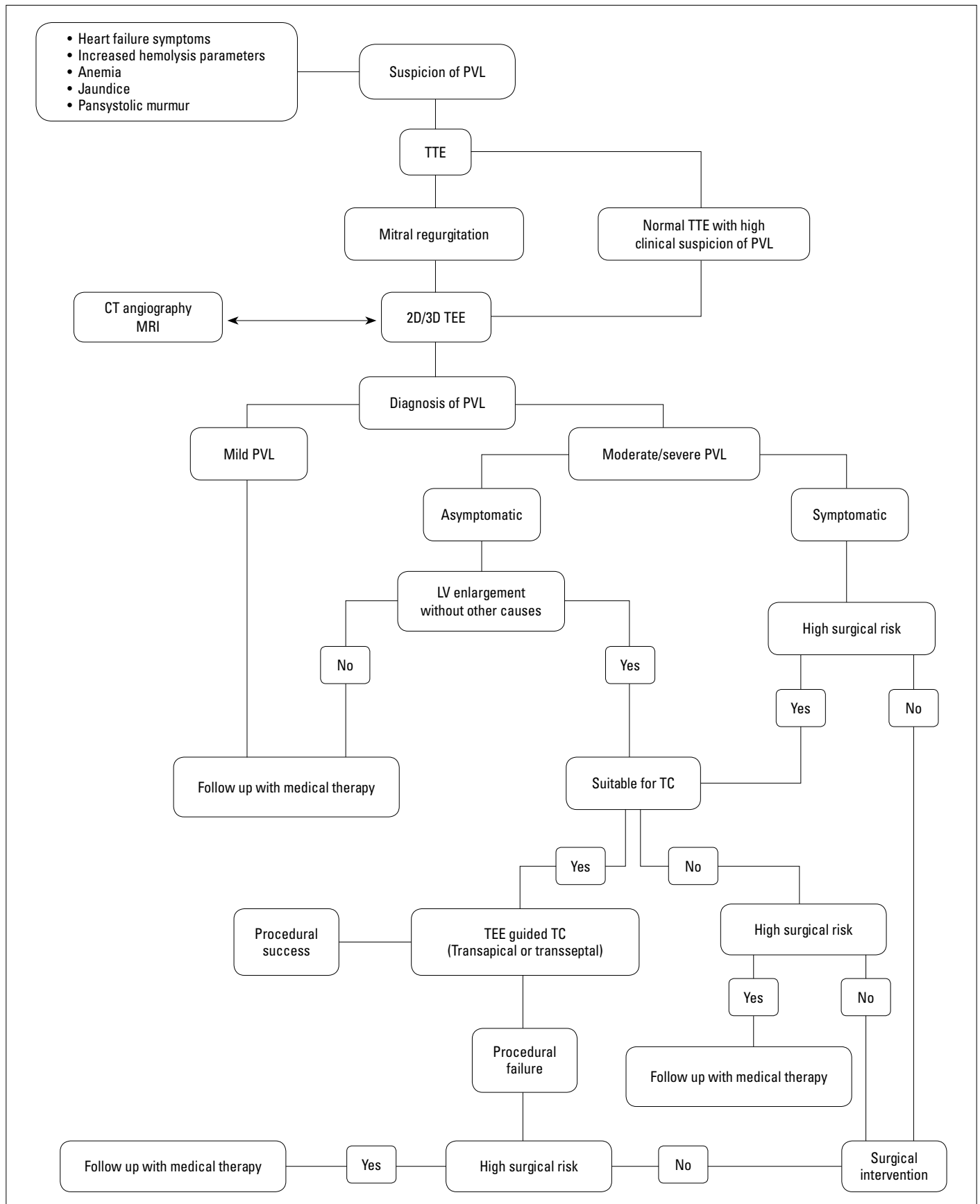


Figure 3. The algorithm for diagnosis and treatment of PVLs is shown

adopted as a first-line therapy in many experienced centers (23). Although most cases of PVL are treatable with TC, the contraindications to TC should be carefully assessed. An ongoing process of endocarditis should be excluded. If a PVL is getting rapidly larger in a short period of time, it may be associated with an ongoing process of suture/tissue rupture, and performing TC may be impractical (48). Unstable prosthesis (dehiscence) and large defects comprising >1/3 of the annular circumference necessitate surgical intervention (15). The anatomical characteristics of PVL mostly determine the mode of initial therapy and the likelihood of success if TC is preferred. The success rates are highest in the small, slit-like, crescentic, and single defects, whereas larger, irregular, and slope tunnel shaped and multiple defects are associated with poorer results (48). Furthermore, crescentic or large oblong defects usually require multiple devices. Table 2 presents the favorable and unfavorable characteristics of the TC of PVLs.

TC has multiple techniques, including antegrade (transseptal), retrograde aortic, and apical approaches (1, 49).

The interventional cardiologists should be experienced in this complex catheter-based procedure, such as the transseptal or apical puncture, snaring, and creation of arteriovenous loops (1). Antegrade transseptal puncture is generally the first method of choice for mitral PVL closure. The optimal location for transseptal approach puncture depends on the localization of PVL. Like other mitral valve interventions, TEE plays a critical role in guiding transseptal puncture. Lateral defects are amenable to high puncture on the interatrial septum. Since posteriorly and medially localized PVLs are difficult to engage, the puncture should be lower and more posterior to allow more direct access to the PVL origin (50). A retrograde transapical approach provides the shortest route and may be reasonable in patients with posterior or septal PVL or multiple PVL at different locations (6). Many interventional cardiologists prefer to create an arteriovenous wire loop in the antegrade transseptal and retrograde transfemoral approaches. Each of these procedures is associated with increased procedural time and cost and high risk of complications. Previous case reports have demonstrated that

an arteriovenous wire loop is not necessary in all cases (51-53). Moreover, retrograde transfemoral closure of mitral PVL is possible without creating a wire loop, which was first described a decade ago by Kursaklioglu et al. (51).

The other steps of TC may also become challenging, resulting in a prolonged procedural time. In some cases, the defect can be crossed with a guidewire, but crossing with an available delivery sheath or catheter may be impossible. The defect may be crossed and closed; however, the closure device may interfere with the function of the prosthetic valve, prohibiting the release of the device (17). The TC of mitral prosthesis may also become more challenging in the case of concomitant aortic prosthesis. An antegrade trans-septal mitral PVL closure without the creation of an arteriovenous wire loop can be successfully performed (53). A transapical, retrograde, or combined retrograde/antegrade approach may also be an option for experienced operators (54). Therefore, periprocedural planning as well as communication between experienced members of the structural heart team is crucial for procedural success.

Irregular leak morphology and complex anatomy of the surrounding tissue may be associated with incomplete PVL sealing. Partial TC of PVLs may reduce regurgitant volume and improve heart failure symptoms, but the degree of hemolysis may not be affected or may even be potentially worsened. Therefore, dedicated devices in multiple sizes and shapes are crucial for complete PVL sealing (55). The ideal device for the TC of PVLs should be retrievable and repositionable and should be larger than the defects to avoid embolization (19). Larger devices and those deployed close to the hinge point may interfere with prosthetic function. Furthermore, it can even fracture the sewing ring from the annulus, exacerbating the PVL. Bleeding, pericardial effusion, hemothorax (in transapical procedure) together with transient hemolysis, transient ischemic events, or stroke may occur during the TC of PVLs (56).

So far, numerous devices have been used in the TC of PVLs, but the outcomes have been usually unsatisfactory due to the potential limitations of the devices and the crescentic nature of most PVLs (1). They are mostly Amplatzer [St. Jude Medical (now Abbott), St. Paul, MN, USA] devices and include the Amplatzer Vascular Plug (AVP) family of occluder devices (AVP II, AVP III, and AVP IV), the Amplatzer Duct Occluder (ADO I and ADO II), the Amplatzer Atrial Septal Occluder (ASO), and the Amplatzer Muscular Ventricular Septal Defect (VSD) Occluder.

A round or long tunnel-shaped PVL can be sealed with a Vascular Plug II, whereas a large crescentic leak can be treated with a large device such as a VSD Occluder (57), which itself also carries a risk of hemolysis. Therefore, a large PVL defect is most effectively closed with the “nesting” of multiple devices (58), which may be more successful than using a large single device (e.g., VSD Occluder).

In the last decade, two devices AVP III (St. Jude Medical, St. Paul, MN, USA) and Occlutech paravalvular leak device (PLD) (Occlutech, Helsingborg, Sweden) have gained popular-

Table 2. Favorable and unfavorable characteristics for the transcatheter closure of paravalvular leaks

Favorable	Unfavorable
>5 mm distance from sewing ring to defect	<2 mm distance from valve sewing ring
Small PVL	Large PVL
Single PVL	Multiple perforated
Straight/short-tunnel	Slope tunnel
	Rocking valve
	Calcified paravalvular tissue
	Infective endocarditis
PVL - paravalvular leak	

ity and are specifically dedicated to PVL closure as their shape is closer to the anatomy of the majority of PVL defects (19). AVP III has an oval shape, smaller pore size, improved surface contact, and faster occlusion compared with other Amplatzer devices. It offers a chance to fully occlude the defect without interfering with the leaflet movement (53). Occlutech PLD is a self-expanding, flexible, double-disc device; the discs have either a rectangular frame with an ellipsoid waist or a square frame with a circular waist (55). Both rectangular and square designs have 35% less surface area compared with a similar sized, circular design, which decreases the possibility of mechanical interference with a valve and minimizes device overlap when multiple Occlutech® PLDs are needed to seal the defect. The rectangular-shaped device can cover a crescentic defect (59). Although Occlutech® PLD has no radial strength due to its waist design, its intrinsic clamping force keeps the prosthetic valve and surrounding tissue in close proximity to each other after the TC of PVLs. The vascular plugs of the Amplatzer family (e.g., Amplatzer Vascular Plug III) have high radial strength due to the large waist design and lack the clamping force; the thicker waist and circular design may exacerbate the regurgitation (59).

The success and complication rates of TC vary between different series, as this is a complex and technically demanding procedure. Furthermore, the type of closure devices varies in different countries. Oblong and purpose-specific devices are not available in the US, whereas they are used for the TC of PVLs in Europe. Although the data regarding the potential benefits of these devices are insufficient, several studies have suggested a potential superiority of these devices (55, 57, 59, 60).

In the Spanish registry (514 procedures in 469 patients from 19 centers; mitral prosthesis 70.2%), technical and procedural success was achieved in 86.6% and 73.2% of the patients, respectively (57). Furthermore, 80.2% of the patients did not experience any complications; the most frequent one was minor bleeding related to the vascular access (8.6%), which did not have a major clinical impact. The 30-day incidence of major complications (death, stroke, or need for emergency surgery) was 5.6%. The reasonable rate of procedural success and a low rate of complications were attributed to the use of specifically designed devices, dedicated techniques for catheter delivery, and improved echocardiographic imaging including RT-3D TEE. This registry indicated a higher success rate for mitral procedures in centers with more experience, highlighting the relation between operator experience and favorable results after TC (57). The registry from the United Kingdom and Ireland (259 patients from 20 different centers) revealed similar findings and indicated a hospital mortality rate of 2.9% for elective procedures (60). They strongly suggested TC as an alternative to repeat surgery. A most recent multicentric study in Europe evaluated the midterm procedural and clinical outcomes of TC with the Occlutech PLD (55). The results revealed that procedural success for mitral PVL closure (n=69) with the

Occlutech PLD was high, with a low rate of residual or recurrent leaks, and was associated with significant improvement in NYHA class and reduction of hemolytic anemia and transfusion dependency.

Comparison of transcatheter closure and surgical correction

Head-to-head data comparing two treatment modalities (SC & TC) are limited (41, 44, 45, 61, 62), and the world-wide experience is based on nonrandomized studies.

The largest study that compared patients with PVL treated with TC (n=195) or SC (n=186) at the Mayo Clinic, USA, between 1995 and 2015 demonstrated a higher technical success in the SC group (95.5% vs. 70.1%; $p<0.001$) (44). The patients in the SC group had higher in-hospital mortality (8.6% vs. 3.1%, $p=0.027$), but no difference between the two therapeutic modalities in terms of mortality or need for reintervention during the follow-up period was observed.

In 2018, Busu et al. (47) reported a meta-analysis regarding the comparison of these two treatment strategies and provided significant data. In this meta-analysis, 22 studies were included: 17 single-arm retrospective studies and 5 retrospective studies that compared SC and TC. Furthermore, 2,373 patients were enrolled: 862 (36.3%) in the SC group and 1,511 (63.7%) in the TC group. The primary indications for TC were symptomatic heart failure (65.9%) followed by hemolytic anemia (21.9%). Mitral position was the most common PVL location (74.4%). The most common device used in the meta-analysis was the Amplatzer Vascular Plug II (71%). The number of patients who underwent prosthetic reimplantation versus patch or pledgeted suture repair was similar in the SC group. SC was associated with higher rates of technical success (96.7% vs. 72.1%) due to the nature of the intervention, but it appeared to bring with it an upfront cost, including a higher 30-day mortality (8.6% vs. 6.8%), stroke (3.3% vs. 1.4%), and hospitalization duration. Moreover, no differences between the two strategies regarding mortality (17.3% vs. 17.2%), reoperation rates (9.1% vs. 9.9%), NYHA class, or heart failure readmissions at the end of a one-year follow-up period were observed.

It is difficult to interpret these results and make clear conclusions due to the heterogeneity of the small-scaled studies regarding PVL characteristics and transcatheter techniques used (purely percutaneous or via a transapical approach) even if multivariate analyses or propensity score matching are used to reduce confounding factors. A trend toward the use of TC as the default treatment option has been observed in large centers with a well-integrated and experienced structural heart team. Unfortunately, a randomized study in the future seems unlikely due to practical and financial limitations.

Ways to prevent PVL development: Future perspectives for better management

As PVL is commonly detected early after valve surgery, several precautions should be taken during the perioperative period.

The routine use of intraoperative TEE may prevent PVL development. Especially, during surgery, eradicating the infected tissue in patients with active infectious endocarditis is crucial to avoid late PVL. Furthermore, extensive mitral annular calcification may interfere with the proper seating of the prosthesis. In such circumstances, the resection of the calcium bar and creation of a new annulus with pericardium may provide better seating of the prosthesis (63).

New technological advancements are especially essential for the success of the TC of PVLs. The development of new devices specifically dedicated to the TC of PVLs is crucial, particularly in relation to the often irregular and crescentic defects. 3D printing may play an invaluable role in patient-specific PVL device production. Furthermore, steerable catheters with radiopaque markers open a new frontier for TC and will become a valuable tool as interventional cardiologists continue to push the edge of endovascular therapy (64). Moreover, the improvements in hybrid imaging (including echocardiography, cardiac CT, and fluoroscopy) may also yield appreciable results in terms of the TC of PVLs. Finally, further data regarding the role of professional experience required to optimize clinical outcomes should be available for interventionalists to perform the TC of mitral PVLs, one of the most demanding interventional procedures used for structural heart valve disease.

Conclusion

PVLs are life-threatening complications of prosthetic valve surgery. PVLs in mitral position may be clinically inconsequential, but severe forms may also aggravate hemolysis or cause heart failure. The TC of severe mitral PVLs can be offered as an initial therapy in experienced centers as a transcatheter attempt does not preclude subsequent surgery as an alternative treatment, therefore allowing a step-wise approach to a challenging clinical disorder. Furthermore, technical advancements in purpose-specific devices, catheters, surgical techniques, and materials with the guidance of multimodality imaging will progressively increase the success of interventional procedures. An integrated approach to select the optimal treatment for the appropriate patient is crucial. Prospective registries and further randomized studies will probably address the gaps in evidence.

Conflict of interest: None declared.

Peer-review: Externally peer-reviewed.

Authorship contributions: Concept – M.O.G., A.G., M.K.; Design – M.O.G.; Supervision – M.Ö.; Funding – None; Materials – M.O.G., A.G., M.K., M.Ö.; Data collection and/or processing – A.G., M.Ö.; Analysis and/or interpretation – A.G., M.K.; Literature search – M.O.G., E.B.; Writing – M.O.G., A.G., M.K.; Critical review – M.Ö., E.B.

References

1. Ruiz CE, Hahn RT, Berrebi A, Borer JS, Cutlip DE, Fontana G, et al. Clinical trial principles and endpoint definitions for paravalvular leaks in surgical prosthesis: an expert statement. *J Am Coll Cardiol* 2017; 69: 2067–87. [\[CrossRef\]](#)
2. Duncan BF, McCarthy PM, Kruse J, Andrei AC, Li Z, Russell HM, et al. Paravalvular regurgitation after conventional aortic and mitral valve replacement: A benchmark for alternative approaches. *J Thorac Cardiovasc Surg* 2015; 150: 860–8. [\[CrossRef\]](#)
3. Cappelli F, Del Bene MR, Santoro G, Meucci F, Attanà P, Barletta G. The challenge of integrated echocardiographic approach in percutaneous closure of paravalvular leak. *Echocardiography* 2011; 28: E168–71. [\[CrossRef\]](#)
4. Ozan Gürsoy M, Kalçık M, Özkan M, Astarçioğlu MA, Karakoyun S, Gündüz S, et al. Evaluation of Aortic Paravalvular Leak: A Special Reference for Anatomical Localization. *J Heart Valve Dis* 2016; 25: 403–9.
5. Cho IJ, Moon J, Shim CY, Jang Y, Chung N, Chang BC, et al. Different clinical outcome of paravalvular leakage after aortic or mitral valve replacement. *Am J Cardiol* 2011; 107: 280–4. [\[CrossRef\]](#)
6. Kumar R, Jelnin V, Kliger C, Ruiz CE. Percutaneous paravalvular leak closure. *Cardiol Clin* 2013; 31: 431–40. [\[CrossRef\]](#)
7. Vongpatanasin W, Hillis LD, Lange RA. Prosthetic heart valves. *N Engl J Med* 1996; 335: 407–16. [\[CrossRef\]](#)
8. De Cicco G, Russo C, Moreo A, Beghi C, Fucci C, Gerometta P, et al. Mitral valve periprosthetic leakage: Anatomical observations in 135 patients from a multicentre study. *Eur J Cardiothorac Surg* 2006; 30: 887–91. [\[CrossRef\]](#)
9. Gürsoy OM, Astarçioğlu MA, Gökdeniz T, Aykan AC, Bayram Z, Cakal B, et al. Severe mitral paravalvular leakage: echo-morphologic description of 47 patients from real-time three-dimensional transesophageal echocardiography perspective. *Anatol J Cardiol* 2013; 13: 633–40. [\[CrossRef\]](#)
10. Kunzelman KS, Cochran RP, Murphree SS, Ring WS, Verrier ED, Eberhart RC. Differential collagen distribution in the mitral valve and its influence on biomechanical behaviour. *J Heart Valve Dis* 1993; 2: 236–44.
11. Angelini A, Ho SY, Thiene G, et al. Anatomy of the mitral valve. In: Boudoulas H, Wooley CF, editors. *Mitral valve: floppy mitral valve, mitral valve prolapse, mitral valvular regurgitation*. 2nd ed. New York: Futura Publishing Company; 2000;p:5-30.
12. Genoni M, Franzen D, Tavakoli R, Seiffert B, Graves K, Jenni R, et al. Does the morphology of mitral paravalvular leaks influence symptoms and hemolysis? *J Heart Valve Dis* 2001; 10: 426–30.
13. Yıldız M, Duran NE, Gökdeniz T, Kaya H, Ozkan M. The value of real-time three-dimensional transesophageal echocardiography in the assessment of paravalvular leak origin following prosthetic mitral valve replacement. *Turk Kardiyol Dern Ars* 2009; 37: 371–7.
14. Komoda T, Hetzer R, Siniawski H, Oellinger J, Felix R, Uyama C, et al. Effects of prosthetic valve placement on mitral annular dynamics and the left ventricular base. *ASAIO J* 2001; 47: 60–5. [\[CrossRef\]](#)
15. Eleid M. Interventional management of paravalvular leak. *Heart* 2018; 104: 1797–802. [\[CrossRef\]](#)
16. Thomas C, Kirschbaum A, Boehm D, Thomas L. The diagnostic plot: a concept for identifying different states of iron deficiency and monitoring the response to epoetin therapy. *Med Oncol* 2006; 23: 23–36. [\[CrossRef\]](#)
17. Ruiz CE, Jelnin V, Kronzon I, Dudiy Y, Valle-Fernandez RD, Einhorn BN, et al. Clinical outcomes in patients undergoing percutaneous

- closure of periprosthetic paravalvular leaks. *J Am Coll Cardiol* 2011; 58: 2210-7. [CrossRef]
18. Bertrand PB, Levine RA, Isselbacher EM, Vandervoort PM. Fact or artifact in two-dimensional echocardiography: avoiding misdiagnosis and missed diagnosis. *J Am Soc Echocardiogr* 2016; 29: 381-91.
 19. Bernard S, Yuçel E. Paravalvular Leaks-From Diagnosis to Management. *Curr Treat Options Cardiovasc Med* 2019; 21: 67. [CrossRef]
 20. Okutucu S, Mach M, Oto A. Mitral paravalvular leak closure: Transcatheter and surgical solutions. *Cardiovasc Revasc Med* 2020; 21: 422-31. [CrossRef]
 21. Alkhouli M, Zack CJ, Sarraf M, Eleid MF, Cabalka AK, Reeder GS, et al. Successful Percutaneous Mitral Paravalvular Leak Closure Is Associated With Improved Midterm Survival. *Circ Cardiovasc Interv* 2017; 10: e005730. [CrossRef]
 22. Siddiqi N, Seto A, Patel PM. Transcatheter closure of a mechanical perivalvular leak using real-time three-dimensional transesophageal echocardiography guidance. *Catheter Cardiovasc Interv* 2011; 78: 333-5. [CrossRef]
 23. Giblett JP, Rana BS, Shapiro LM, Calvert PA. Percutaneous management of paravalvular leaks. *Nat Rev Cardiol* 2019; 16: 275-85. [CrossRef]
 24. Furukawa K, Kamohara K, Itoh M, Furutachi A, Mukae Y, Morita S. Real-time three-dimensional transesophageal echocardiography is useful for the localization of a small mitral paravalvular leak. *Ann Thorac Surg* 2011; 91: e72-3. [CrossRef]
 25. Ziegler A, Jander N, Guenkel L, Keyl C. Intraoperative localization of paravalvular mitral prosthetic regurgitation by 3-dimensional color-flow transesophageal echocardiography. *J Cardiothorac Vasc Anesth* 2008; 22: 435-7. [CrossRef]
 26. Wunderlich NC, Beigel R, Ho SY, Nietlispach F, Cheng R, Agricola E, et al. Imaging for Mitral Interventions: Methods and Efficacy. *JACC Cardiovasc Imaging* 2018; 11: 872-901. [CrossRef]
 27. Lang RM, Badano LP, Tsang W, Adams DH, Agricola E, Buck T, et al. EAE/ASE recommendations for image acquisition and display using three-dimensional echocardiography. *J Am Soc Echocardiogr* 2012; 25: 3-46. [CrossRef]
 28. Perk G, Lang RM, Garcia-Fernandez MA, Lodato J, Sugeng L, Lopez J, et al. Use of real time three-dimensional transesophageal echocardiography in intracardiac catheter based interventions. *J Am Soc Echocardiogr* 2009; 22: 865-82. [CrossRef]
 29. Lázaro C, Hinojar R, Zamorano JL. Cardiac imaging in prosthetic paravalvular leaks. *Cardiovasc Diagn Ther* 2014; 4: 307-13.
 30. Habib G, Lancellotti P, Antunes MJ, Bongiorni MG, Casalta JP, Del Zotti F, et al.; ESC Scientific Document Group. 2015 ESC Guidelines for the management of infective endocarditis: The Task Force for the Management of Infective Endocarditis of the European Society of Cardiology (ESC). Endorsed by: European Association for Cardio-Thoracic Surgery (EACTS), the European Association of Nuclear Medicine (EANM). *Eur Heart J* 2015; 36: 3075-128. [CrossRef]
 31. Pizzi MN, Roque A, Fernandez-Hidalgo N, Cuéllar-Calabria H, Ferreira-González I, González-Alujas MT, et al. Improving the diagnosis of infective endocarditis in prosthetic valves and intracardiac devices with 18F-fluorodeoxyglucose positron emission tomography/computed tomography angiography: initial results at an infective endocarditis referral center. *Circulation* 2015; 132: 1113-26.
 32. Gündüz S, Özkan M, Kalçık M, Gürsoy OM, Astarcioglu MA, Karakoyun S, et al. Sixty-Four-Section Cardiac Computed Tomography in Mechanical Prosthetic Heart Valve Dysfunction: Thrombus or Pannus. *Circ Cardiovasc Imaging* 2015; 8: e003246. [CrossRef]
 33. Suh YJ, Hong GR, Han K, Im DJ, Chang S, Hong YJ, et al. Assessment of mitral paravalvular leakage after mitral valve replacement using cardiac computed tomography: comparison with surgical findings. *Circ Cardiovasc Imaging* 2016; 9: e004153. [CrossRef]
 34. Cawley PJ, Hamilton-Craig C, Owens DS, Krieger EV, Strugnell WE, Mitsumori L, et al. Prospective comparison of valve regurgitation quantitation by cardiac magnetic resonance imaging and transthoracic echocardiography. *Circ Cardiovasc Imaging* 2013; 6: 48-57.
 35. Orwat S, Diller GP, Kaleschke G, Kerckhoff G, Kempny A, Radke RM, et al. Aortic regurgitation severity after transcatheter aortic valve implantation is underestimated by echocardiography compared with MRI. *Heart* 2014; 100: 1933-8. [CrossRef]
 36. Balzer J, Zeus T, Hellhammer K, Veulemans V, Eschenhagen S, Kehmeier E, et al. Initial clinical experience using the EchoNavigator (®)-system during structural heart disease interventions. *World J Cardiol* 2015; 7: 562-70. [CrossRef]
 37. Ruparelina N, Cao J, Newton JD, Wilson N, Daniels MJ, Ormerod OJ. Paravalvular leak closure under intracardiac echocardiographic guidance. *Catheter Cardiovasc Interv* 2018; 91: 958-65. [CrossRef]
 38. Nishimura RA, Otto CM, Bonow RO, Carabello BA, Erwin JP 3rd, Fleisher LA, et al. 2017 AHA/ ACC focused update of the 2014 AHA/ ACC guideline for the management of patients with valvular heart disease: a report of the American College of Cardiology/American Heart Association Task Force on clinical practice guidelines. *J Am Coll Cardiol* 2017; 70: 252-89. [CrossRef]
 39. Baumgartner H, Falk V, Bax JJ, De Bonis M, Hamm C, Holm PJ, et al. 2017 ESC/EACTS Guidelines for the management of valvular heart disease. *Eur Heart J* 2017; 38: 2739-91. [CrossRef]
 40. Abbruzzese PA, Meloni L, Cardu G, Napoleone A, Cherchi A, Martelli V. Intraoperative transesophageal echocardiography and periprosthetic leaks. *J Thorac Cardiovasc Surg* 1991; 101: 556-7. [CrossRef]
 41. Millán X, Bouhout I, Nozza A, Samman K, Stevens LM, Lamarche Y, et al. Surgery Versus Transcatheter Interventions for Significant Paravalvular Prosthetic Leaks. *JACC Cardiovasc Interv* 2017; 10: 1959-69. [CrossRef]
 42. Ozkan M, Aykan AC, Gürsoy O, Tuncer MA, Cakal B, Yildiz M, et al. An alternative approach for mitral paravalvular leak with Dacron patch curtaining under the guidance of real-time 3-dimensional transesophageal echocardiography. *Cardiology* 2011; 119: 34-7.
 43. Genoni M, Franzen D, Vogt P, Seifert B, Jenni R, Künzli A, et al. Paravalvular leakage after mitral valve replacement: improved long-term survival with aggressive surgery? *Eur J Cardiothorac Surg* 2000; 17: 14-9. [CrossRef]
 44. Alkhouli M, Rihal CS, Zack CJ, Eleid MF, Maor E, Sarraf M, et al. Transcatheter and surgical management of mitral paravalvular leak: long-term outcomes. *JACC Cardiovasc Interv* 2017; 10: 1946-56. [CrossRef]
 45. Wells JA 4th, Condado JF, Kamioka N, Dong A, Ritter A, Lerakis S, et al. Outcomes after paravalvular leak closure: transcatheter versus surgical approaches. *JACC Cardiovasc Interv* 2017; 10: 500-7. [CrossRef]
 46. Akins CW, Bitondo JM, Hilgenberg AD, Vlahakes GJ, Madsen JC, MacGillivray TR, et al. Early and late results of the surgical correction of cardiac prosthetic paravalvular leaks. *J Heart Valve Dis* 2005; 14: 792-9.
 47. Busu T, Alqahtani F, Badhwar V, Cook CC, Rihal CS, Alkhouli M. Meta-analysis Comparing Transcatheter and Surgical Treatments of Paravalvular Leaks. *Am J Cardiol* 2018; 122: 302-9. [CrossRef]
 48. Ozkan M, Gürsoy OM, Astarcioglu MA, Wunderlich N, Sievert H. Percutaneous closure of paravalvular mitral regurgitation with Vascular Plug III under the guidance of real-time three-dimensional transesophageal echocardiography. *Turk Kardiyol Dern Ars* 2012; 40: 632-41. [CrossRef]

49. Guler A, Tavlasoglu M, Kadan M, Barcin C. Transapical closure of mitral paravalvular leakage. *Eur J Cardiothorac Surg* 2013; 43: 861-3.
50. Krishnaswamy A, Kapadia SR, Tuzcu EM. Percutaneous paravalvular leak closure- imaging, techniques and outcomes. *Circ J* 2013; 77: 19-27. [\[CrossRef\]](#)
51. Kursaklioglu H, Barcin C, Iyisoy A, Baysan O, Celik T, Kose S. Percutaneous closure of mitral paravalvular leak via retrograde approach with use of the Amplatzer duct occluder II and without a wire loop. *Tex Heart Inst J* 2010; 37: 461-4.
52. Kilic T, Sahin T, Ural E. Percutaneous retrograde transfemoral closure of mitral paravalvular leak in 3 patients without construction of an arteriovenous wire loop. *Tex Heart Inst J* 2014; 41: 170-3.
53. Kilic T, Coskun S, Karauzum K, Yavuz S, Sahin T. Percutaneous Antegrade Trans-Septal Closure of Mitral Paravalvular Leak without Creation of an Arteriovenous Wire Loop in Patients with Coexistent Mechanical Aortic Valve. *J Heart Valve Dis* 2017; 26: 54-62.
54. Zhou D, Pan W, Guan L, Qian J, Ge J. Retrograde Transcatheter Closure of Mitral Paravalvular Leak through a Mechanical Aortic Valve Prosthesis: 2 Successful Cases. *Tex Heart Inst J* 2016; 43: 137-41.
55. Onorato EM, Muratori M, Smolka G, Malczewska M, Zorinas A, Zakarkaite D, et al. Midterm procedural and clinical outcomes of percutaneous paravalvular leak closure with the Occlutech Paravalvular Leak Device. *EuroIntervention* 2020; 15: 1251-9. [\[CrossRef\]](#)
56. Lampropoulos K, Aggeli C, Megalou A, Barbetseas J, Budts W. Diagnosis and Treatment of Left-Sided Prosthetic Paravalvular Regurgitation. *Cardiology* 2016; 133: 27-34. [\[CrossRef\]](#)
57. Garcia E, Arzamendi D, Jimenez-Quevedo P, Sarnago F, Martí G, Sanchez-Recalde A, et al. Outcomes and predictors of success and complications for paravalvular leak closure: an analysis of the Spanish real-wOrld paravalvular LEaks closure (HOLE) registry. *EuroIntervention* 2017; 12: 1962-8. [\[CrossRef\]](#)
58. Smolka G, Pysz P, Jasiński M, Roleder T, Peszek-Przybyła E, Ochała A, et al. Multiplug paravalvular leak closure using Amplatzer Vascular Plugs III: A prospective registry. *Catheter Cardiovasc Interv* 2016; 87: 478-87. [\[CrossRef\]](#)
59. Goktekin O, Vatankulu MA, Ozhan H, Ay Y, Ergelen M, Tasal A, et al. Early experience of percutaneous paravalvular leak closure using a novel Occlutech occluder. *EuroIntervention* 2016; 11: 1195-200. [\[CrossRef\]](#)
60. Calvert PA, Northridge DB, Malik IS, Shapiro L, Ludman P, Qureshi SA, et al. Percutaneous device closure of paravalvular leak: combined experience from the United Kingdom and Ireland. *Circulation* 2016; 134: 934-44. [\[CrossRef\]](#)
61. Pinheiro CP, Rezek D, Costa EP, Carvalho ES, Moscoso FA, Taborga PR, et al. Paravalvular regurgitation: clinical outcomes in surgical and percutaneous treatments. *Arq Bras Cardiol* 2016; 107: 55-62.
62. Angulo-Llanos R, Sarnago-Cebada F, Rivera AR, Corrales JE, Cuervo G, Solis J, et al. Two-year follow up after surgical versus percutaneous paravalvular leak closure: a non-randomized analysis. *Catheter Cardiovasc Interv* 2016; 88: 626-34. [\[CrossRef\]](#)
63. Feindel CM, Tufail Z, David TE, Ivanov J, Armstrong S. Mitral valve surgery in patients with extensive calcification of the mitral annulus. *J Thorac Cardiovasc Surg* 2003; 126: 777-82. [\[CrossRef\]](#)
64. Hansen JW, Gadey G, Piemonte TC. Prosthetic mitral valve paravalvular leak: A problem that requires dexterity. *Cardiovasc Revasc Med* 2018; 19: 126-32. [\[CrossRef\]](#)