

A rare association: concomitant presence of mitral valve blood cyst with atrial septal aneurysm and cor triatriatum dexter

Gökhan Özmen, Mehmet Demir, Hasan Arı, İbrahim Aktaş
Department of Cardiology, Bursa Yüksek İhtisas Education and Research Hospital; Bursa-Turkey

Introduction

Congenital heart valve cyst is a rare and asymptomatic condition mostly seen in the mitral and tricuspid valves (1). In some cases, surgery is required as these cysts may cause obstruction, valve dysfunction, and sometimes embolism (2, 3). We think that if a heart valve cyst is asymptomatic and does not alter valve function, periodic evaluation with echocardiography is a feasible option. Here we report a mitral valve blood cyst causing mild to moderate regurgitation. Concomitant atrial septal aneurysm and cor triatriatum dexter were also seen on examination.

Case Report

A 19-year-old woman was referred to our hospital with complaints of atypical chest pain. She seemed healthy, and her physical examination was normal except a 2/6 pansystolic soft murmur from the cardiac apex to the axilla. The electrocardiogram showed a normal sinus rhythm of 75 beats per min. Transthoracic 2D echocardiography revealed normal size and function of the chambers with a thin and moving interatrial septum. The same examination revealed a 15×17-mm cystic mass on the tip of the anterior mitral leaflet at the ventricular aspect of the chambers, and concomitant mild to moderate mitral regurgitation toward the interatrial septum could be seen (Fig. 1a, b).

The transesophageal echocardiogram (TEE) confirmed the mobile, round, and hypoechogenic thin-walled mass (15×17 mm) attached to the tip of the anterior mitral leaflet (Videos 1-3). Additionally, TEE revealed an atrial septal aneurysm and a large eustachian valve that normally arose from the inferior vena cava ostium and that was

attached to interatrial septum resulting in the partitioning of the right atrium into two chambers. The inferior vena cava flow was not blocked. These findings like with cor triatriatum dexter (Fig. 2).

Discussion

Intracardiac blood cysts, first defined by Elaser in 1844, are rare congenital malformations located in the endocardium of atrioventricular valves. Patients are mostly asymptomatic and are diagnosed in the pediatric age, particularly in the first months. Their appearance in adults is rare (1, 2).

Several hypotheses were proposed to explain the development of blood cysts.

- 1) Blood cysts are formed during valve development as a result of blood being pressed and trapped in crevices that are later sealed off.
- 2) Blood cysts are the result of hematoma formation in the subvalvular region secondary to the occlusion of small vascular branches of end arteries due to inflammation, vagal stimulation, anoxia, or hemorrhagic events.
- 3) Possible heteroplastic changes in the tissue that comes from primitive pericardial mesothelium.
- 4) Blood cysts simply represent ectatic or dilated blood vessels.
- 5) Myxomatous degeneration.

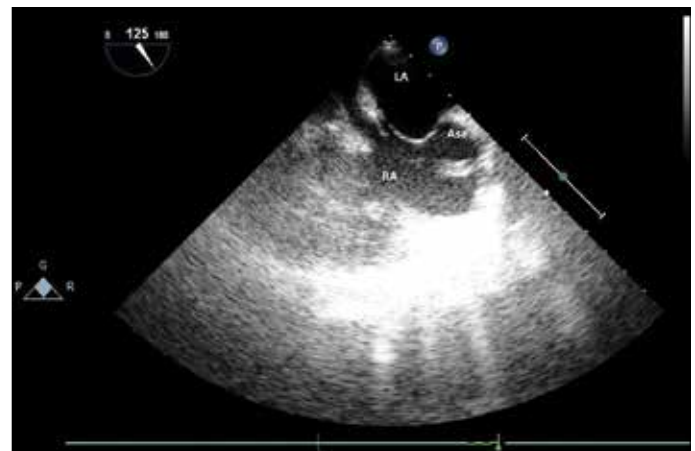

Figure 2. Transesophageal echocardiographic image showing an atrial septal aneurysm and cor triatriatum dexter

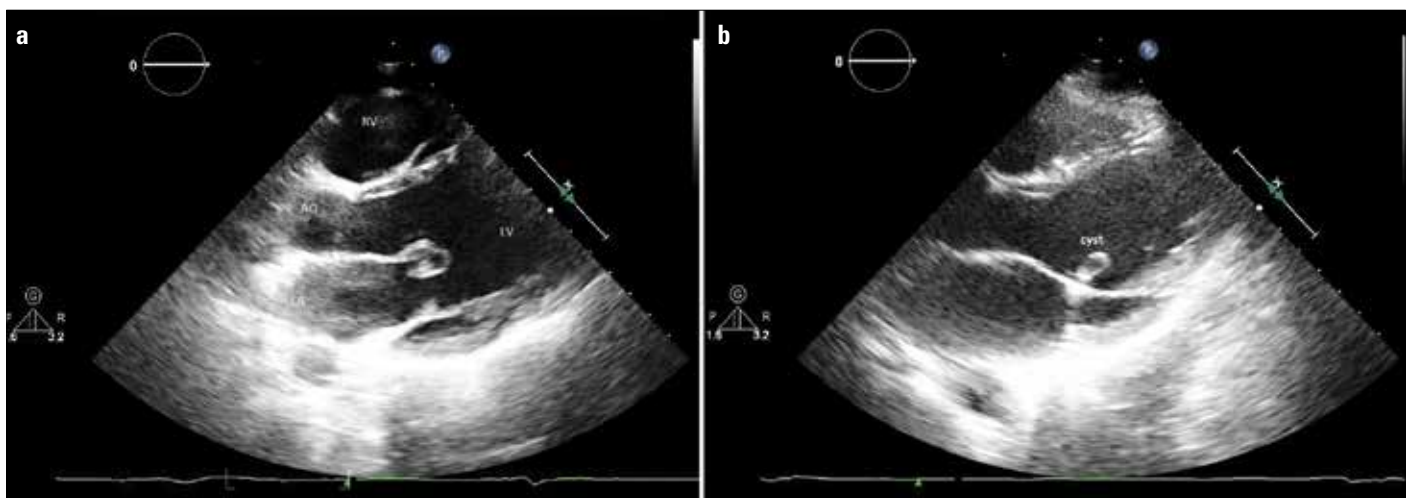


Figure 1. a, b. Transthoracic echocardiographic image showing a blood cyst on the anterior leaflet of the mitral valve (parasternal long-axis view)

However, there is still no consensus regarding the development of blood cysts (3-5).

Myxomatous degeneration is used in the context of mitral valve prolapse. This refers to the pathological weakening of connective tissue. In our case and also in some other reported cases, weak cardiac structures such as floppy interatrial septum, mitral leaflets, and embryological remnants like eustachian valve were reported. So these features support embryologic origin as mentioned by Zimmerman et al. (6).

There are controversies regarding therapy for blood cysts because long-term follow-up results are absent. Surgery is the therapy of choice for blood cysts, potential source of embolism and left ventricular outflow tract obstruction, even in asymptomatic patients to discriminate from cardiac malignancies (7).

The incidence of cor triatriatum is approximately 0.1% of congenital heart malformation. Typically, the right atrial partition is due to exaggerated fetal eustachian and thebesian valves, which together form an incomplete septum across the lower part of the atrium. This septum may range from a reticulum to a substantial sheet of tissue (8, 9).

In our case, the interatrial septum was thin and floppy, and the large eustachian valve membrane divided the right atrium into two (cor triatriatum dexter) (Fig. 1b). Complete persistence of the right sinus valve results in a separation between the smooth and trabeculated portions of the right atrium, resulting in cor triatriatum dexter. Both blood cyst and cor triatriatum dexter have not been described in echocardiographic literature before. However, Dencker et al. (4) described mitral cysts in both the anterior and posterior leaflets and incomplete cor triatriatum sinister.

According to some case reports, depending on which area of the heart is affected, blood cysts may result in a variety of clinical phenomena, including embolism, valvular dysfunction, and heart block (7, 10).

Conclusion

Blood cysts are rarely reported, so there is no consensus or guidelines for the optimal management of asymptomatic cases. Annual follow-up with echocardiography is our choice for this patient.

Video 1. Transthoracic echocardiographic image showing a blood cyst on the anterior leaflet of the mitral valve (parasternal long-axis view)

Video 2. Transesophageal echocardiographic image showing a blood cyst on the anterior leaflet of the mitral valve

Video 3. TEE demonstrates mitral regurgitation at the coaptation point of the anterior leaflet. The cyst causes the coaptation defect
ECG - electrocardiography; TEE - transesophageal echocardiography

References

1. Tanaka H, Ebato M, Narisawa T, Mori T, Masuda M, Suzuki T, et al. Atrial blood cyst with ischemic heart disease. *Circ J* 2003; 67: 91-2. [CrossRef]
2. Paşaoğlu I, Doğan R, Oram A, Özyılmaz F, Bozer AY. Giant blood cyst of the left ventricle. *Jpn Heart J* 1991; 32: 147-51. [CrossRef]
3. Minneci C, Casolo G, Popoff G, Sulla A, Comin CE, Pedemonti E. A rare case of left ventricular outflow obstruction. *Eur J Echocardiogr* 2004; 5: 72-5. [CrossRef]
4. Dencker M, Jexmark T, Hansen F, Tydén P, Roijer A, Lühns C. Bileaflet blood cysts on the mitral valve in an adult. *J Am Soc Echocardiogr* 2009; 22: 1085-8. [CrossRef]
5. Xie SW, Lu OL, Picard MH. Blood cyst of the mitral valve: detection by transthoracic and transesophageal echocardiography. *J Am Soc Echocardiogr* 1992; 5: 547-50. [CrossRef]
6. Zimmerman KG, Paplanus SH, Dong S, Nagle RB. Congenital blood cysts of the heart valves. *Hum Pathol* 1983; 14: 699-703. [CrossRef]
7. Park MH, Jung SY, Youn HJ, Jin JY, Lee JH, Jung HO. Blood cyst of subvalvular apparatus of the mitral valve in an adult. *J Cardiovasc Ultrasound* 2012; 20: 146-9. [CrossRef]
8. Embrey RP. Cor triatriatum, pulmonary vein stenosis, atresia of the common pulmonary vein. Mavroudis C, Backer CL, editors. *Pediatric cardiac surgery*. 2nd ed. St Louis. Mosby-Year Book; 1994. p. 503-4.
9. Alboliras ET, Edwards WD, Driscoll DJ, Seward JB. Cor triatriatum dexter: two-dimensional echocardiographic diagnosis. *J Am Coll Cardiol* 1987; 9: 334-7. [CrossRef]
10. López-Pardo F, López-Haldón J, Granado-Sánchez C, Rodríguez-Puras MJ, Martínez-Martínez A. A heart inside the heart: blood cyst of mitral valve. *Echocardiography* 2008; 25: 928-30. [CrossRef]

Address for Correspondence: Dr. Gökhan Özmen, Bursa Yüksek İhtisas Eğitim ve Araştırma Hastanesi, Kardiyoloji Bölümü, 152 Evler Mah. Prof. Tezok Cad. Yıldırım, Bursa-Türkiye

Phone: +90 532 711 60 32

E-mail: gokhanozmendr@gmail.com

Available Online Date: 22.05.2015

©Copyright 2015 by Turkish Society of Cardiology - Available online at www.anatoljcardiol.com
DOI:10.5152/akd.2015.5984



Hybrid approach of percutaneous mitral valve repair with the MitraClip followed by off-pump coronary artery bypass grafting

Mehmet Bilge^{1,2}, Sina Ali¹, Yakup Alsancak¹, Ayşe Saatçi Yaşar¹
¹Division of Cardiology, Atatürk Education and Research Hospital; Ankara-Turkey
²Division of Cardiology, Faculty of Medicine, Yıldırım Beyazıt University; Ankara-Turkey

Introduction

The management of patients with concomitant severe ischemic mitral regurgitation (IMR) and coronary artery disease is challenging. The combined surgical approach is burdened by a high risk of morbidity and mortality, especially in the presence of severe left ventricular systolic dysfunction (1). However, mitral valve repair with MitraClip® (Abbott Vascular, Santa Clara, CA, USA) is a new and promising therapeutic option that has recently been introduced as an alternative approach in patients who have a high risk for mitral valve surgery. Although the hybrid approach is a theoretically possible technique in the treatment of patients with concomitant coronary artery disease and severe IMR and who are at a high risk or unsuitable for conventional surgery, to the best of our knowledge, there is no published case available on the use of this technique.

Case Report

A 68-year-old man with a history of atrial fibrillation, stroke in 2010, myocardial infarction, and heart failure for the preceding two months was referred to our hospital because of symptomatic severe IMR and