

Intracoronary shunt use in an adult patient with Bland-White-Garland syndrome

Bland-White-Garland sendromlu yetişkin hastada intrakoronar şant kullanımı

The anomalous origin of the left coronary artery from the pulmonary artery (ALCAPA or Bland-White-Garland syndrome) is a rare congenital heart defect with an incidence of 1 in 300.000 live births (1). Although it is the most common congenital coronary artery anomaly comprising 0.24%-0.46% of all congenital cardiac anomalies, only 10% of patients survive to adulthood (1, 2).

A 44-year old man was referred to our clinic because of chest pain on exertion. Left main coronary artery (LMCA) could not be visualized during conventional coronary angiography. Computed tomography angiography revealed abnormal origin of the left coronary artery from the pulmonary artery (PA) and muscular bridging of the left anterior descending (LAD) coronary artery (Fig. 1). During the operation, aortic arterial and bicaval venous cannulation, intermittent antegrade and retrograde blood cardioplegia were used. Right coronary artery was aneurysmatic due to collateral flow (Fig. 2A, B). Through the pulmonary arteriotomy, LMCA orifice was seen to be originating from the left posterior sinus of PA and

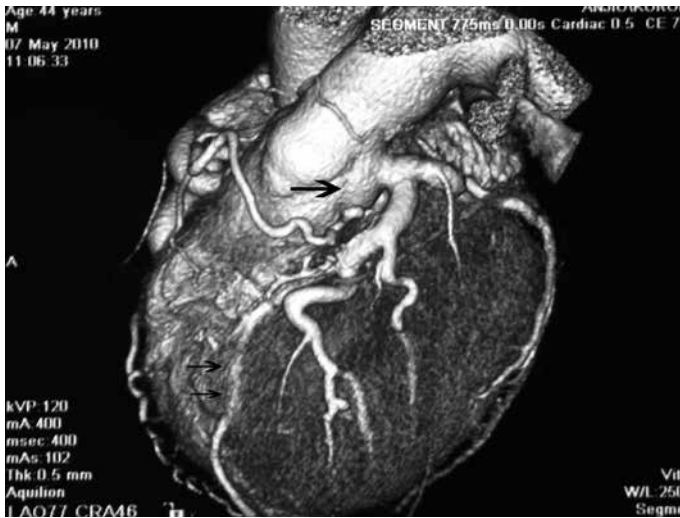


Figure 1. Multislice computed tomography angiography view of left main coronary artery arising from the pulmonary artery and muscular bridging in the left anterior descending artery (angiography)

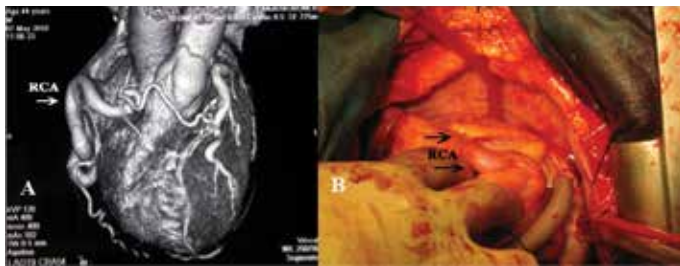

Figure 2. A) Multislice computed tomography angiography view of aneurysmatic right coronary artery originating from the aorta, B) Intraoperative view of the aneurysmatic dilatation of the right coronary artery due to high flow

it was closed primarily by Teflon pledgeted 4/0 polypropylene sutures. Excessive systemic collateral flow was impeding exposure despite a properly placed aortic cross-clamp and a fully arrested and vented heart. Intracoronary shunts (ClearView® Medtronic Inc. Minneapolis, MN, USA) were used to divert flow away from the site of anastomosis. Left internal mammary artery and a saphenous vein graft were anastomosed to LAD and circumflex artery respectively. The patient was discharged on the sixth postoperative day after an uneventful recovery. He is well and free of ischemic symptoms in his second year following the operation.

In untreated adult ALCAPA patients, sudden death secondary to myocardial ischemia and cardiomyopathy is seen with an incidence of 80-90% at a mean age of 35 years (1, 2). Although establishing dual coronary circulation in childhood is a common practice, treatment of this anomaly in adult patients is controversial. Among various treatment options, establishing dual coronary circulation seems to provide better survival and significant recovery in ventricular functions (1, 3, 4). We performed combined simple closure and coronary artery bypass procedure to establish dual coronary circulation.

About 10% of ALCAPA patients can survive to adulthood by well-developed intercoronary and extra coronary systemic collaterals (mainly from the bronchial arteries) (2, 4). Excessive collateral flow is a challenge during administration and maintenance of cardioplegia and coronary anastomoses in these patients (3-5). In order to facilitate anastomoses, several techniques have been suggested such as gentle compression of atrioventricular groove (3) but to our knowledge, this is the first report suggesting use of an intracoronary shunt during such an on-pump procedure. Contrary to the common knowledge that intracoronary shunts are used in off-pump surgery, we used them in an on-pump procedure because excessive collateral blood flow was impeding exposure for anastomoses and further manipulation or coronary clamping were avoided.

In adult ALCAPA patients, prompt treatment provides better survival. Closure of the LMCA ostium and bypass grafting to LAD may give satisfactory results in these patients. The use of an intracoronary shunt provides a bloodless and clear exposure for precise anastomoses during coronary artery bypass grafting in this patient group.

Berk Özkaynak¹, Özgür Yıldırım², Adil Orman³, Ahmet Özdemir⁴
¹Clinic of Cardiovascular Surgery, Bağcılar Education and Research Hospital, İstanbul-Turkey
²Clinic of Cardiovascular Surgery, Medicana International Hospital, İstanbul-Turkey
³Clinic of Cardiology, Mersin State Hospital, Mersin-Turkey
⁴Clinic of Cardiovascular Surgery, Medikar Hospital, Karabük-Turkey

References

1. Murala JS, Sankar MN, Agarwal R, Golla PN, Nayar PG, Cherian KM. Anomalous origin of left coronary artery from pulmonary artery in adults. *Asian Cardiovasc Thorac Ann* 2006; 14: 38-42.
2. Meader M, Vogt PR, Ammann P, Rickli H. Bland-White-Garland syndrome in a 39-year old mother. *Ann Thorac Surg* 2004; 78: 1451-3.
3. Rodrigues AJ, Vicente WV, Bassetto S, Filho AS. Anomalous origin of the left coronary artery from the pulmonary artery in an adult with systemic collateral circulation to the left coronary artery. *Ann Thorac Surg* 2004; 78: 1082-4.
4. Dodge-Khatami A, Mavroudis C, Backer CL. Anomalous origin of the left coronary artery from the pulmonary artery: collective review of surgical therapy. *Ann Thorac Surg* 2002; 74: 946-55.
5. Arsan S, Naseri E, Keser N. An adult case of Bland White Garland syndrome with huge right coronary aneurysm. *Ann Thorac Surg* 1999; 68: 1832-3.

Address for Correspondence/Yazışma Adresi: Dr. Berk Özkaynak
Bağcılar Eğitim ve Araştırma Hastanesi, Kalp ve Damar Cerrahisi Kliniği
Merkez Mah. 6. Sok. Bağcılar, 34200 İstanbul-Türkiye
Phone: +90 212 440 40 00 Fax: +90 212 440 42 42
E-mail: berkozaynak2005@hotmail.com

Available Online Date/Çevrimiçi Yayın Tarihi: 08.08.2012

©Telif Hakkı 2012 AVES Yayıncılık Ltd. Şti. - Makale metnine www.anakarder.com web sayfasından ulaşılabilir.

©Copyright 2012 by AVES Yayıncılık Ltd. - Available on-line at www.anakarder.com
doi:10.5152/akd.2012.201

Successful management of an unwanted complication; VAC therapy

İstenmeyen bir komplikasyonun başarılı tedavisi; VAC terapi

Median sternotomy is the most common approach in cardiac surgery with 3% risk of mediastinitis development despite sterile techniques, antibiotics and appropriate wound care. Post-sternotomy mediastinitis (PSM) is a serious condition associated with 30% mortality rate. Treatment of this unwanted condition includes debridement, antibiotic irrigation and reconstruction with omentum or pectoral muscle. Due to its

challenging nature, management of PSM became a subject of scientific interest. Comprehension of the crucial role of early extubation and mobilization in the acceleration of wound healing besides the benefits of sufficient microvascular blood supply as well as edema reduction; application of topical negative pressure (Vacuum assisted closure method; VAC therapy) has been suggested with identification of the rapid closure of the wound via increase in granulation tissue. Being first used by Obdeijn et al. for the treatment of PMS in 1999, VAC therapy has become popular in USA by Argenta and Morykwas in 1995 and in Europe in 1997 (1).

Past studies revealed 4-fold increase in microcirculation by application of 125 mmHg negative pressure, while the opposite effect in case of 400 mmHg negative pressure. In patients with use of internal thoracic artery for bypass, reduction in blood flow to peristernal wound margins was demonstrated to lead to a delay in the wound healing with benefits of negative pressure application via positive effects on the blood circulation. Depending on the size of the wound, VAC can be performed based on 5-12 sessions with 48-72 hour intervals. In patients under warfarin therapy, it is possible to perform procedure by switching to low molecular weight heparin when necessary. In larger mediastinal defects including heart with bypassed grafts, controlled application of lower pressure (75-100 mmHg) as well as prevention of the risk of right ventricle rupture via use of barrier isolating polyvinyl alcohol from sterile gas seems possible (2-5).

A total of 7 patients (obese and with short sternum) who were applied with VAC therapy for the mediastinal sternal wound infection following coronary bypass surgery performed in our hospital between 2009-2012 were included in this study (Table 1). Partial (2/3 of the region)

Table 1. Patients` characteristics

Patient	Age, gender	BMI, kg/m ²	Comorbidity	Operation	CPB time	C-RP WBC	Tissue culture	VAC therapy+ Antibiotic
1	65, M	25.1	HT HPL Type 2 DM Cigarette	LIMA-LAD Ao-OM Ao-Rdp	55 min	26 mg/L 13.4 g/L	<i>S. epidermidis</i>	10 sessions (20 day) + ampicillin + sulbactam (4x2gr)
2	73, F	27.3	HT HPL Type 2 DM	LIMA-LAD Ao-Rdp Mitral repair	78 min	54 mg/L 16.1 g/L	<i>S. aureus</i>	8 session (17 day) + daptomysin (1x500 mg)
3	71, F	26.9	HT COPD HPL Type 2 DM	LIMA-LAD Ao-D Ao-OM Ao- RCA	68 min	68 mg/L 12.6 g/L	<i>S. aureus</i>	8 session (16 day) + vancomysin (4x500 mg)
4	66, M	24.8	HT HPL Cigarette	LIMA-LAD AO-IM-OM Ao-Rdp	67 min	46 mg/L 11.3 g/L	<i>S. aureus</i>	9 session (18 day) + vancomysin (4x500 mg)
5	76, M	25.8	COPD HPL Type 2 DM	LIMA-LAD Ao-D-OM Ao-RCA	73 min	74 mg/L 15.6 g/L	<i>S. epidermidis</i>	5 session (10 day) + ampicillin + sulbactam (4x2 gr)
6	71, F	25.6	HT COPD HPL	LIMA-LAD Ao-RCA	46 min	83 mg/L 14.4 g/L	<i>S. epidermidis</i>	6 session (12 day) + ampicillin + sulbactam (4x1 gr)
7	78, M	26.4	HT HPL Type 2 DM	LIMA-LAD Ao-IM Ao-Rdp	54 min	52 mg/L 11.4 g/L	<i>S. epidermidis</i>	7 session (15 day) + ampicillin + sulbactam (4x2 gr)

Ao - aorta, BMI-body mass index, COPD - chronic obstructive pulmonary disease, CPB - cardiopulmonary bypass, C-RP - C- reaktif protein, D - diagonal coronary branch, DM - diabetes mellitus, HPL - hyperlipidemia, HT - hypertension, IM - intermediate coronary branch, LAD - left anterior descending artery, LIMA - left internal mammary artery, OM - obtuse marginal coronary branch, RCA - right coronary artery, Rdp - right posterior descending coronary branch, VAC - vacuum assisted device, WBC - white blood cell (leukocyte)