

## An unusual localization of cyst hydatidosis associated with cardiac hydatid disease

*Hidatik kistin alışılmadık lokalizasyonu ve kardiyak kist hidatikle beraberliği*

Metin Demircin, Ömer Faruk Doğan, Meral Kanbak\*

From Departments of Cardiovascular Surgery and \*Anesthesia, Medical Faculty, Hacettepe University, Ankara, Turkey

A 50-year-old woman was admitted to our clinic for surgical removal of cardiac hydatid cyst. Before the admission, she had been referred to other clinic with signs and complaints of a large mass in the medial aspect of the left upper leg and severe pain. A multiloculated hydatid cyst between the iliopsoas and pectineus muscle had been diagnosed using an ultrasonography and magnetic resonance imaging (MRI). Magnetic resonance images demonstrated a well-defined cystic mass containing a few round lesions. The mother cyst had a thin, low-signal intensity rim on T1 and T2 weighted sequences. The daughter cyst exhibited a very low signal on T1-weighted images. Indirect hemagglutination and Western-Blot tests for echinococcus antibodies were also positive. After the diagnosis, albendazole 10 mg/kg daily for three months had been given immediately. At the follow-up, the symptoms disappeared and the MRI confirmed that the amount of the cystic lesions have decreased and

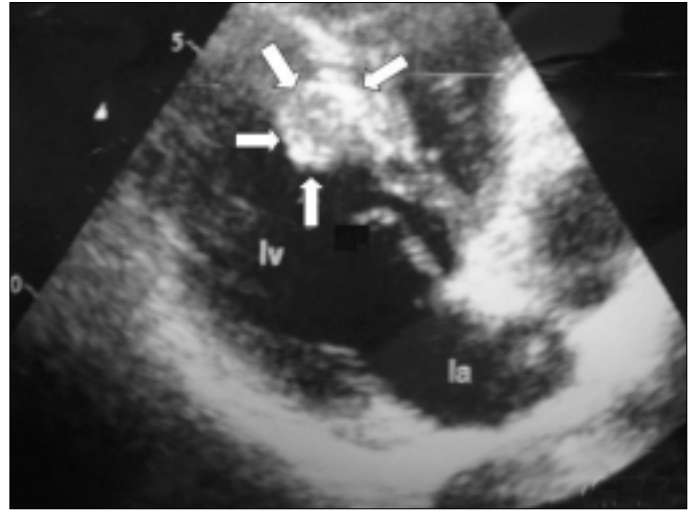


Figure 2. The echocardiographic image demonstrates cardiac hydatid cyst, 1.9x1.3 cm in size, located in interventricular septum (Arrowhead)

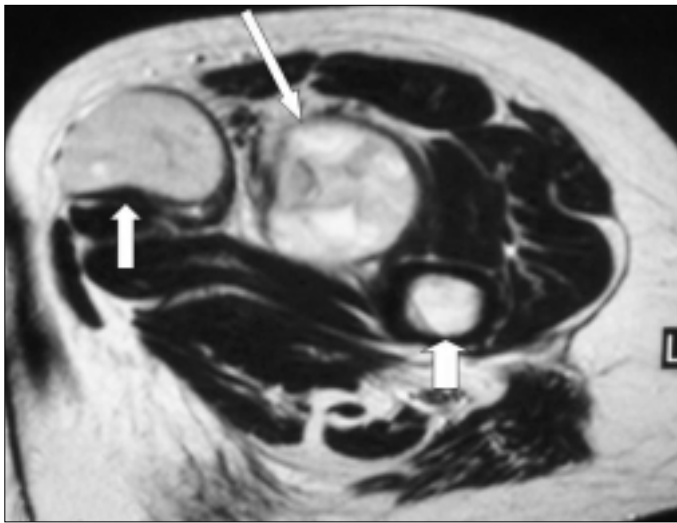


Figure 1. Sagittal T2 weighted magnetic resonance imaging of left upper leg demonstrates a regressed and calcified hydatid cyst in muscle two months after albendazole treatment

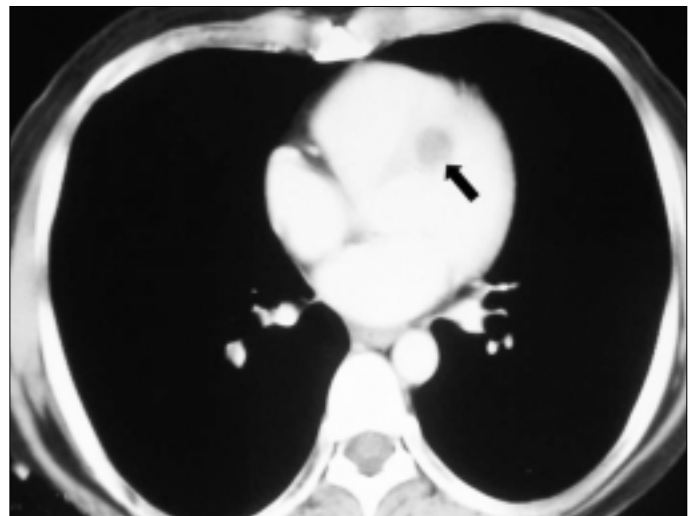


Figure 3. Thoracic computed tomography demonstrating a cystic lesion located in interventricular septum (Arrowhead)

became calcified (Fig. 1). But, transthoracic echocardiography and chest computed tomography revealed a cardiac hydatid cyst, 19x13 mm in size, originated from the interventricular septum (Fig. 2 and Fig. 3). Therefore, the patient underwent operation for removal of hydatid cyst in interventricular septum. We prescribed albendazole 10 mgr/kg daily for three months to prevent recurrence postoperatively.

This case emphasizes that in endemic areas with high occurrence of hydatid infestation, physicians should have a high index of suspicion when patients present with slowly growing cystic mass in musculoskeletal system. The preoperative work-up including ultrasonography, transthoracic echocardiography, and total body computed tomography must be performed routinely as we show in this case.

### VEDA

Çok ileri bir tarihte  
Çok yaşlı olarak  
Sessizce ayrılmalıyım  
Kimseye pek gözükmeden  
Ve kimseyi rahatsız etmeden.

Masamın üzerinde  
Dünden kalan işler  
Tamamlanmamış yazılar  
Okunmayı bekleyen kitaplar  
Ve anılar ve umutlar.

Filleri kuyruğundan çekerek  
Tepeleri aşırıtmaktı görevim  
Günler bitti filler tükenmedi  
Ben elimden geleni yaptım  
Gerisini siz tamamlayın.

Boşa geçmedi hayatım  
Daha fazlası olabilirdi ama  
'Buna da şükür' demeliyim  
İşte sevgili dostlar  
Ben böyle veda etmeliyim.

**Ismail Cem**  
**New York, 1995**