

## Paroxysmal Syncope Induced by Severe Kinked Ascending Aortic Graft

A 48-year old man underwent ascending aorta replacement after being diagnosed with ascending aortic aneurysm at another institution 4 years previously. After discharge, the patient appeared to have paroxysmal dizziness, which relieved after about 5 seconds. About 1 year ago, the patient developed paroxysmal syncope, which currently occurs 1-2 times a month.

### E-PAGE ORIGINAL IMAGE

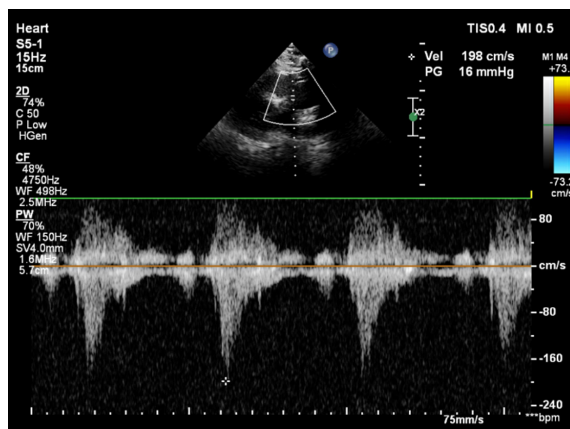


Figure 1. Transthoracic echocardiography confirmed that the narrow part of kinked graft and its pressure gradient was 16 mm Hg and the velocity of blood flow was 198 cm/s.

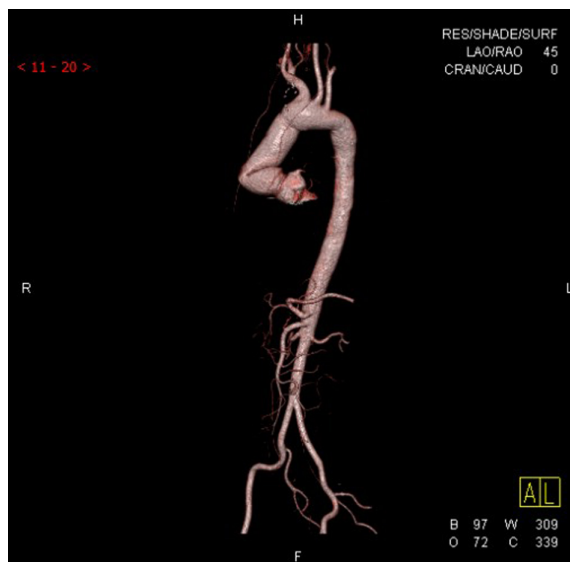

Figure 2. The 3D reconstruction by CT revealed the severely kinked graft. CT, computed tomography.

He Dongsheng <sup>ID 1</sup>  
Li Yifan <sup>ID 2</sup>  
Tang Juan <sup>ID 3,4</sup>  
Wu Zhong <sup>ID 2</sup>

<sup>1</sup>Department of Cardiothoracic Surgery, First Affiliated Hospital of Chengdu Medical College, Chengdu, China  
<sup>2</sup>Department of Cardiovascular Surgery, West China Hospital, Sichuan University, Chengdu, China  
<sup>3</sup>Acupuncture and Moxibustion School of Teaching Hospital of Chengdu University of TCM, Chengdu, China  
<sup>4</sup>Ministry of Education, Key Laboratory of Hainan Trauma and Disaster Rescue, College of Emergency and Trauma, Hainan Medical University, Haikou, China

Corresponding author:  
Wu Zhong  
✉ wuzhong71@163.com

Cite this article as: Dongsheng H, Yifan L, Juan T, Zhong W. Paroxysmal syncope induced by severe kinked ascending aortic graft. *Anatol J Cardiol.* 2022;26(10):E-16-E-17.

DOI:10.5152/AnatolJCardiol.2022.2118



Copyright@Author(s) - Available online at anatoljcardiol.com.  
Content of this journal is licensed under a Creative Commons Attribution-NonCommercial 4.0 International License.

The physical examination showed that the vital signs were normal. Laboratory examination showed no significant abnormality. Transthoracic echocardiography revealed an increased pressure gradient (16 mm Hg) and high velocity jet (198 cm/s) in proximal graft from the right parasternal window (Figure 1). Further evaluation of bilateral carotid and vertebral artery ultrasound showed no significant abnormalities. Enhanced computed tomography and 3D reconstruction revealed a severely kinked graft caused by inappropriate length (Figure 2).

During the redo-operation, we replaced the ascending aortic graft and released the kinking part. After operation, paroxysmal syncope did not appear again. His postoperative course was uneventful, and he was discharged on postoperative day 5.

---

**Informed Consent:** Written informed consent has been obtained from the patient to share and publish his medical history and examination results in this paper.