

Myocardial fibrosis detected by cardiac magnetic resonance imaging in heart failure: impact on remodeling, diastolic function and BNP levels

Kalp yetersizliğinde kardiyak manyetik rezonans görüntüleme ile saptanan miyokardiyal fibrozis: Yeniden şekillenme, diyastolik fonksiyon ve BNP seviyeleri üzerine etki

Gamze Babür Güler, Tansu Karaahmet¹, Kürşat Tigen

Cardiology Clinic, Kartal Koşuyolu Training and Research Hospital, İstanbul
¹Department of Cardiology, Faculty of Medicine, Acıbadem University, İstanbul, Turkey

ABSTRACT

Myocardial fibrosis, progressive over-accumulation of extracellular matrix (ECM) components in cardiac muscle, defined as a key component of heart failure and since then various studies showed a strong connection between fibrosis and progression of heart failure. The impaired left ventricular diastolic and systolic functions that are originated by fibrosis are used to predict poor clinical outcome in dilated cardiomyopathy. Even though endomyocardial biopsy is still considered as a gold standard, various noninvasive imaging techniques have been used to detect presence, location and extend of myocardial fibrosis. Cardiac magnetic resonance emerged as a crucial noninvasive imaging technique because of its high accuracy and high fidelity in detection of fibrosis. The noninvasive assessment of fibrosis is advantageous in early prediction of possible adverse outcomes and creates an opportunity to utilize new therapeutic approaches that target fibrosis in heart failure.

(*Anadolu Kardiyol Derg 2011 1: 71-6*)

Key words: Myocardial fibrosis, cardiac magnetic resonance, heart failure, remodeling, natriuretic peptide

ÖZET

Miyokardiyal fibrozis kalp kasında ekstraselüler matriks bileşenlerinin progresif birikimidir. Fibrozis ve kalp yetersizliği progresyonu arasındaki kuvvetli ilişki gösterildiğinden beri kalp yetersizliğinin anahtar bir bileşeni olarak kabul edilmektedir. Fibrozisin sebep olduğu bozulmuş sol ventrikül diyastolik ve sistolik fonksiyonlar; dilate kardiyomyopatide kötü klinik sonlanımın öngördürücüleridir. Endomyokardiyal biyopsi, altın standart olarak gösterilse de miyokardiyal fibrozisin varlığını, yerleşim yerini ve yaygınlığını saptayabilen çeşitli noninvaziv görüntüleme teknikleri bulunmaktadır. Kardiyak manyetik rezonans; fibrozisin saptanmasındaki yüksek doğruluk ve güvenilirliği sebebiyle önemli bir noninvaziv görüntüleme tekniği olarak belirmiştir. Fibrozisin noninvaziv değerlendirilmesi; olası kötü sonlanım noktalarının erken öngörülmesinde avantajlı olabilir ve kalp yetersizliğinde fibrozisi hedef alan yeni terapötik yaklaşımlardan yararlanma fırsatı yaratabilir.

(*Anadolu Kardiyol Derg 2011 1: 71-6*)

Anahtar kelimeler: Miyokardiyal fibrozis, kardiyak manyetik rezonans, kalp yetersizliği, yeniden şekillenme, natriüretik peptid

Introduction

The presence of myocardial fibrosis is an important aspect of heart failure (HF) and an index of poor prognosis. Cardiac fibrosis can be defined as progressive accumulation of extracellular matrix (ECM) components like collagens I, III, IV, laminin, fibronectin within the myocardium (1). In patients with non-

ischemic dilated cardiomyopathy (NICM), myocardial fibrosis has been observed pathologically (2). A histological analysis of dilated cardiomyopathy reveal changes in collagen content at the protein level, an increase in the absolute amounts of both type I collagen and type III collagen, while a significant increase is observed in the ratio of type I collagen to type III collagen (3). Several neurohumoral or growth factors such as angiotensin II

Address for Correspondence/Yazışma Adresi: Dr. Kürşat Tigen, Kartal Koşuyolu Yüksek İhtisas Eğitim ve Araştırma Hastanesi, Kardiyoloji Kliniği, İstanbul, Turkey
Phone: +90 216 459 44 40 Fax: +90 216 459 63 21 E-mail: mktigen@yahoo.com

Accepted Date/Kabul Tarihi: 28.12.2010 **Available Online Date/Çevrimiçi Yayın Tarihi:** 11.01.2011

©Telif Hakkı 2011 AVES Yayıncılık Ltd. Şti. - Makale metnine www.anakarder.com web sayfasından ulaşılabilir.

©Copyright 2011 by AVES Yayıncılık Ltd. - Available on-line at www.anakarder.com

doi:10.5152/akd.2011.013

(Ang II), endothelin-1 (ET-1), cardiotrophin-1 (CT-1), norepinephrine (NE), aldosterone, fibroblast growth factor 2 (FGF2), platelet-derived growth factor (PDGF), and transforming growth factor- α (TGF- α) have been implicated in the development of cardiac fibrosis (4).

Fibrosis can be reparative or reactive; "reactive" fibrosis, in which collagen accumulates in perivascular and interstitial tissue, is not accompanied by myocyte loss while in "replacement (reparative)" fibrosis myocyte loss and secondary microscopic scarring is detected (5). The distribution and extent of fibrosis depend on the etiology of the heart failure. Ischemic cardiomyopathy is characterized by areas of reparative fibrotic scarring that typically involve the subendocardium (6) and it can be also detected in remote areas other than ischemic scar (7). Although both reparative and reactive fibrosis occurs in the non-ischemic cardiomyopathy, reactive fibrosis usually predominate the deranged myocardial histology (8). Late gadolinium enhancement in CMR indicates different fibrosis patterns between ischemic and non-ischemic cardiomyopathy. In ischemic cardiomyopathy subendocardial and transmural enhancement is observed while in NICM usually patchy or longitudinal stria of midwall enhancement is more common (9).

Since myocardial fibrosis augment left ventricular (LV) stiffness, reduces LV compliance, impairs the diastolic and systolic function and decreases the cardiac output (2), evaluation of the presence and degree of cardiac fibrosis is crucial. In this review we will portray advantages of cardiac magnetic resonance imaging for detecting cardiac fibrosis and its importance in clinical practice, moreover we will discuss how CMR based approach may provide insights for prognostic determinants of non-ischemic cardiomyopathy such as LV remodeling, diastolic dysfunction, brain natriuretic peptide levels.

Cardiac fibrosis and cardiac magnetic resonance

Tissue biopsies are used for verification of cardiac fibrosis traditionally, but the evolution of noninvasive imaging techniques and the advances in biochemical assays for detection of serum collagen biomarkers provides new avenues to reveal myocardial fibrosis (10). Noninvasive techniques such as echocardiography (backscatter analysis, tissue Doppler imaging), nuclear imaging (single-photon emission computed tomography-molecular labeling, positron emission tomography-perfusible tissue index), cardiac magnetic resonance (delayed enhancement, T1 mapping, tissue tagging), collagen biomarkers (carboxy-terminal pro-peptide of pro-collagen type I (PICP) and ratio of matrix metalloproteinase type 1 to tissue inhibitor of metalloproteinase type 1(MMP-1/TIMP-1)) have been used frequently for the assessment of fibrosis (7).

Cardiovascular magnetic resonance (CMR) imaging is a useful tool to evaluate myocardial function, morphology and tissue structure. The indications for CMR in heart failure are reported as serial assessment of biventricular structure, size, and function (11); viability assessment before revascularization (11); differentiation of ischemic versus non-ischemic cardiomyopathy (9); evaluation of specific cardiomyopathies (such as arrhythmo-

genic right ventricular cardiomyopathy, cardiac amyloidosis, cardiac sarcoidosis) (11) and assessment of mechanical dyssynchrony before resynchronization therapy (12).

Delayed enhancements on cardiac magnetic resonance (DE-CMR) imply myocardial fibrosis regardless of the etiology of the damage. The principle behind delayed contrast-enhancement in CMR imaging is that gadolinium-based contrast agents, which are inert and cannot cross the myocyte cell membrane, diffuse passively and accumulate in the extracellular space and demonstrate delayed washout from extracellular space areas that are enlarged by fibrous replacement (13). Moreover, late gadolinium enhancement (LGE) shows a strong correlation with histological markers of fibrosis (14) and surrounding areas of abnormal contrast enhancement can be used to obtain tissue samples while performing an endomyocardial biopsy which in turn would increase diagnostic yield (15). Figure 1 demonstrates three different patients with various forms of late gadolinium enhancement in CMR.

The detection of delayed enhancement in CMR is associated with necrosis and irreversible fibrotic changes after myocardial infarction (16) and reflects myocardial fibrosis in NICM (9). DE-CMR is useful to detect presence, location, extend of myocardial scar and it may give hints about the nature of the scar (16). Ischemic fibrosis usually shows subendocardial and transmural distribution of delayed enhancement whereas non-ischemic fibrosis shows subepicardial even irregular and intramural distribution of delayed enhancement (17). The extent of myocardial

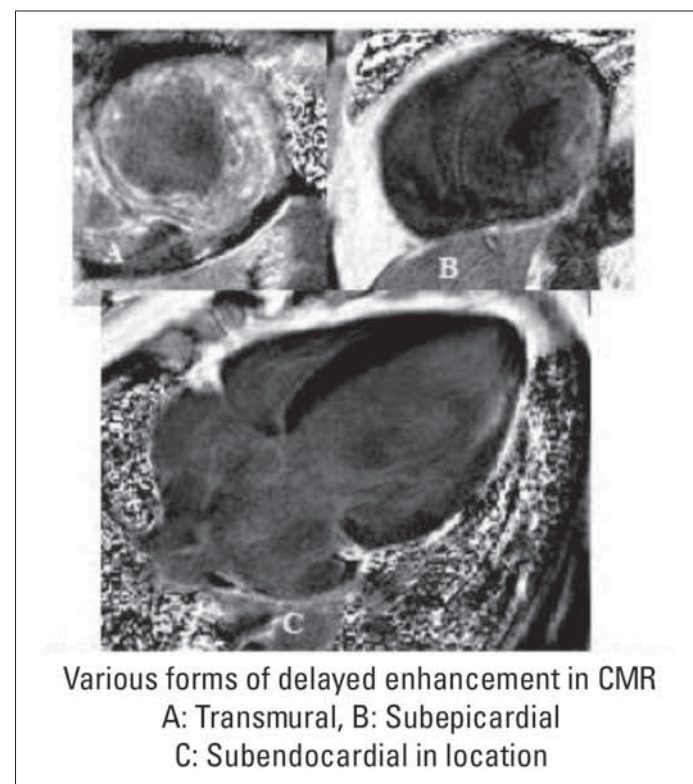


Figure 1. Three different patients with various forms of late gadolinium enhancement in CMR

CMR - cardiac magnetic resonance imaging

fibrosis is as crucial as its location; diffuse subendocardial delayed enhancement on CMR was linked to significant intraventricular systolic dyssynchrony (18). The identification presence and location of fibrosis by DE-CMR can assist to discern the etiology of heart failure from ischemic to non-ischemic and patient management is planned according to this simple categorization. However in non-ischemic dilated cardiomyopathy, usually diffuse interstitial fibrosis is observed and since it is hard to find a nonfibrotic reference point in myocardium at a diffuse fibrosis back-ground the implementation of delayed enhancement CMR is limited (7). Contrast enhanced T1 mapping has been developed to quantify diffuse non-ischemic myocardial fibrosis (19).

The prognostic importance of LGE in myocardial disease has been documented in previous studies (20, 21) such that in ischemic settings, LGE-CMR could provide support to predict recovery of contractile function after revascularization (22) and assist in detecting viability in transmural scars (23). In a survival analysis, 349 ischemic cardiomyopathy were evaluated by LGE CMR and scars that engage >30% of total myocardium was detected as an independent predictor of death or indication for cardiac transplantation (24). In another study, in symptomatic dilated cardiomyopathy (DCM), mid-wall fibrosis determined by CMR and an association with high rate of all cause mortality, cardiovascular hospitalization even after adjustment for age, LV function, and ventricular volumes was found (20). Moreover, LGE-CMR can be used to detect arrhythmogenic substrate due to fibrosis (25) and to distinguish the patients in need of sophisticated therapeutic interventions such as implantable cardioverter-defibrillators, biventricular pacemakers (12) and LV assist device (26) in DCM. Finally, CMR is a favorable imaging alternative to serial CMR scans for monitoring disease progression and effectiveness of treatment because it is high accurate/reproducible while it doesn't require ionizing radiation (11).

Cardiac fibrosis and LV remodeling

Cardiac remodeling is thought to be a key determinant of the clinical outcome in heart disease and it is characterized by a structural rearrangement of the cardiac chambers that involves cardiomyocyte hypertrophy, fibroblast proliferation, and increased deposition of extracellular matrix proteins (4). In LV remodeling, the left ventricle morphology is deformed from ellipsoidal to spherical form (2) and this deformation initiates a series of events beginning with increased wall stress, afterload mismatch, episodic subendocardial hypoperfusion, increased oxygen utilization, increased oxidative stress and increased free oxygen radical production with secondary alteration in gene expression of inflammatory pathways like tissue necrosis factor- α and interleukin-1 (2). The alterations that occur in the geometry of the remodeled left ventricle may promote progressive failure in LV performance.

Post-MI progressive LV dilatation is associated with adverse cardiovascular events and it continues even after the infarct zone has repaired (27). In acute myocardial infarction, localization and the intensity of the mural involvement (such as anterior transmural infarcts) is associated with adverse remodeling and

worse outcomes (28). Cardiac magnetic resonance (CMR) imaging allows precise quantification of myocardial scar and LV chamber dimensions and function; rendering CMR an ideal tool for assessing the relation between infarct size and LV remodeling after MI (29). The association of fibrosis and LV remodeling was studied previously (24, 34). Fibrosis that is detected by CMR is a frequent feature of left ventricular hypertrophy and it depends on the severity of LV remodeling (30). In a recent study by our group, left ventricle and atrium enlargement is observed when cardiac fibrosis is detected by LGE-CMR in the patients with dilated cardiomyopathy and a link between cardiac fibrosis and adverse LV remodeling is established (31, 32).

Pharmacologic intervention of LV remodeling is an important part of treatment in heart failure. One of these pharmacologic intervention targets renin-angiotensin-aldosterone system (RAAS) that has an important role in the pathophysiology of LV remodeling and HF progression; thus the pharmacologic inhibition of RAAS by angiotensin-converting enzyme inhibitors and angiotensin II type 1 receptor blocker attenuates LV remodeling (33). Aldosterone is also a key component of the RAAS and it has detrimental effects on LV remodeling, including stimulation of myocardial fibrosis (34). In mild to moderate heart failure, a reduction in LV volumes and mass was observed when spironolactone was combined with candesartan therapy (35). Another class of medicine that is used in heart failure is beta-blockers: a recent study showed that carvedilol treatments alleviating effects on LV remodeling caused a reduction in LV end systolic volume and an improvement in LV ejection fraction (EF) (36). New pharmacological approaches such as antioxidants, phosphodiesterase 5A inhibitors, metalloproteinase inhibitors, and cyclic guanylyl cyclase activators can also be used to prevent or reverse LV remodeling (18). In addition, a negative correlation between reverse remodeling of the LV and cardiac resynchronization therapy, an effective treatment for systolic heart failure, was found (37). In spite of availability of different pharmacological and device therapies, LV remodeling remains to be a challenging problem.

Cardiac fibrosis and diastolic function

LV filling and myocyte relaxation displays a complex interplay during diastole, which is influenced by many factors such as loading conditions, systolic emptying, myocardial ischemia, heart rate, and intracellular calcium cycling (38). Although the association of myocardial fibrosis and the molecular mechanism of collagen turnover are not identified yet, it is suggested that excess collagen deposition plays an important role in the development of diastolic dysfunction after myocardial injury (10). In addition, a strong correlation between the degree of diastolic dysfunction and increased collagen turnover markers (such as serum carboxy-terminal telopeptide of procollagen type I, matrix metalloproteinases) was shown (10). Increased type I collagen attenuates myocyte contraction strength, causes stiffness and contributes to systolic and in particular diastolic dysfunction in dilated cardiomyopathy (39). Fibrosis may cause decrease in ventricle compliance and subsequent increase in filling pressures (20). It has been reported that a good correlation exists

between diastolic functions and late gadolinium enhancement rate, suggesting that extend of LV fibrosis reflects LV diastolic function, which occurs earlier than systolic function (40). In another study, conventional and tissue Doppler echocardiography was used to assess the association of fibrosis and diastolic functions in dilated cardiomyopathy, although similar LV systolic functions were monitored, fibrosis was found to be linked with impaired diastolic function (31). These observations support the hypothesis that myocardial fibrosis causes aggravation of diastolic dysfunction. Diastolic dysfunction significantly affects prognosis in chronic heart failure regardless of other contributing factors. In heart failure, the detection of myocardial fibrosis is crucial to assess both the negative influence of fibrosis on prognosis and its aggravating effect on diastolic dysfunction.

Cardiac fibrosis and brain natriuretic peptide

Atrial natriuretic peptide (ANP) and B-type natriuretic peptide (BNP) are predominantly produced in the heart and have vasorelaxant, natriuretic, and antigrowth activities (4). Production and secretion of BNP by ventricular myocytes are increased in case of volume and/or pressure overload. Elevated BNP plasma level is detected in various types of heart disease and is not specific to any of them and usually high plasma levels are associated with severity of ventricular systolic dysfunction (41). Multiple factors influence brain natriuretic peptide secretion in heart failure, some of them are renal dysfunction (particularly with estimated glomerular filtration rates <60 ml/min) (42), age and gender (43).

Diastolic wall stress modulates BNP expression levels (44) consequently higher BNP levels are detected when LV filling pressures are higher. The association of diastolic dysfunction and plasma BNP concentrations was studied in presence and absence of systolic dysfunction (45, 31). In case of isolated diastolic dysfunction with preserved left ventricular systolic function, BNP levels were correlated to functional capacity determined by cardiopulmonary exercise test (45). Paelinck et al. (44) showed that plasma BNP level was correlated with the extent of myocardial damage and estimated LV filling pressures; By receiver-operating character analysis it was revealed that the optimal cut-off values for an early diastolic mitral flow velocity/early diastolic tissue velocity (E/E') ratio < 8 had a positive predictive value of 75% for the prediction of a BNP level <100 pg/ml and a E/E' ratio >15 had a positive predictive value of 86% for the prediction of a BNP level >100 pg/ml (44). Measuring of BNP level is a simple and noninvasive procedure and it is feasible to use in BNP levels in our daily clinical practice to predict diastolic dysfunction.

After myocardial infarction, progressive cardiac remodeling augments synthesis and secretion of brain natriuretic peptide, thus plasma BNP concentration is a powerful predictor of LV dilatation in both short and long term (46). Nelson et al. (47) demonstrated that extent of dysfunctional myocardium (defined as a combination of viable and scarred myocardium) which is determined by CMR, has a moderately positive correlation with BNP levels. In another CMR study, a significant correlation was

found between N-terminal-pro- BNP (NT-pro-BNP) levels and myocardial fibrosis and also NT-pro-BNP level was revealed as an independent predictor of cardiac fibrosis (31). Reciprocal interaction of myocardial fibrosis, LV remodeling and BNP secretion with each other has a complex role in heart failure. This multifaceted relationship rises new therapeutic opportunities to deal with heart failure in today's evidence-based cardiology.

Cardiac fibrosis and prognosis

Myocardial fibrosis, which may be a general or local phenomenon, is coupled with poor prognosis factors in NICM such as progressive remodeling, diastolic dysfunction and arrhythmia (21). In both ischemic and non-ischemic myocardial disease, fibrosis is a stronger predictive marker for poor outcome compared to standard clinical markers, including EF (48). Absence of myocardial fibrosis is associated with ventricular functional recovery in patients with NICM with high sensitivity (90.5%), specificity (79.2%), positive predictive value (80.0%) and negative predictive value (90.9%) (49). In a survival analysis, cardiac fibrosis was found to be the most important independent predictor of mortality/transplantation requirement, especially in patients with LVEF < 30% who already had increased mortality, survival was found to be decreased in the presence of delayed enhancement (50). Wu et al. (21) demonstrated that in NICM with late gadolinium enhancement on CMR, probability to experience adverse cardiac outcomes such as HF hospitalization, implantable cardioverter-defibrillator (ICD) discharge, and cardiac death increased eight fold after adjustment for LV volume index and functional class.

Myocardial fibrosis is a possible source for arrhythmias. In a catheter mapping study, reentry around myocardium scar found to be responsible for monomorphic ventricular tachycardia (VT) in the setting of non-ischemic cardiomyopathy with predominance in left ventricle basal distribution of endocardial electrocardiogram abnormalities (51). In NICM, induction of sustained ventricular tachycardia, which is caused by nonconductive scar associated reentry phenomena, indicates a poor prognosis (25). If the midwall myocardial enhancement involves >25% of wall thickness, the probability of inducible VT in DCM significantly increases and this increase is not affected by LV ejection fraction (25). In dilated cardiomyopathy, evaluation of the presence and degree of myocardial fibrosis is important for choosing a treatment option such as cardiac resynchronization therapy (12), left ventricular assist device (LVAD) therapy (26), and surgical ventricular restoration (52). In heart failure, it is hard to assess the requirement and value of a particular therapeutic intervention just by clinical evaluation because patients may present with a broad range of symptoms even though similar EF is observed, in this case a noninvasive prognostic evaluation like CMR can guide us to select a favorable therapeutic intervention. Echocardiography is widely used to select patients for cardiac resynchronization therapy, however approximately 20%-to-30% of patients were non respondent to the therapy even though a detailed evaluation is done before device placement (53). White et al. (12) demonstrated that presence of delayed enhancement in

magnetic resonance imaging is a better marker of positive clinical response to cardiac resynchronization therapy (cut-off value of 15% total scar provided a sensitivity and specificity of 85% and 90% respectively). The degree of cardiac fibrosis and myocyte size has also been demonstrated as a significant predictor of improvement in cardiac function and the sustained recovery after the LVAD explanation (26). Preoperative quantitative assessment of left ventricular basal scarring remote from surgical exclusion site with delayed-enhancement magnetic resonance imaging can be used for predicting outcomes of surgical ventricular restoration (52). The evaluation of myocardium by a noninvasive technique like CMR may expose hints about response before clinical response is observed and may guide us to select alternative therapeutic approaches in end stage heart failure.

Conclusion and perspectives

Myocardial fibrosis is gradually recognized in multiple etiologies as a pathological entity. The presence of fibrosis is an important contributor for development of heart failure, a predictor of poor prognosis, a cause of diastolic dysfunction and arrhythmias. The detection of myocardial fibrosis with a noninvasive imaging technique is useful for prediction of probable adverse outcomes. Delayed enhancement CMR is widely used to detect myocardial scar and perfusion dynamics. Although routine usage of this imaging technique is limited due to its high cost, it can be extremely beneficial for evaluation of high-risk patients. The detection and evaluation of fibrosis by an imaging technique may support the new therapeutic intervention approaches that target fibrosis in heart failure patients.

Cardiac fibrosis detected by CMR might be useful in selection of candidates for advanced therapies like cardiac resynchronization therapy, stem cell transplantation after myocardial infarction and cardiac transplantation. Severity of cardiac fibrosis might affect the medical management strategies of heart failure patients with preserved systolic function. The detection and evaluation of fibrosis by an imaging technique may support the new therapeutic intervention approaches in these patients. All of the above-mentioned considerations need further research and long-term studies.

Conflict of interest: None declared.

References

1. Herpel E, Pritsch M, Koch A, Dengler TJ, Schirmacher P, Schnabel PA. Interstitial fibrosis in the heart: differences in extracellular matrix proteins and matrix metalloproteinases in end-stage dilated, ischaemic and valvular cardiomyopathy. *Histopathology* 2006; 48: 736-47.
2. Mann DL, Bristow MR. Mechanisms and models in heart failure: the biomechanical model and beyond. *Circulation* 2005; 111: 2837-49.
3. Bishop JE, Greenbaum R, Gibson DG, Yacoub M, Laurent GJ. Enhanced deposition of predominantly type I collagen in myocardial disease. *J Mol Cell Cardiol* 1990; 22: 1157-65.
4. Kapoun AM, Liang F, O'Young G, Damm DL, Quon D, White RT, et al. B-type natriuretic peptide exerts broad functional opposition to transforming growth factor-beta in primary human cardiac fibroblasts: fibrosis, myofibroblast conversion, proliferation, and inflammation. *Circ Res* 2004; 94: 453-61.
5. Mann D. Pathophysiology of heart failure. In: Libby P, Bonow RO, Mann DL, Zipes DP, Braunwald E. *Braunwald's Heart Disease. A Textbook of Cardiovascular Medicine*. 8th ed. Saunders Elsevier; 2008.p.541-60.
6. Reimer KA, Lowe JE, Rasmussen MM, Jennings RB. The wavefront phenomenon of ischemic cell death. 1. Myocardial infarct size vs duration of coronary occlusion in dogs. *Circulation* 1977; 56: 786-94.
7. Jellis C, Martin J, Narula J, Marwick TH. Assessment of nonischemic myocardial fibrosis. *J Am Coll Cardiol* 2010; 56: 89-97.
8. De Leeuw N, Ruiter DJ, Balk AH, de Jonge N, Melchers WJ, Galama JM. Histopathologic findings in explanted heart tissue from patients with end-stage idiopathic dilated cardiomyopathy. *Transpl Int* 2001; 14: 299-306.
9. McCrohon JA, Moon JC, Prasad SK, McKenna WJ, Lorenz CH, Coats AJ, et al. Differentiation of heart failure related to dilated cardiomyopathy and coronary artery disease using gadolinium-enhanced cardiovascular magnetic resonance. *Circulation* 2003; 108: 54-9.
10. Martos R, Baugh J, Ledwidge M, O'Loughlin C, Conlon C, Patle A, et al. Diastolic heart failure: evidence of increased myocardial collagen turnover linked to diastolic dysfunction. *Circulation* 2007; 115: 888-95.
11. Karamitsos TD, Francis JM, Myerson S, Selvanayagam JB, Neubauer S. The role of cardiovascular magnetic resonance imaging in heart failure. *J Am Coll Cardiol* 2009; 54: 1407-24.
12. White JA, Yee R, Yuan X, Krahn A, Skanes A, Parker M, et al. Delayed enhancement magnetic resonance imaging predicts response to cardiac resynchronization therapy in patients with intraventricular dyssynchrony. *J Am Coll Cardiol* 2006; 48: 1953-60.
13. Rehwald WG, Fieno DS, Chen EL, Kim RJ, Judd RM. Myocardial magnetic resonance imaging contrast agent concentrations after reversible and irreversible ischemic injury. *Circulation* 2002; 105: 224-9.
14. Papavassiliu T, Schnabel P, Schröder M, Borggrefe M. CMR scarring in a patient with hypertrophic cardiomyopathy correlates well with histological findings of fibrosis. *Eur Heart J* 2005; 26: 2395.
15. Borchert B, Lawrenz T, Bartelsmeier M, Röthemeyer S, Kuhn H, Stellbrink C. Utility of endomyocardial biopsy guided by delayed enhancement areas on magnetic resonance imaging in the diagnosis of cardiac sarcoidosis. *Clin Res Cardiol* 2007; 96: 759-62.
16. Kim RJ, Wu E, Rafael A, Chen EL, Parker MA, Simonetti O, et al. The use of contrast-enhanced magnetic resonance imaging to identify reversible myocardial dysfunction. *N Engl J Med* 2000; 343: 1445-53.
17. Cummings KW, Bhalla S, Javidan-Nejad C, Bierhals AJ, Gutierrez FR, Woodard PK. A pattern-based approach to assessment of delayed enhancement in nonischemic cardiomyopathy at MR imaging. *Radiographics* 2009; 29: 89-103.
18. Tigen K, Karaahmet T, Kirma C, Dündar C, Pala S, Işıklar I, et al. Diffuse late gadolinium enhancement by cardiovascular magnetic resonance predicts significant intraventricular systolic dyssynchrony in patients with non-ischemic dilated cardiomyopathy. *J Am Soc Echocardiogr* 2010; 23: 416-22.
19. Iles L, Pfluger H, Phrommintikul A, Cherayath J, Aksit P, Gupta SN, et al. Evaluation of diffuse myocardial fibrosis in heart failure with cardiac magnetic resonance contrast-enhanced T1 mapping. *J Am Coll Cardiol* 2008; 52: 1574-80.
20. Assomull RG, Prasad SK, Lyne J, Smith G, Burman ED, Khan M, et al. Cardiovascular magnetic resonance, fibrosis, and prognosis in dilated cardiomyopathy. *J Am Coll Cardiol* 2006; 48: 1977-85.
21. Wu KC, Weiss RG, Thiemann DR, Kitagawa K, Schmidt A, Dalal D, et al. Late gadolinium enhancement by cardiovascular magnetic resonance heralds an adverse prognosis in nonischemic cardiomyopathy. *J Am Coll Cardiol* 2008; 51: 2414-21.

22. Beek AM, Kühl HP, Bondarenko O, Twisk JW, Hofman MB, van Dockum WG, et al. Delayed contrast enhanced magnetic resonance imaging for the prediction of regional functional improvement after acute myocardial infarction. *J Am Coll Cardiol* 2003; 42: 895-901.
23. Kim RJ, Manning WJ. Viability assessment by delayed enhancement cardiovascular magnetic resonance: will low-dose dobutamine dull the shine? *Circulation* 2004; 109: 2476-9.
24. Kwon DH, Halley CM, Carrigan TP, Zysek V, Popovic ZB, Setser R, et al. Extent of left ventricular scar predicts outcomes in ischemic cardiomyopathy patients with significantly reduced systolic function: a delayed hyperenhancement cardiac magnetic resonance study. *JACC Cardiovasc Imaging* 2009; 2: 34-44.
25. Nazarian S, Bluemke DA, Lardo AC, Zviman MM, Watkins SP, Dickfeld TL, et al. Magnetic resonance assessment of the substrate for inducible ventricular tachycardia in nonischemic cardiomyopathy. *Circulation* 2005; 112: 2821-5.
26. Saito S, Matsumiya G, Sakaguchi T, Miyagawa S, Yamauchi T, Kuratani T, et al. Cardiac fibrosis and cellular hypertrophy decrease the degree of reverse remodeling and improvement in cardiac function during left ventricular assist. *J Heart Lung Transplant* 2010; 29: 672-9.
27. St John Sutton M, Pfeffer MA, Moye L, Plappert T, Rouleau JL, Lamas G, et al. Cardiovascular death and left ventricular remodeling two years after myocardial infarction: baseline predictors and impact of long-term use of captopril: information from the Survival and Ventricular Enlargement (SAVE) trial. *Circulation* 1997; 96: 3294-9.
28. Weisman HF, Healy B. Myocardial infarct expansion, infarct extension and reinfarction: pathophysiological concepts. *Prog Cardiovasc Dis* 1987; 30: 73-110.
29. Orm S, Manhenke C, Anand IS, Squire I, Nagel E, Edvardsen T, et al. Effect of left ventricular scar size, location, and transmural extent on left ventricular remodeling with healed myocardial infarction. *Am J Cardiol* 2007; 99: 1109-14.
30. Rudolph A, Abdel-Aty H, Bohl S, Boyé P, Zagrosek A, Dietz R, et al. Noninvasive detection of fibrosis applying contrast-enhanced cardiac magnetic resonance in different forms of left ventricular hypertrophy. *J Am Coll Cardiol* 2009; 53: 284-91.
31. Karaahmet T, Tigen K, Dündar C, Pala S, Güler A, Kılıçgedik A, et al. The effect of cardiac fibrosis on left ventricular remodeling, diastolic function, and N-terminal pro-B-type natriuretic peptide levels in patients with nonischemic dilated cardiomyopathy. *Echocardiography* 2010; 27: 954-60.
32. Karaahmet T, Tigen K, Dündar C, Pala S, Güler A, Kılıçgedik A, et al. The effect of cardiac fibrosis on left ventricular remodeling, diastolic function, and N-terminal pro-B-type natriuretic peptide levels in patients with non-ischemic dilated cardiomyopathy. *Eur Heart J* 2010; Sep31(Suppl 1): P3814. (Abstract)
33. Anavekar NS, Solomon SD. Angiotensin II receptor blockade and ventricular remodeling. *J Renin Angiotensin Aldosterone Syst* 2005; 6: 43-8.
34. Weber KT. Aldosterone in congestive heart failure. *N Engl J Med* 2001; 345: 1689-97.
35. Chan AK, Sanderson JE, Wang T, Lam W, Yip G, Wang M, et al. Aldosterone receptor antagonism induces reverse remodeling when added to angiotensin receptor blockade in chronic heart failure. *J Am Coll Cardiol* 2007; 50: 591-6.
36. Doughty RN, Whalley GA, Walsh HA, Gamble GD, Lopez-Sendon J, Sharpe N, et al. CAPRICORN Echo Substudy Investigators. Effects of carvedilol on left ventricular remodeling after acute myocardial infarction: the CAPRICORN Echo Substudy. *Circulation* 2004; 109: 201-6.
37. Landmesser U, Wollert KC, Drexler H. Potential novel pharmacological therapies for myocardial remodeling. *Cardiovasc Res* 2009; 81: 519-27.
38. Moreo A, Ambrosio G, De Chiara B, Pu M, Tran T, Mauri F, et al. Influence of myocardial fibrosis on left ventricular diastolic function. *Circ Cardiovasc Imaging* 2009; 2: 437-43.
39. Pauschinger M, Knopf D, Petschauer S, Doerner A, Poller W, Schwimmbeck PL, et al. Dilated cardiomyopathy is associated with significant changes in collagen type I/III ratio. *Circulation* 1999; 99: 2750-6.
40. Nanjo S, Yoshikawa K, Harada M, Inoue Y, Namiki A, Nakano H, et al. Correlation between left ventricular diastolic function and ejection fraction in dilated cardiomyopathy using magnetic resonance imaging with late gadolinium enhancement. *Circ J* 2009; 73: 1939-44.
41. Selvais PL, Donckier JE, Robert A, Laloux O, van Linden F, Ahn S, et al. Cardiac natriuretic peptides for diagnosis and risk stratification in heart failure: influences of left ventricular dysfunction and coronary artery disease on cardiac hormonal activation. *Eur J Clin Invest* 1998; 28: 636-42.
42. Tsutamoto T, Wada A, Sakai H, Ishikawa C, Tanaka T, Hayashi M, et al. Relationship between renal function and plasma brain natriuretic peptide in patients with heart failure. *J Am Coll Cardiol* 2006; 47: 582-6.
43. Redfield MM, Rodeheffer RJ, Jacobsen SJ, Mahoney DW, Bailey KR, Burnett JC Jr. Plasma brain natriuretic peptide concentration: impact of age and gender. *J Am Coll Cardiol* 2002; 40: 976-82.
44. Paelinck BP, Vrints CJ, Bax JJ, Bosmans JM, De Hert SG, de Roos A, et al. Relation of B-type natriuretic peptide early after acute myocardial infarction to left ventricular diastolic function and extent of myocardial damage determined by magnetic resonance imaging. *Am J Cardiol* 2006; 97: 1146-50.
45. Eroğlu S, Yıldırım A, Bozbaş H, Aydınalp A, Ulubay G, Eldem O, et al. Brain natriuretic peptide levels and cardiac functional capacity in patients with dyspnea and isolated diastolic dysfunction. *Int Heart J* 2007; 48: 97-106.
46. Hirayama A, Kusuoka H, Yamamoto H, Sakata Y, Asakura M, Higuchi Y, et al. Serial changes in plasma brain natriuretic peptide concentration at the infarct and non-infarct sites in patients with left ventricular remodeling after myocardial infarction. *Heart* 2005; 91: 1573-7.
47. Nelson CA, Case C, McCrohon J, Marwick TH. Relationship of extent and nature of dysfunctional myocardium to brain natriuretic peptide in patients with ischemic left ventricular dysfunction. *Int J Cardiovasc Imaging* 2005; 21: 295-300.
48. Kramer CM. The expanding prognostic role of late gadolinium enhanced cardiac magnetic resonance. *J Am Coll Cardiol* 2006; 48: 1986-7.
49. Park S, Choi BW, Rim SJ, Shim CY, Ko YG, Kang SM, et al. Delayed hyperenhancement magnetic resonance imaging is useful in predicting functional recovery of nonischemic left ventricular systolic dysfunction. *J Card Fail* 2006; 12: 93-9.
50. Cheong BY, Muthupillai R, Wilson JM, Sung A, Huber S, Amin S, et al. Prognostic significance of delayed-enhancement magnetic resonance imaging survival of 857 patients with and without left ventricular dysfunction. *Circulation* 2009; 120: 2069-76.
51. Hsia HH, Callans DJ, Marchlinski FE. Characterization of endocardial electrophysiological substrate in patients with nonischemic cardiomyopathy and monomorphic ventricular tachycardia. *Circulation* 2003; 108: 704-10.
52. Takeda K, Matsumiya G, Matsue H, Hamada S, Sakaki M, Sakaguchi T, et al. Use of quantitative analysis of remote myocardial fibrosis with delayed-enhancement magnetic resonance imaging to predict outcomes after surgical ventricular restoration for ischemic cardiomyopathy. *J Thorac Cardiovasc Surg* 2008; 136: 1514-21.
53. Bax JJ, Abraham T, Barold SS, Breithardt OA, Fung JW, Garrigue S, et al. Cardiac resynchronization therapy: part 1-issues before device implantation. *J Am Coll Cardiol* 2005; 46: 2153-67.