

## Acute myocardial infarction and ischemic stroke coexistence due to marijuana abuse in an adolescent 🎬

Muhammed Keskin, Mert İlker Hayiroğlu, Ümran Keskin<sup>1</sup>, Mehmet Eren  
 Department of Cardiology, Siyami Ersek Thoracic and Cardiovascular  
 Surgery Center, Training and Research Hospital; Istanbul-Turkey  
<sup>1</sup>Department of Internal Medicine, Ümraniye Training and Research  
 Hospital; Istanbul-Turkey

### Introduction

Bonzai, a synthetic derivative of cannabis, is increasingly being used by young adults, and even adolescents, on account of the fact that it is cheap and easily accessible. We present the case of a young patient with acute myocardial infarction (AMI) and acute ischemic stroke related to bonzai.

### Case Report

A 15-year-old teenager presented with complaint of chest pain for 3 h. He had been a heavy bonzai smoker for 2.5 years, and approximately 2 h passed after this last smoke. His blood pressure and heart rate were 84/47 mm Hg and 104 bpm, respectively. Electrocardiography (ECG) revealed right bundle-branch block and ST-segment elevation in leads DI, II, III, aVL, aVF, and V4-6 (Fig. 1a). Transthoracic echocardiography (TTE) revealed moderate mitral regurgitation, +2 spontaneous echo contrast (SEC) in left chambers, and left ventricular (LV) inferior and posterolateral wall hypokinesia with an ejection fraction (EF) of 40% (Video 1–3). Aspirin, 300 mg and clopidogrel, 600 mg were administered with the diagnosis of ST-elevation myocardial infarction, and the patient was referred to the catheterization laboratory. Coronary angiography (CAG) revealed normal coronary arteries (Fig. 2a–d). Troponin I levels were 6.4 ng/mL (0–0.028 ng/mL), and the other biochemical findings were unremarkable. Considering coronary vasospasm, we initiated diltiazem therapy. After 2 h of initiation, the patient complained of right-sided blurred vision. Initial cranial multidetector computed tomography findings (MDCT) were normal (Fig. 3a). A control MDCT showed acute occipital lobe infarction (Fig. 3b). Because of +2 SEC in the left chambers, we presumed cardio-embolism to be the main reason for the stroke. After 7 days of low-molecular-weight heparin and warfarin therapy, the patient's visual impairment was alleviated. He was discharged on the 10<sup>th</sup> day and called for a control visit after 1 month. At the control visit, ECG revealed inverted T waves in leads DI, II, aVL, and V4-6 (Fig. 1b). TTE revealed mild mitral regurgitation and normal LV wall motion (Video 3, 4). Cardiac magnetic resonance imaging (MRI) was performed for confirmation, and it revealed late myocardial gadolinium enhancement in the posterolateral portion of the heart (Fig. 4a, b; Video 5).

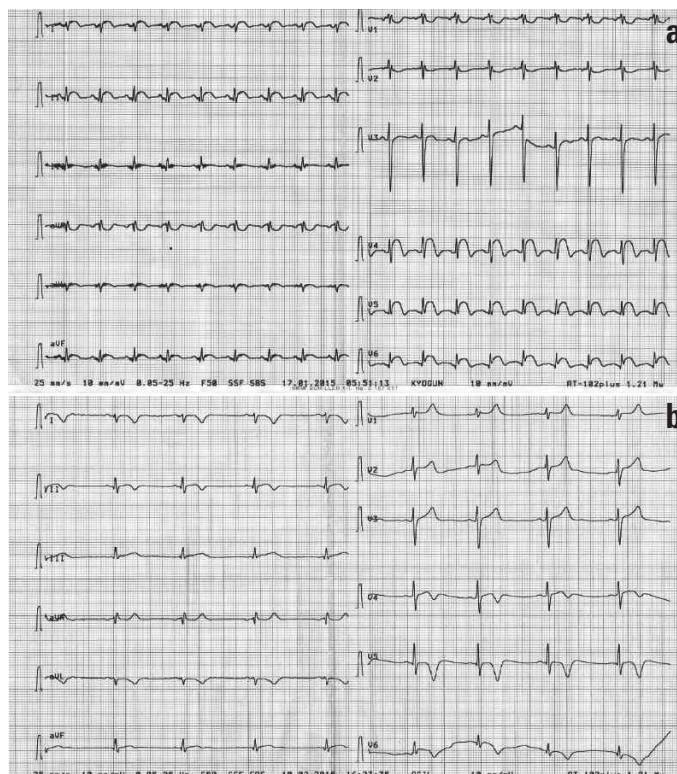


Figure 1. (a) ECG showing RBBB and ST segment elevation in leads DI, II, III, aVL, aVF, and V4-6; (b) Control ECG showing inverted T waves in leads DI, II, aVL, and V4-6 without RBBB

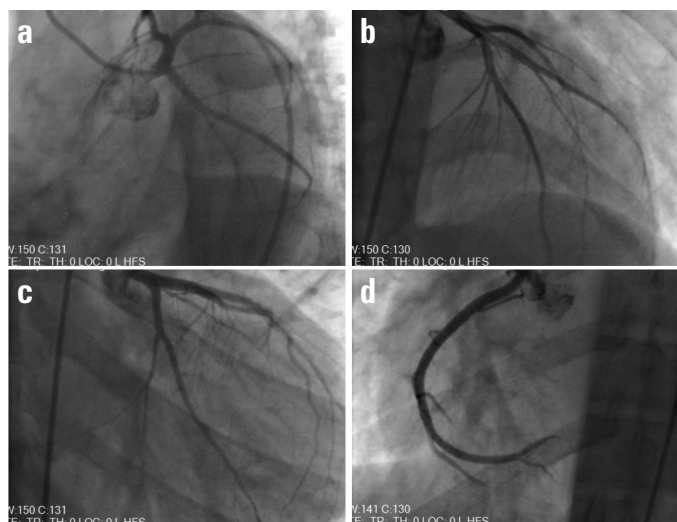
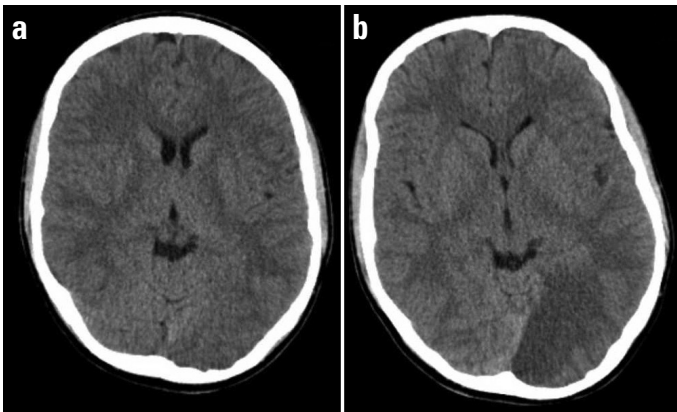


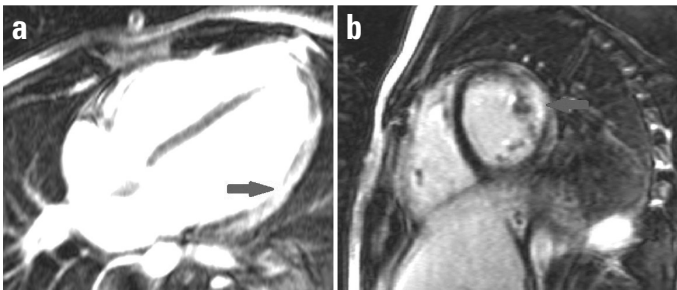
Figure 2. (a–d) CAG showing normal coronary arteries

### Discussion

Marijuana is a rare trigger for AMI. The risk of AMI onset increases by almost 5-fold 1 h after smoking marijuana and persists afterwards (1). Marijuana intoxication usually causes an increase in the sympathetic activity and a decrease in the parasympathetic activity, resulting in tachycardia and increased cardiac output,



**Figure 3. (a, b) Initial and control cranial MDCT**



**Figure 4. (a, b) Cardiac MRIs showing late gadolinium enhancement (LGE) in posterolateral portion of the heart (arrows), which is consistent with an old myocardial infarction**

with little or no increase in blood pressure (2). There are different reports on the type of AMI associated with marijuana, including atherosclerotic coronary artery disease, coronary artery thrombosis, and coronary vasospasm (3, 4). Considering vasospasm, the present patient was administered diltiazem during hospitalization. Usually, cardiovascular and cerebrovascular ischemic mechanisms associated with marijuana are similar. Intense postural hypotension, cardio-embolism, vasospasm, and increased catecholamines and carboxyhemoglobin levels might be the responsible mechanisms. Paroxysmal atrial fibrillation (PAF) is accepted as the main reason for cardio-embolism (5–7). Albeit the sinus rhythm observed in the patient's admission ECG, SEC in the left chambers suggested a history of PAF. Resolution of symptoms with anticoagulants and disappearance of SEC indicates cardio-embolism as the responsible mechanism. Furthermore, in children and adolescents, following marijuana consumption, posterior cerebrovascular circulations have been reported as the regions of predilection (8). Our patient's stroke-related area was the left occipital lobe, which confirms the predilection.

## Conclusion

Marijuana is a novel illicit drug used worldwide. There have been some reports about the side effects of marijuana on the cardiovascular and cerebrovascular systems. To the best of our knowledge and according to the literature, our patient was the youngest to present with stroke and myocardial infarction.

**Video 1.** TTE showing inferior and posterolateral wall hypokinesis with an EF of 40%.

**Video 2.** TTE showing +2 SEC in left chambers.

**Video 3.** TTE showing moderate mitral regurgitation.

**Video 4.** Control TTE showing normal left ventricular wall motion.

**Video 5.** Control TTE showing mild mitral regurgitation.

**Video 6.** Cardiac MRI showing mild posterolateral hypokinesia.

## References

1. Leggett T. United Nations Office on Drugs and Crime. A review of the world cannabis situation. *Bull Narc* 2006; 58:1-155.
2. Ghuran A, Nolan J. Recreational drug misuse: issues for the cardiologist. *Heart* 2000; 83: 627-33. [Crossref]
3. Velibey Y, Şahin S, Tank O, Keskin M, Bolca O, Eren M. Acute myocardial infarction due to marijuana smoking in a young man: guilty should not be underestimated. *Am J Emerg Med* 2015; 3: 1114.
4. Yurtdaş M, Aydın MK. Acute myocardial infarction in a young man; fatal blow of the marijuana: A case report. *Korean Circ J* 2012; 42: 641-5. [Crossref]
5. Basnet S, Mander G, Nicolas R. Coronary vasospasm in an adolescent resulting from marijuana use. *Pediatr Cardiol* 2009; 30: 543-5.
6. Zachariah SB. Stroke after heavy marijuana smoking. *Stroke* 1991; 22: 406-9. [Crossref]
7. Barnes D, Palace J, O'Brien MD. Stroke following marijuana smoking. *Stroke* 1992; 23: 1381. [Crossref]
8. Geller T, Loftis L, Brink DS. Cerebellar infarction in adolescent males associated with acute marijuana use. *Pediatrics* 2004; 113: 365-70.

**Address for Correspondence:** Dr. Muhammed Keskin

Dr. Siyami Ersek Hastanesi,

Tıbbiye Cad. No: 25, Üsküdar/İstanbul-Türkiye

Phone: +90 224 295 16 40 Fax: +90 224 295 16 28

E-mail: drmuhammedkeskin@gmail.com

©Copyright 2016 by Turkish Society of Cardiology - Available online

at [www.anatoljcardiol.com](http://www.anatoljcardiol.com)

DOI:10.14744/AnatolJCardiol.2016.6978



## Severe hypocalcemia and hypercalciuria due to contrast medium in the course of acute myocardial infarction

**Ali Çoner, Gültekin Gençtoy\*, Serhat Balcıoğlu, Haldun Müderrisoğlu**  
Departments of Cardiology, \*Nephrology, Başkent University Hospital, Ankara\*, Antalya-Turkey

### Introduction

Contrast media-related nephropathy is one of the possible complications in myocardial infarction patients following primary percutaneous intervention (PCI). Contrast media-related nephropathy is mainly defined as a decrease in creatinine clearance and an increase in serum creatinine levels; however, contrast media may also cause electrolyte imbalances. Here we present a case report of severe electrolyte deficiency related with contrast media administration.