

## Electrification Technique of a Guidewire to Assist in Crossing Iliac Occlusion

### INTRODUCTION

Endovascular treatment of Trans-Atlantic Inter-Society Consensus C and D aortoiliac lesions is complex, and the success rate is lower than that of TASC A and B lesions. Recanalization success rate can be increased by using re-entry devices.<sup>1,2</sup> Although commonly adopted techniques were used to cross chronic total occlusion (CTO) lesions, electrical energy-facilitated crossing of coronary CTO has recently been reported, when common techniques fail.<sup>3</sup> The use of electrical energy has become a growing area of interest for other interventions of vascular areas, such as BASILICA procedure, LAMPOON procedure, and interatrial septum crossing.<sup>4-6</sup> Innovative technologies to improve operational success are continually identified by endovascular operators through hybrid algorithms and modern facilities. Although many devices are available, there is no information on the use of electrocautery for crossing peripheral CTO.

In this case report, we describe a novel use of delivering electrical energy through a guidewire supported with catheter to facilitate crossing of iliac CTO when stiff hydrophilic guidewires failed to cross the cap of occlusion.

### CASE REPORT

A 68-year-old male presented with bilateral claudication of lower extremities, classified as Rutherford stage 4. Ankle-brachial index (ABI) was measured as 0.40. Lower extremity Doppler ultrasonography showed diminished distal blood flow in both lower extremities from the superficial femoral artery to the popliteal artery. The patient's having Rutherford class 4 symptoms determined the need for intervention. Computed tomographic angiography revealed critical aortoiliac total occlusion. After consulting with vascular surgeons regarding the patient's comorbidities (chronic lung disease, diabetes, and previous myocardial infarction), the patient was considered at high risk for perioperative morbidity and mortality, and the case was decided not suitable for aortofemoral bypass surgery. Considering ameliorating symptoms, percutaneous intervention was planned. Informed consent was taken from the patient before the procedure.

The procedure began with placing 7-French (Fr) introducer sheaths into ipsilateral and contralateral common femoral arteries; in addition, a 6-Fr introducer sheath was placed into the left brachial artery, and heparin was administered intravenously at a dose of 7500 IU. Diagnostic angiography revealed heavily calcified bilateral aortoiliac occlusion extending to femoral arteries and the appearance of severe calcific aorta (Figure 1a, Video 1). The patient was sedated with midazolam and fentanyl. Antegrade penetration of lesion was attempted via brachial route but failed crossing to the iliac true lumen. Retrograde approach via 0.035" Glidewire (Terumo Medical Corporation, Somerset, NJ, USA) was successful for crossing the right iliac lesion. As for the left iliac lesion, multiple attempts to cross the lesion both ante- and retrogradely were made using 0.035" Glidewire (Terumo Medical Corporation), 0.014" guidewire Gladius, Astato XS20, Astato XS40 (Asahi Intecc Co, Aichi, Japan), and 0.014" guidewire Treasure 12 (Asahi Intecc). The first attempt was a controlled antegrade and retrograde subintimal tracking technique; however; this attempt failed because of bulky calcification. As a result, we decided

### CASE REPORT



Fatih Yılmaz <sup>ID</sup><sup>1</sup>

Barkın Kültürsay <sup>ID</sup><sup>1</sup>

Berhan Keskin <sup>ID</sup><sup>1</sup>

Süleyman Çağan Efe <sup>ID</sup><sup>1</sup>

Enver Yücel <sup>ID</sup><sup>2</sup>

Ali Karagöz <sup>ID</sup><sup>1</sup>

Cihangir Kaymaz <sup>ID</sup><sup>1</sup>

<sup>1</sup>Department of Cardiology, Kartal Koşuyolu Training and Research Hospital, İstanbul, Turkey

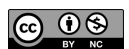<sup>2</sup>Department of Cardiology, Sancaktepe Şehit Prof. Dr. İlhan Varank Training and Research Hospital, İstanbul, Turkey

#### Corresponding author:

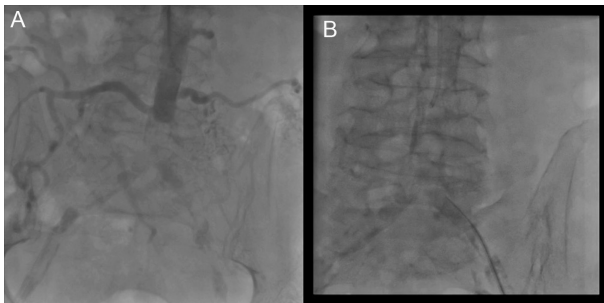Barkın Kültürsay  
✉ bkultursay@gmail.com

**Cite this article as:** Yılmaz F, Kültürsay B, Keskin B, et al. Electrification technique of a guidewire to assist in crossing iliac occlusion. *Anatol J Cardiol.* 2022;26(8):662-664.

DOI:10.5152/AnatolJCardiol.2022.1477

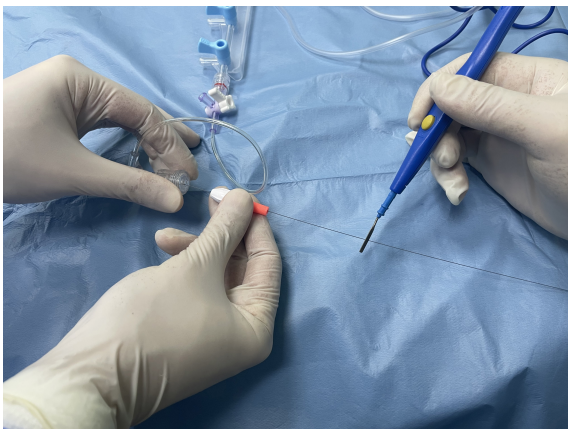

Copyright@Author(s) - Available online at anatoljcardiol.com.  
Content of this journal is licensed under a Creative Commons Attribution-NonCommercial 4.0 International License.



**Figure 1. (A) Diagnostic angiography revealing heavily calcified bilateral aortoiliac occlusion extending to femoral arteries. (B) Distal tip of guidewire penetrating to the lesion using 4-Fr catheter and crossing the lesion using electrocautery assistance.**

to attempt electrocautery-assisted crossing of the lesion. A 0.014" guidewire Astato XS40 (Asahi Intecc) advanced to the lesion in 4 Fr Judkins right (JR) catheter. The 4F JR catheter was kept to the level of the occlusion to protect the iliac artery distal to the occlusion, distal tip of Astato XS40 guidewire was penetrated to the lesion, and proximal tip of guidewire was connected to a unipolar electrocautery pencil using forceps. After making sure that it was intraluminal using 2 different angiographic angles, electrocautery with cutting mode was applied, guidewire was energized at 50 W for 3 seconds, and crossed the calcified lesion intraluminally (Figures 1b, 2, Video 2) after second attempt. After dilatation with 3.0 × 20 mm coronary balloon, the 4-Fr catheter crossed the lesion and 0.014" guidewire exchanged with a 0.035" guidewire. Aortoiliac lesion was dilated using 6.0 × 60 mm and 7.0 × 80 mm balloons (Figure 3a, Video 3). Bilateral aortoiliac 8 × 59 mm stent graft Advanta V12 (Atrium Europe B.V, Mijdrecht, the Netherlands) was implanted using kissing stent technique. Then 8 × 59 mm stent graft and 8 × 59 mm balloon-expandable stent were implanted to right and left iliac arteries, respectively (Figure 3b, Video 4). Procedure was done without complication. Patient was started on aspirin and clopidogrel.



**Figure 2. Demonstration of electrocautery setup in the catheter laboratory. Tip of guidewire is connected to a unipolar electrocautery pencil.**

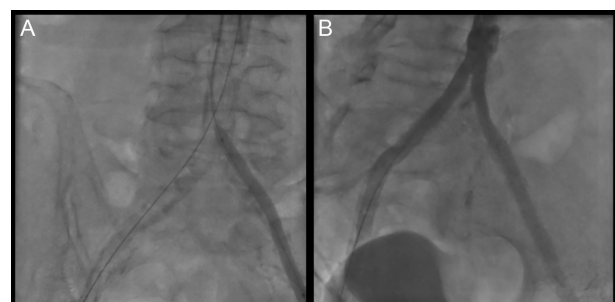
The procedure was performed in a single-plane angiography suite with Siemens Axiom Artis (Siemens, Erlangen, Germany) by an interventionalist who has performed yearly more than 200 cases of TASC C and D lesions. The procedure duration was 188 minutes. The patient's follow-up was uneventful. The ankle-brachial index was measured as 0.73 post-procedure. The patient was able to walk 500 m without claudication in the first month's visit.

## DISCUSSION

This case describes the technical success and effectiveness of electrocautery-assisted true lumen puncture and crossing of CTO iliac artery with bulky calcification. The preferred method of treatment remains to be surgery for TASC C and D aortoiliac lesions. However, percutaneous treatment has been preferred instead of surgery for patients with many comorbidities, and high surgical risk.<sup>7</sup>

The electrical energy-facilitated crossing has been a growing area of interest, such as the BASILICA trial with 30 subjects and high-risk coronary obstruction; electrified guidewires were used to lacerate the leaflet to prevent coronary obstruction.<sup>4</sup> Besides, the LAMPOON procedure, which aims in reducing left ventricular outflow tract obstruction in transcatheter mitral valve replacement, is a technique similar to BASILICA; a wire was electrified through the catheter to split open the leaflet. In these trials, there were no technique-related adverse events found.<sup>5</sup> Moreover, electrocautery was used for interatrial septum crossing when conventional techniques fail.<sup>6</sup> Further, the energized stiff guidewire is used to cross the inferior vena cava and the aortic wall to establish trans-caval access in transcatheter aortic valve implantation.<sup>8</sup> Similar to these techniques, we used a stiff wire (Astato XS, Asahi Intecc) with a short pulse of energy.

Crossing of the iliac lesions is achieved in a subintimal or intraluminal manner depending upon the characteristics and area of the lesion. The length and diameter of the lesion are judged by an intraoperative angiogram. In a study demonstrating long-term outcomes of percutaneous treatment of complex iliac occlusive disease, primary patency rates for primary stenting at 10 years were acceptable even if compared with the outcomes of bypass surgery. Cox multivariable analysis indicated lesion length as an independent risk factor for restenosis.<sup>9</sup> As for the procedural success, failure rate with the use of percutaneous technique varies<sup>10</sup>; but



**Figure 3. (A) Dilating iliac lesion using 7.0 × 80 mm balloon. (B) Final imaging after implantation of aortoiliac stentgrafts.**

generally, rates are at least 20%. Therefore, assessment of the patient's general condition and anatomy of the diseased segment(s) become central in deciding which approach is warranted.<sup>11</sup> Percutaneous intervention of TASC C and D aortoiliac disease remains a technical challenge, even by experienced operators. Due to the high cost and limited availability of newly developed re-entry devices, recanalization can still be difficult to achieve.

Our electrification technique has also been performed in coronary lesions by Neupane et al<sup>3</sup>. They used electrocautery assistance in 6 cases of coronary CTO, only 1 of those cases was complicated, in which the microcatheter melted after electrocautery applied, thereafter, the lesion was crossed with another microcatheter and guidewire. In addition, regarding possible complications in this technique, when the distal cap is crossed using electrocautery assistance, the guidewire should carefully and slowly be advanced after it is evaluated whether it is in the true lumen. Potential complications include thermal injury (particularly in coagulation mode), catheter and equipment damage and melting, and vascular perforation. Further, applying electrical energy could be painful to patient; therefore, peri-procedural sedation must be considered. To our knowledge, this is the first case of an electrification technique used for peripheral CTO when other techniques fail crossing the lesion.

## CONCLUSION

Percutaneous treatment of TASC C and D aortoiliac chronic total occlusions is still a challenge. Recanalization success rate remains low in complex lesions. Percutaneous electrocautery-assisted crossing technique might be an effective method to cross the lesion when common techniques fail to succeed.

**Informed Consent:** Informed consent for publication of the case report and accompanying data has been obtained from the patient.

**Acknowledgments:** We thank Zübeyde Bayram, MD for her contributions.

**Video 1:** Diagnostic angiography revealing heavily calcified bilateral aortoiliac occlusion extending to femoral arteries.

**Video 2:** A 0.018" guidewire advanced to the lesion in 4-Fr Judkins right (JR) catheter. Distal tip of guidewire was penetrated to the lesion and proximal tip of guidewire was connected to a unipolar electrocautery pencil using forceps. The lesion was crossed with electrocautery assistance.

**Video 3:** Dilating iliac lesion using 7.0 × 80 mm balloon.

**Video 4:** Final imaging after implantation of aortoiliac stentgrafts.

## REFERENCES

1. Bolia A, Miles KA, Brennan J, Bell PR. Percutaneous transluminal angioplasty of occlusions of the femoral and popliteal arteries by subintimal dissection. *Cardiovasc Intervent Radiol*. 1990;13(6):357-363. [\[CrossRef\]](#)
2. Kokkinidis DG, Katsaros I, Jonnalagadda AK, et al. Use, safety and effectiveness of subintimal angioplasty and re-entry devices for the treatment of iliac artery chronic total occlusions: a systematic review of 30 studies and 1112 lesions. *Cardiovasc Revasc Med*. 2020;21(3):334-341. [\[CrossRef\]](#)
3. Neupane S, Basir M, Alaswad K. Electrocautery-facilitated crossing (ECFC) of chronic total occlusions. *J Invasive Cardiol*. 2020;32(2):55-57.
4. Khan JM, Greenbaum AB, Babaliaros VC, et al. The BASILICA trial: prospective multicenter investigation of intentional leaflet laceration to prevent TAVR coronary obstruction. *JACC Cardiovasc Interv*. 2019;12(13):1240-1252. [\[CrossRef\]](#)
5. Khan JM, Babaliaros VC, Greenbaum AB, et al. Anterior leaflet laceration to prevent ventricular outflow tract obstruction during transcatheter mitral valve replacement. *J Am Coll Cardiol*. 2019;73(20):2521-2534. [\[CrossRef\]](#)
6. Simard T, El Sabbagh A, Lane C, et al. Anatomic approach to transeptal puncture for structural heart interventions. *JACC Cardiovasc Interv*. 2021;14(14):1509-1522. [\[CrossRef\]](#)
7. Aboyans V, Ricco JB, Bartelink MEL, et al. ESC guidelines on the diagnosis and treatment of peripheral arterial diseases, in collaboration with the European Society for Vascular Surgery (ESVS): document covering atherosclerotic disease of extra cranial carotid and vertebral, mesenteric, renal, upper and lower extremity arteries Endorsed by: the European Stroke Organization (ESO) The Task Force for the Diagnosis and Treatment of Peripheral Arterial Diseases of the European Society of Cardiology (ESC) and of the European Society for Vascular Surgery (ESVS). *Eur Heart J* 2018;39(9):763-816. [\[CrossRef\]](#)
8. Vuruşkan E, Kaplan M, Altunbaş G, Düzen İV, Yılmaz Coşkun F, Sucu MM. Transcaval transcatheter aortic valve replacement through abdominal aortic aneurysm in a patient with no option for other vascular access. *Anatol J Cardiol*. 2021;25(6):456-457. [\[CrossRef\]](#)
9. Ichihashi S, Higashiura W, Itoh H, Sakaguchi S, Nishimine K, Kichikawa K. Long-term outcomes for systematic primary stent placement in complex iliac artery occlusive disease classified according to trans-Atlantic Inter-Society Consensus (TASC)-II. *J Vasc Surg*. 2011;53(4):992-999. [\[CrossRef\]](#)
10. Scheinert D, Bräunlich S, Scheinert S, Ulrich M, Biamino G, Schmidt A. Initial clinical experience with an IVUS-guided transmembrane puncture device to facilitate recanalization of total femoral artery occlusions. *EuroIntervention*. 2005;1(1):115-119.
11. Norgren L, Hiatt WR, Dormandy JA, et al. Inter-society consensus for the management of peripheral arterial disease (TASC II). *J Vasc Surg*. 2007;45(suppl S):S5-S67. [\[CrossRef\]](#)