

Accuracy of Global Longitudinal and Territorial Longitudinal Strain in Determining Myocardial Viability in Comparison to Single-Photon Emission Computed Tomography in Out of Window Period Anterior Wall Myocardial Infarction Patients

ORIGINAL INVESTIGATION

ABSTRACT

Background: To determine the accuracy of global longitudinal strain and territorial longitudinal strain in determining myocardial viability in comparison to single-photon emission computed tomography in out of window period anterior wall myocardial infarction patients.

Methods: This was a single-center, prospective study carried out in a tertiary care center in northern India. All patients presenting with anterior wall myocardial infarction—out of window period without ongoing chest pain and akinetic left-anterior descending territory on echocardiography were recruited. All patients underwent strain echocardiography and the determination of both global longitudinal strain and territorial longitudinal strain within 12–48 hours of anterior wall myocardial infarction. In addition, all underwent single-photon emission computed tomography to determine the viability status of the anterior myocardium.

Results: Fifty-one patients of anterior wall myocardial infarction—out of window period were enrolled and underwent strain imaging with speckle tracking and single-photon emission computed tomography for viability determination. Global longitudinal strain and territorial longitudinal strain were significantly reduced in patients with nonviable myocardium ($P < .001$). On receiver-operating curves, a global longitudinal strain of $<10.45\%$ had a sensitivity of 77.8% and specificity of 93.9% ($AUC = 0.889$) in predicting nonviability on single-photon emission computed tomography. Similarly, a territorial longitudinal strain of $<7.60\%$ had a sensitivity of 77.8% and specificity of 84.8% ($AUC = 0.825$) in predicting nonviability.

Conclusions: Treatment strategies in patients presenting with anterior wall myocardial infarction, outside the window period is largely guided by the hemodynamic status and influenced by the viability status of the myocardium. Strain echocardiography using speckle tracking provides global longitudinal strain and territorial longitudinal strain, both of which have good sensitivity and specificity in predicting viability and can be performed safely and quickly in high-risk group of patients.

Keywords: Strain echocardiography, global longitudinal strain, territorial longitudinal strain, anterior wall myocardial infarction, myocardial viability

INTRODUCTION

ST-elevation anterior wall myocardial infarction (AWMI) accounts for 33% of all ST-elevation myocardial infarction (STEMI) and is associated with increased morbidity and mortality.¹ Prognosis is worse compared to inferior or posterior wall infarction and there is increased risk of left ventricular failure, malignant ventricular arrhythmias, and death.² Immediate revascularization and restoration of coronary blood flow remains essential for successful outcomes. However, a large proportion of patients, especially in the Indian scenario present late in course, are outside the window period.³ Finding of an akinetic left anterior descending

Yash Paul Sharma ¹
Akash Batta ²
Navjot Kaur ¹
Juniali Hatwal ³
Kunaal Makkar ¹
Prashant Panda ¹

¹Department of Cardiology, Advanced Cardiac Centre, Post Graduate Institute of Medical Education & Research, Chandigarh, India

²Department of Cardiology, Dayanand Medical College and Hospital, Ludhiana, India

³Department of Internal Medicine, Advanced Cardiac Centre, Post Graduate Institute of Medical Education & Research, Chandigarh, India

Corresponding author:

Akash Batta
✉ akashbatta02@gmail.com

Received: December 13, 2021

Accepted: March 15, 2022

Available Online Date: May 11, 2022

Cite this article as: Sharma YP, Batta A, Kaur N, Hatwal J, Makkar K, Panda P. Accuracy of global longitudinal and territorial longitudinal strain in determining myocardial viability in comparison to single-photon emission computed tomography in out of window period anterior wall myocardial infarction patients. *Anatol J Cardiol.* 2022;26(8):637–644.



Copyright©Author(s) - Available online at anatoljcardiol.com.
Content of this journal is licensed under a Creative Commons Attribution-NonCommercial 4.0 International License.

DOI:10.5152/AnatolJCardiol.2022.1457

(LAD) artery is common in these patients and in the absence of ongoing chest pain, the revascularization strategy is primarily guided by the viability status. Timely recognition of the viability status has clinical implications as only the viable segments show functional recovery and correlate with improved long-term outcomes.⁴

METHODS

This was a single-center, prospective, observational study carried out in a tertiary care center in Northern India. All patients presenting with AWMi-OWP (>12 hours after the onset of chest pain) without ongoing chest pain and akinetic LAD territory on echocardiography from December 2020 to September 2021 were recruited. All patients underwent strain echocardiography and determination of both global longitudinal strain (GLS) and territorial longitudinal strain (TLS) within 12-48 hours of AWMi was done. In addition, all underwent single-photon emission computed tomography (SPECT) to determine the viability status of the anterior myocardium within 24 hours of strain echocardiography. On SPECT, a defect >5% myocardial territory showing severe reperfusion defect was considered as a marker of nonviability.

2D-Speckle Tracking Echocardiography

Strain imaging was performed, analyzed, and reported as per standardized recommendations⁵ on Philips EPIC 7C (Philips Healthcare; Best, The Netherlands) echocardiography machine. Longitudinal strain imaging by 2D-speckle tracking echocardiography was done with high-quality ECG-gated images from the apical four-, two-, and three-chamber views. The gain settings were optimized. The depth was reduced so that the left ventricle occupied most of the image sector. Care was taken to avoid foreshortening of the LV, the gray-scale frame rate was kept between 50 and 90 frames/s; minimum 3 cardiac cycles were obtained for each loop. All the images were obtained in breath-hold to avoid any breathing artifacts. The endocardial border of the left ventricle was traced manually throughout in the end-systolic frames in all the 3 apical views. The software subsequently generated a region-of-interest (ROI) to include the entire myocardial thickness. Care was taken to avoid the bright echogenic pericardium in the ROI. The software then tracked the myocardial speckles frame-by-frame and generated

moving images displaying the tracking. Adequacy of the tracking was determined by visually inspecting the moving image. When it was found to be inaccurate, the operator returned and readjusted the ROI accordingly. The strain values for all the segments were recorded and averaged which yielded the GLS and also generated the bull's eye display of the regional and global strains.

The territorial longitudinal strain of the LAD territory was calculated based on the segment model proposed by the American Heart Association.⁶ Basal and mid-anterior wall, anteroseptal segments along with apical anterior, and septal segments were taken to be supplied by the LAD. The mean of all the 6 segments was taken as the TLS of the LAD territory. In addition, layer-specific strains were performed for better characterization of ischemic myocardium and endocardial, mid-myocardial, and epicardial longitudinal strains were determined.

SPECT

All SPECT studies were performed with 24 hours of the strain echocardiography. SPECT myocardial perfusion scintigraphy was performed after intravenous injection of 10 mCi of Tc-99m MIBI in the resting condition, 5 minutes after sublingual administration of 5 mg of nitrate. Imaging was performed in dedicated CZT cardiac gamma camera. Reconstruction of SPECT images was done and interpreted. Severely reduced resting myocardial perfusion (matched defects) of >5% in the LAD territory segments was taken as a marker of nonviable myocardium.

Inclusion Criteria

1. ST-elevation AWMi patients presenting OWP (>12 hours).
2. Akinetic LAD territory on echocardiography.
3. Absence of ongoing chest pain.
4. Both strain echocardiography and SPECT performed during hospital admission.

Exclusion Criteria

1. Presentation within window period (<12 hours).
2. Ongoing chest pain.
3. Candidate for immediate percutaneous revascularization as per physician's discretion.
4. Either of strain echocardiography or SPECT could not be performed.
5. Poor echocardiography window limiting accurate strain echocardiography.
6. Patients unwilling to give consent.

The study aimed at determining the accuracy of strain echocardiographic parameters compared to SPECT in predicting myocardial viability in patients of AWMi presenting OWP, having an akinetic LAD territory on echocardiogram.

Ethical Justification

The study protocol conformed to the ethical guidelines of the declaration of Helsinki and is in line with guideline-directed management of OWP AWMi patients. The strain echocardiography software was preinstalled in the Philips EPIC 7C echocardiography machine, and all strain echocardiographs were performed at no additional cost to the patients. All

HIGHLIGHTS

- Timely recognition of the viability status has clinical implications in myocardial infarction patients.
- Strain echocardiography is safe and easy to perform in the sickest of patients.
- Endocardial global longitudinal strain of <10.45% had a sensitivity of 77.8% and specificity of 93.9% (AUROC = 0.889) in predicting nonviability.
- Endocardial territorial longitudinal strain of <7.60% had a sensitivity of 77.8% and specificity of 84.8% (AUROC = 0.825) in predicting nonviability.

patients received guideline-directed treatment⁷ and there was no deviation from usual standard of care.

Statistical Analysis

Statistical analysis was performed with Statistical Package for the Social Sciences version 26 (SPSS Inc., Chicago, Ill, USA). Variables are presented as mean \pm SD or median (IQR). Variable was checked for outliers and normalcy (Shapiro-Wilk test). Differences between mean were analyzed using an independent paired *t*-test. Comparison between categorical variables was done using Chi-square test or Fisher exact test. Receiver operating curve (ROC) analysis was done to find out the appropriate cutoff. A two-sided *P*-value $< .05$ was considered to be significant for all variables. Intra- and inter-observer reproducibility was performed on 20 randomly selected studies by repeat assessment of endocardial GLS and endocardial TLS, and intraclass correlation (α value) was determined.

RESULTS

A total of 51 patients were recruited. Baseline characteristics are shown in Table 1. The mean age of the population was 60.4 ± 12.3 years and had male preponderance with 38 (74.5%) patients. The mean time of presentation of 51 patients to the hospital was 21.4 ± 7.7 hours from the onset of chest pain. Past history of coronary artery disease (CAD) was present

in 8 (15.7%) patients. All of them had stable angina without known coronary anatomy prior to this episode. Among them 3 were on antianginal medication prior to this event and the rest took no treatment for their symptoms.

Acute left ventricular failure and cardiogenic shock was present in 10 (19.6%) and 11 (21.6%) patients, respectively. Out of 42 patients who had undergone angiography, majority of the patients 38 (90.5%) had single vessel disease involving the LAD. All but 1 patient who had undergone had hemodynamically significant obstruction of LAD ($>70\%$ visual diametric stenosis on quantitative coronary angiography analysis). Only 1 patient had no evidence of coronary obstruction (possibly related to recanalization of LAD).

The mean left ventricular ejection fraction (LVEF) of the study group was $30.7 \pm 7.0\%$.

Since most studies have shown that endocardial layer is typically involved first during ischemic states and correlates best with the extent of ischemia, most analyses were performed using endocardial longitudinal strains. The mean endocardial GLS and LAD territory TLS of the study group was $11.45 \pm 2.92\%$ and $7.72 \pm 2.49\%$, respectively. On SPECT, 18 (35.3%) patients had nonviable underlying myocardium.

Parameters (Table 2) that were significantly associated with nonviability on SPECT included past history of CAD, dyslipidemia, and presentation with left ventricular failure or cardiogenic shock. The mean LVEF was significantly lower in the group with nonviability on SPECT ($34.2 \pm 4.8\%$ vs. $24.1 \pm 5.5\%$; $P < .001$). Both endocardial GLS ($12.9 \pm 1.4\%$ vs. $8.6 \pm 2.9\%$; $P < .001$) and endocardial TLS ($8.8 \pm 1.4\%$ vs. $5.7 \pm 2.7\%$;

Table 1. Baseline Patient Characteristics

Variable	Frequency
Mean age in years (\pm SD)	60.4 ± 12.3
Sex, n (%) (n=51)	
Female	13 (25.5%)
Male	38 (74.5%)
Mean BMI (kg/m ²) (\pm SD)	$22.9 (\pm 3.72)$
Co-Morbidities, n (%) (n = 51)	
Diabetes mellitus	11 (21.6%)
Hypertension	22 (43.1%)
Past history of CAD	8 (15.7%)
Smoking	9 (33.3%)
Dyslipidemia	15 (29.4%)
Complications, n (%) (n = 51)	
Acute left ventricular failure	10 (19.6%)
Cardiogenic shock	11 (21.6%)
Echocardiographic parameters (n = 51)	
Mean LVEF (%) (\pm SD)	$30.7 \pm 7.0\%$
Mean GLS (%) (\pm SD)	$-11.45 \pm 2.92\%$
Mean LAD territory TLS (%) (\pm SD)	$7.72 \pm 2.49\%$
Angiographic parameters, n (%) (n = 42)	
Single-vessel disease (LAD)	38 (90.5%)
Double-vessel disease	0
Triple-vessel disease	4 (9.5%)

All values are presented as the n (%). Continuous variables were presented as mean \pm SD. BMI, body mass index; CAD, coronary artery disease; LVEF, left ventricular ejection fraction; GLS, global longitudinal strain; LAD, left anterior descending artery; TLS, territorial longitudinal strain.

Table 2. Parameters Influencing Viability on SPECT

Variable	Nonviable (n = 18)	Viable (n = 33)	<i>P</i>
Age, years, mean (\pm SD)	$61.4 (\pm 12.2)$	$59.8 (\pm 12.5)$.65
Sex, n (%)			
Male	11 (61.1%)	27 (81.8%)	.17
Female	7 (39.9%)	6 (18.2%)	
Diabetes, n (%)	6 (33.3%)	5 (15.1%)	.16
Hypertension, n (%)	8 (44.4%)	14 (42.4%)	1
Dyslipidaemia, n (%)	10 (55.5%)	5 (15.1%)	.004
Smoking, n (%)	8 (44.4%)	11 (33.3%)	.54
Past history of CAD, n (%)	8 (44.4%)	0	<.001
Cardiogenic shock, n (%)	12 (66.7%)	0	<.001
Left ventricular failure, n (%)	11 (61.1%)	0	<.001
LVEF, %, mean \pm (SD)	$24.1 \pm (5.5\%)$	$34.2 \pm (4.8\%)$	<.001
GLS, %, mean \pm (SD)	$8.6 \pm (2.9\%)$	$-12.9 \pm (1.4\%)$	<.001
TLS, %, mean \pm (SD)	$-8.8 \pm (1.4\%)$	$-5.7 \pm (2.7\%)$	<.001

All values are presented as the n (%). Continuous variables were presented as mean \pm SD. CAD, coronary artery disease; LVEF, left ventricular ejection fraction; GLS, global longitudinal strain; TLS, territorial longitudinal strain.

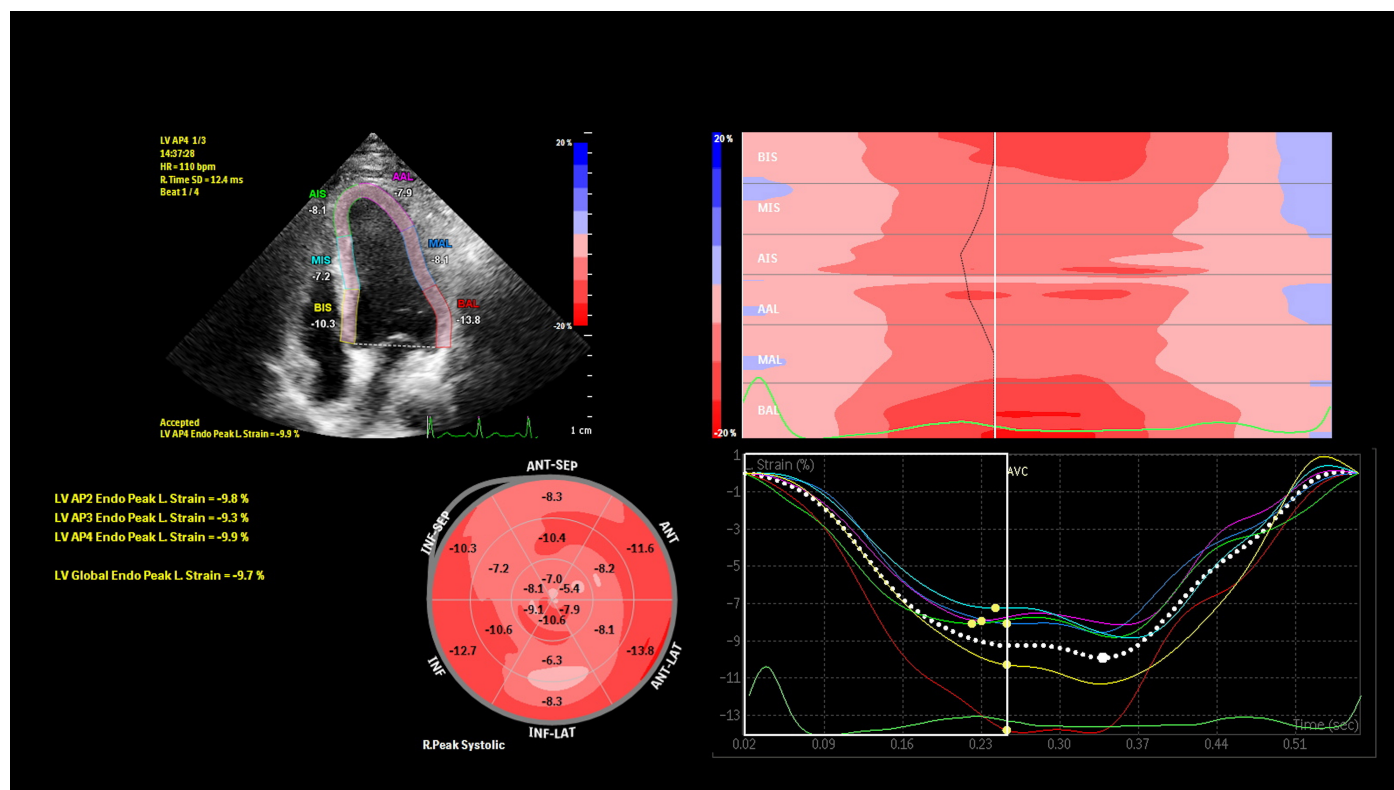


Figure 1. Strain echocardiography images from a patient presenting with anterior wall infarction 26 hours prior to admission. Echocardiography showed an ejection fraction of 32% and an akinetic left anterior descending artery (LAD) segments. On strain echocardiography, the patient had reduced strain in the basal, mid-anterior, and apical septum as well as apical and mid-anterior segments (see bulls' eye and strain curves). The left ventricular global peak longitudinal endocardial layer was 9.7% and TLS of LAD territory was 8.5%. The patient had adequate resting perfusion in all left ventricular segments suggestive of viable myocardium on SPECT imaging. Subsequently, he underwent stenting to a subtotal proximal LAD (type 3) lesion. TLS, territorial longitudinal strain.

$P < .001$) were significantly lower in group showing nonviability on SPECT (Figures 1 and 2).

Strain parameters of patients presenting with cardiogenic shock were also analyzed. Both endocardial GLS ($12.4 \pm 2.2\%$ vs. $7.5 \pm 2.2\%$; $P < .001$) and endocardial TLS ($8.4 \pm 1.8\%$ vs. $4.4 \pm 2.3\%$; $P < .001$) were significantly reduced in patients presenting with cardiogenic shock.

On ROCs, an endocardial GLS of $<10.45\%$ had a sensitivity of 77.8% and specificity of 93.9% (AUC, 0.889; 95% CI, 0.776-0.973; $P < .001$) in predicting nonviability on SPECT. Similarly, an endocardial TLS of $<7.60\%$ had a sensitivity of 77.8% and specificity of 84.8% (AUC, 0.813; 95% CI, 0.681-0.945; $P < .001$) in predicting nonviability. Both showed good accuracy in predicting nonviability on overall quality model.

In layer-specific strain analysis, all the 6 longitudinal strains were significantly decreased in the nonviable myocardium group ($P < .05$). Though there was no difference in performance of any of the longitudinal strain compared to the other ($P > .05$), on ROC curve the endocardial GLS had the best accuracy in predicting viability (AUC, 0.889; 95% CI, 0.776-0.973; $P < .001$) (Table 3 and Figure 3).

The decision to revascularize was based on the presence of viability on SPECT. Global longitudinal strain was determined for all patients but was not used to guide decision-making in our population. Out of 33 (64.7%) patients who had a viable myocardium, 27 (52.9%) patients underwent stenting to LAD artery. All of our patients had presented with evidence of acute AWMI on both electrocardiogram and echocardiogram. Hence, LAD was the culprit vessel in all cases. Only 4 cases had triple vessel disease on angiogram with noncritical disease ($<90\%$) in both left circumflex and right coronary arteries, and hence we believe they did not alter the overall results.

Reproducibility analysis was performed on 20 random echocardiography studies and endocardial GLS and TLS were assessed. The intraclass correlation coefficient (α value) for endocardial GLS was 0.91 and 0.85 for intra- and interobserver variability, respectively. While it was 0.87 and 0.84 for intra- and interobserver variability, respectively, during endocardial TLS measurement suggestive of good reproducibility.

DISCUSSION

Determination of the size and distribution of the infarcted segment and its viability is valuable for optimal management

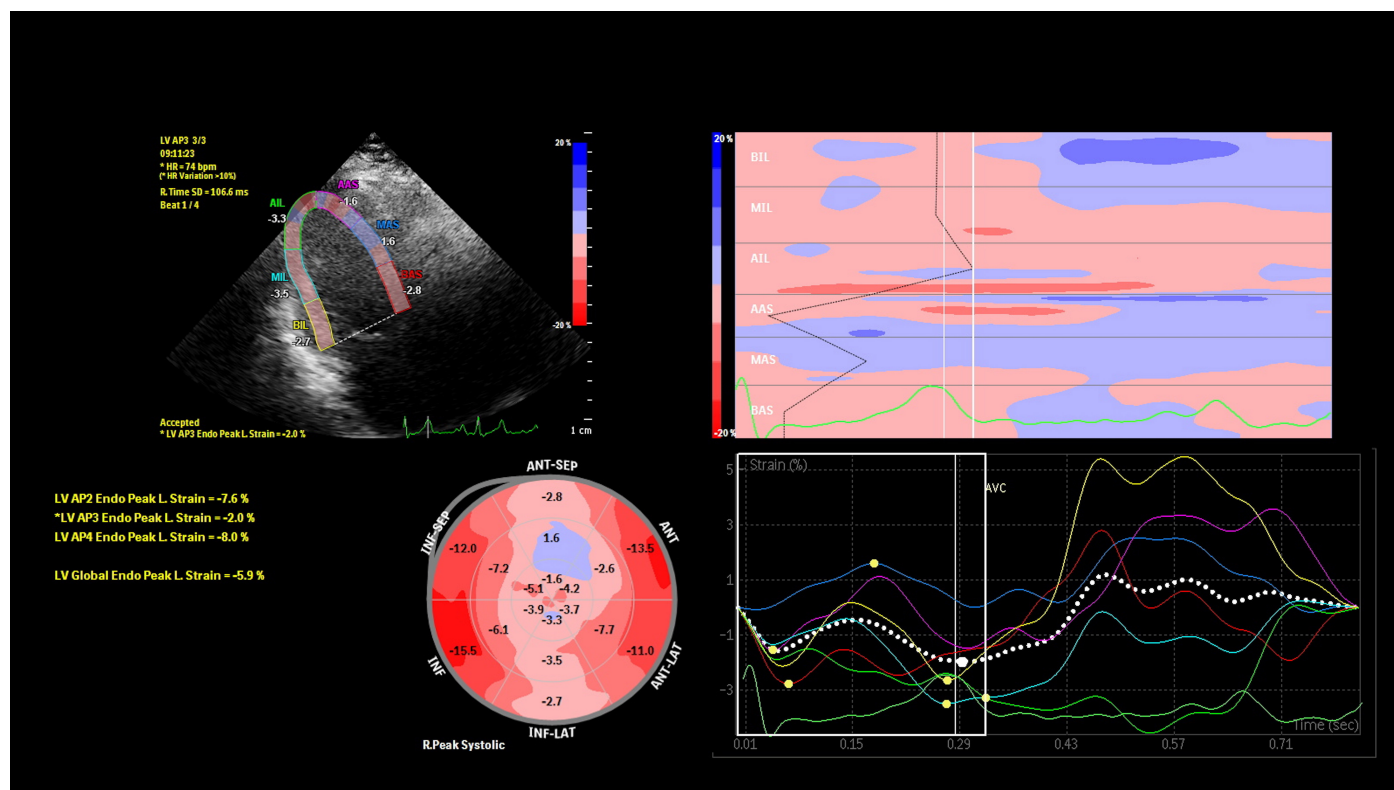


Figure 2. Strain echocardiography images from a patient presenting with anterior wall infarction 29 hours prior to admission. Echocardiography showed an ejection fraction of 30% and an akinetic left anterior descending artery (LAD) segments. On strain echocardiography, the patient had markedly reduced strain in the basal, mid-anterior, and apical septum as well as apical and mid-anterior segments (see bulls' eye and strain curves). The left ventricular global peak longitudinal endocardial was 5.9% and TLS of LAD territory was 3.8%. The patient had severely reduced perfusion in basal, mid-anterior, and apical septum, as well as in the mid-anterior segment involving 44-46% of left ventricular myocardium suggestive of nonviability on SPECT imaging. His angiogram revealed a subtotal proximal LAD (type 3) lesion and was managed conservatively.

and prognostication of patients of AWMI patients who present OWP.⁸ A recent study by Otaal et al showed that the presence of poor collateral on angiography in patients with totally occluded LAD on angiogram correlated with worse clinical outcomes. This indeed translates to the fact that nonviable myocardium (surrogate of poor collaterals) correlates with poor outcome.⁹ Cardiac biomarkers are non-specific and usually overestimate the extent of infarction.¹⁰ Bedside 2D echocardiography is helpful for prompt estimation of hypokinetic or akinetic segments, but correlate poorly with pathological changes.¹¹ Hence it is insufficient for estimation of myocardial viability.

With the advancement in medical technologies, modalities such as SPECT, positron emission tomography (PET), dobutamine stress echocardiography (DSE), and late gadolinium enhancement by cardiac magnetic resonance have come up, all of which have shown good accuracy in predicting myocardial viability.¹²⁻¹⁵ However, each of these modalities has certain adverse/untoward effects which render their use impractical in certain situations.

Single-photon emission computed tomography and positron emission tomography both are expensive and require radionuclide contrast administration, DSE carries risk of malignant ventricular arrhythmia and is challenging in acute

AWMI patients, cardiac magnetic resonance requires the administration of gadolinium contrast which is contraindicated in patients with renal dysfunction and besides it is expensive. A common theme across all these modalities is the time needed to perform and interpret these investigations which in patients of MI directly translate into ongoing myocardial ischemia. Another fact is that they might not be readily available especially in resource-constrained setting.

Though strain echocardiography has widely reported to correlate with viability in chronic LV dysfunction patients,¹⁶ there is limited data on its accuracy in the acute setting. Global longitudinal strain has previously been demonstrated to be a strong predictor of LV remodeling and subsequent major cardiovascular events.¹⁷ Global longitudinal strain of <13% was 80% sensitive and 83% specific in predicting the extent of transmural infarction on CMR.¹⁸ Another study by Eek et al showed good accuracy of GLS with CMR viability at a GLS of <13.8% in non-ST-elevation myocardial infarction (NSTEMI) patients.¹⁹ In a recent meta-analysis, comprising STEMI and NSTEMI patients, GLS had good accuracy at predicting viability compared to CMR.²⁰ Limited studies have evaluated viability prediction by strain echocardiography in STEMI patients with varying accuracy.²¹⁻²⁴

Table 3. Comparison of Layer-Specific Strain Among the Viable and Nonviable Myocardium Groups

Variable	Viable Myocardium (n=33)	Nonviable Myocardium (n=18)	P
Epicardial GLS ± (SD)	10.2 ± 1.7	6.8 ± 2.4	<.001
Mid-myocardial GLS ± (SD)	11.48 ± 1.7	7.6 ± 2.6	<.001
Endocardial GLS ± (SD)	12.9 ± 1.4	8.6 ± 2.9	<.001
Epicardial TLS ± (SD)	7.2 ± 1.4	4.8 ± 2.6	<.001
Mid-myocardial TLS ± (SD)	8.0 ± 1.5	5.3 ± 2.6	<.001
Endocardial TLS ± (SD)	8.8 ± 1.4	5.7 ± 2.7	<.001

Continuous variables were presented as mean ± SD. GLS, global longitudinal strain; TLS, territorial longitudinal strain.

To the best of our knowledge, this is the first study focusing solely on determining viability in OWP AWMIs patients using strain echocardiography. In our study, we compared myocardial deformation estimation by speckle tracking 2D strain with SPECT which is most commonly used for viability estimation at our center. We found that either an endocardial GLS of <10.45% or an endocardial TLS of <7.60% both had good accuracy in determining nonviability on SPECT as determined by the ROC curve and the overall quality model. Recent studies by Cimino et al²⁵ and Bendary et al²⁶ both showed improved accuracy of TLS in predicting myocardial infarct size and extent compared to GLS. Hence, given the high accuracy of GLS and TLS in our study, there is cautious optimism regarding its clinical application in selected patients who are unsuitable for undergoing conventional imaging and need viability estimation in a timely manner.

Layer-specific strain analysis allows assessment of each of the myocardial layers separately. Longitudinal endocardial layer is indeed the most sensitive parameter for detecting the presence of ischemia as the endocardial layer is first involved in the ischemic process. This has been validated in prior studies on patients with acute coronary syndromes as well as in those with stable angina.^{27,28} However, once there is significant CAD, all of the layers are involved eventually. In a recent study, it has been shown that both GLS and layer-specific strain when used in combination can help increase the diagnostic accuracy of SPECT.²⁹ We have shown in our study that amongst the layer-specific longitudinal strains, endocardial GLS had the best correlation with non-viability on SPECT.

A major limitation is the small size of our study and the fact we only recruited OWP AWMIs patients. Hence, our results cannot be generalized to all STEMI patients. Another limitation is that we did not take into account the coronary anatomy variations. Myocardial function assigned to a specific vascular territory by Cerqueira et al⁶ may not necessarily reflect the real coronary distribution. Furthermore, networks formed by microvascular communications between coronary arteries can give rise to zones of dual arterial perfusion, making strict regional analysis somewhat inaccurate. Larger studies are needed to validate the findings of the current study. However, despite the small sample size, the strong agreement between strain echocardiographic parameters and viability on SPECT merits attention.

CONCLUSION

Treatment strategies in patients presenting with AWMIs, outside the window period, are largely guided by the hemodynamic status and influenced by the viability status of the

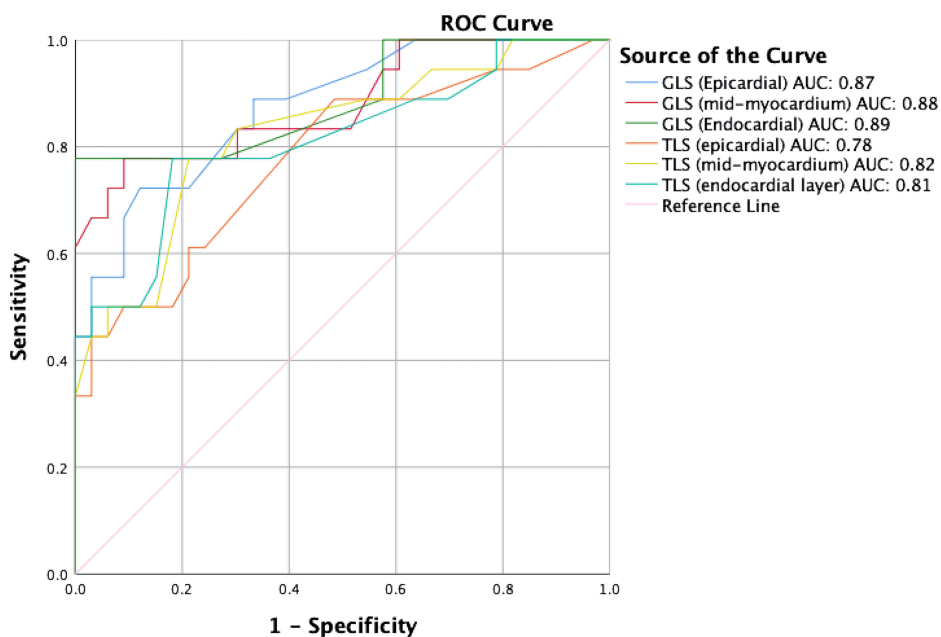


Figure 3. Excellent accuracy of all the layer-specific global longitudinal strain (GLS) and territorial longitudinal strain (TLS) parameters in predicting nonviability on SPECT on ROC curve. Endocardial GLS had the best accuracy in predicting viability (AUC, 0.889; 95% CI, 0.776-0.973; P <.001). SPECT, single-photon emission computed tomography; ROC, receiver operating curve

myocardium. Modalities like CMR, SPECT, or PET are resource dependent and take time to be performed. Hence, performing these investigations is challenging in frail, unstable patients or those with renal dysfunction. Strain echocardiography using speckle tracking provides GLS and TLS, both of which have good sensitivity and specificity in predicting viability and can be performed safely and quickly in this high-risk group.

Ethics Committee Approval: The study protocol conforms to the ethical guidelines of the declaration of Helsinki and was reviewed and cleared by the Ethical Committee of the Institute (Post Graduate Institute of Medical Education & Research).

Informed Consent: Written informed consent was obtained from all participants who participated in this study.

Peer-review: Externally peer-reviewed.

Author Contributions: Concept – Y.P.S., A.B.; Design – Y.P.S., A.B., N.K.; Supervision – Y.P.S., P.P.; Funding – Y.P.S.; Materials – Y.P.S.; Data Collection and/or Processing – Y.P.S., A.B., N.K.; Analysis and/or Interpretation – Y.P.S., A.B., N.K., J.H., K.M., P.P.; Literature Review – A.B., N.K., J.H.; Writing – A.B., N.K., J.H.; Critical Review – Y.P.S., P.P.

Acknowledgments: None.

Declaration of Interests: The authors declare that they have no competing interest.

Funding: This study received no funding.

REFERENCES

- Newman JD, Shimbo D, Baggett C, et al. Trends in myocardial infarction rates and case fatality by anatomical location in four United States communities, 1987-2008 (from the Atherosclerosis Risk in Communities Study). *Am J Cardiol.* 2013;112(11):1714-1719. [\[CrossRef\]](#)
- Bansal K, Gore M, Nalabothu P. Anterior Myocardial Infarction. 2022 Feb 12. In: StatPearls [Internet]. Treasure Island (FL): StatPearls Publishing; 2022.
- Sharma YP, Krishnappa D, Kanabar K, et al. Clinical characteristics and outcome in patients with a delayed presentation after ST-elevation myocardial infarction and complicated by cardiogenic shock. *Indian Heart J.* 2019;71(5):387-393. [\[CrossRef\]](#)
- Baran I, Ozdemir B, Gullulu S, Kaderli AA, Senturk T, Aydinlar A. Prognostic value of viable myocardium in patients with non-Q-wave and Q-wave myocardial infarction. *J Int Med Res.* 2005;33(5):574-582. [\[CrossRef\]](#)
- Voigt JU, Pedrizzetti G, Lysyansky P, et al. Definitions for a common standard for 2D speckle tracking echocardiography: consensus document of the EACVI/ASE/Industry Task Force to standardize deformation imaging. *Eur Heart J Cardiovasc Imaging.* 2015;16(1):1-11. [\[CrossRef\]](#)
- Cerqueira MD, Weissman NJ, Dilsizian V, et al. Imaging AHA/GoMSaRfC. Standardized myocardial segmentation and nomenclature for tomographic imaging of the heart: a statement for healthcare professionals from the Cardiac Imaging Committee of the Council on Clinical Cardiology of the American Heart Association. *Circulation.* 2002;105(4):539-542. [\[CrossRef\]](#)
- Collet J-P, Thiele H, Barbato E, et al. ESC Guidelines for the management of acute coronary syndromes in patients presenting without persistent ST-segment elevation: the Task Force for the management of acute coronary syndromes in patients presenting without persistent ST-segment elevation of the European Society of Cardiology (ESC). *Eur Heart J.* 2021;42(14):1289-1367.
- Allman KC, Shaw LJ, Hachamovitch R, Udelson JE. Myocardial viability testing and impact of revascularization on prognosis in patients with coronary artery disease and left ventricular dysfunction: a meta-analysis. *J Am Coll Cardiol.* 2002;39(7):1151-1158. [\[CrossRef\]](#)
- Otaal PS, Shah A, Batta A, Sood A, Pal A. Clinical and angiographic prophesy of hemodynamic status in patients with acute anterior wall ST-segment-elevation myocardial infarction and totally occluded left anterior descending artery. *Integr Blood Press Control.* 2021;14:89-97. [\[CrossRef\]](#)
- American College of Cardiology Foundation Task Force on Expert Consensus Documents, Hundley WG, Bluemke DA, et al. ACCF/ACR/AHA/NASCI/SCMR 2010 expert consensus document on cardiovascular magnetic resonance: a report of the American College of Cardiology Foundation Task Force on Expert Consensus Documents. *J Am Coll Cardiol.* 2010;55(23):2614-2662. [\[CrossRef\]](#)
- Kalam K, Otahal P, Marwick TH. Prognostic implications of global LV dysfunction: a systematic review and meta-analysis of global longitudinal strain and ejection fraction. *Heart.* 2014;100(21):1673-1680. [\[CrossRef\]](#)
- Dilsizian V, Rocco TP, Freedman NM, Leon MB, Bonow RO. Enhanced detection of ischemic but viable myocardium by the reinjection of thallium after stress-redistribution imaging. *N Engl J Med.* 1990;323(3):141-146. [\[CrossRef\]](#)
- Mauro VM, Cianciulli TF, Prezioso HA, et al. Dobutamine stress echocardiography can predict reversible ventricular dysfunction after acute myocardial infarction. *Clin Cardiol.* 2005;28(11):523-528. [\[CrossRef\]](#)
- Park SM, Hong SJ, Kim YH, Ahn CM, Lim DS, Shim WJ. Predicting myocardial functional recovery after acute myocardial infarction: relationship between myocardial strain and coronary flow reserve. *Korean Circ J.* 2010;40(12):639-644. [\[CrossRef\]](#)
- Romero J, Kahan J, Kelesidis I, et al. CMR imaging for the evaluation of myocardial stunning after acute myocardial infarction: a meta-analysis of prospective trials. *Eur Heart J Cardiovasc Imaging.* 2013;14(11):1080-1091. [\[CrossRef\]](#)
- Weidemann F, Dommke C, Bijnens B, et al. Defining the transmural extent of a chronic myocardial infarction by ultrasonic strain-rate imaging: implications for identifying intramural viability: an experimental study. *Circulation.* 2003;107(6):883-888. [\[CrossRef\]](#)
- Park YH, Kang SJ, Song JK, et al. Prognostic value of longitudinal strain after primary reperfusion therapy in patients with anterior-wall acute myocardial infarction. *J Am Soc Echocardiogr.* 2008;21(3):262-267. [\[CrossRef\]](#)
- Gjesdal O, Hopp E, Vartdal T, et al. Global longitudinal strain measured by two-dimensional speckle tracking echocardiography is closely related to myocardial infarct size in chronic ischaemic heart disease. *Clin Sci (Lond).* 2007;113(6):287-296. [\[CrossRef\]](#)
- Eek C, Grenne B, Brunvand H, Aakhus S, Endresen K, Hol PK, et al. Strain echocardiography and wall motion score index predicts final infarct size in patients with non-ST-segment-elevation myocardial infarction. *Circ Cardiovasc Imaging.* 2010;3(2):187-94.
- Diao KY, Yang ZG, Ma M, et al. The diagnostic value of global longitudinal strain (GLS) on myocardial infarction size by echocardiography: a systematic review and meta-analysis. *Sci Rep.* 2017;7(1):10082. [\[CrossRef\]](#)
- Altioek E, Tiemann S, Becker M, et al. Myocardial deformation imaging by two-dimensional speckle-tracking echocardiography for prediction of global and segmental functional changes

- after acute myocardial infarction: a comparison with late gadolinium enhancement cardiac magnetic resonance. *J Am Soc Echocardiogr.* 2014;27(3):249-257. [\[CrossRef\]](#)
22. Gjesdal O, Helle-Valle T, Hopp E, et al. Noninvasive separation of large, medium, and small myocardial infarcts in survivors of reperfused ST-elevation myocardial infarction: a comprehensive tissue Doppler and speckle-tracking echocardiography study. *Circ Cardiovasc Imaging.* 2008;1(3):189-96, 2 p following 196. [\[CrossRef\]](#)
 23. Vartdal T, Pettersen E, Helle-Valle T, et al. Identification of viable myocardium in acute anterior infarction using duration of systolic lengthening by tissue Doppler strain: a preliminary study. *J Am Soc Echocardiogr.* 2012;25(7):718-725. [\[CrossRef\]](#)
 24. Batta A, Sharma YP, Makkar K, Hatwal J, Malhi T, Panda P. Accuracy of global longitudinal and territorial longitudinal strain in determining myocardial viability in out of window period Anterior wall myocardial infarction patients. *Eur Heart J.* 2022;43(Supplement_1). [\[CrossRef\]](#)
 25. Cimino S, Canali E, Petronilli V, et al. Global and regional longitudinal strain assessed by two-dimensional speckle tracking echocardiography identifies early myocardial dysfunction and transmural extent of myocardial scar in patients with acute ST elevation myocardial infarction and relatively preserved LV function. *Eur Heart J Cardiovasc Imaging.* 2013;14(8):805-811. [\[CrossRef\]](#)
 26. Bendary A, Afifi M, Tawfik W, Mahros M, Ramzy A, Salem M. The predictive value of global longitudinal strain on late infarct size in patients with anterior ST-segment elevation myocardial infarction treated with a primary percutaneous coronary intervention. *Int J Cardiovasc Imaging.* 2019;35(2):339-346. [\[CrossRef\]](#)
 27. Liu C, Li J, Ren M, et al. Multilayer longitudinal strain at rest may help to predict significant stenosis of the left anterior descending coronary artery in patients with suspected non-ST-elevation acute coronary syndrome. *Int J Cardiovasc Imaging.* 2016;32(12):1675-1685. [\[CrossRef\]](#)
 28. Nishi T, Funabashi N, Ozawa K, et al. Resting multilayer 2D speckle-tracking transthoracic echocardiography for the detection of clinically stable myocardial ischemic segments confirmed by invasive fractional flow reserve. Part 1: vessel-by-vessel analysis. *Int J Cardiol.* 2016;218:324-332. [\[CrossRef\]](#)
 29. Hagemann CE, Hoffmann S, Olsen FJ, et al. Layer-specific global longitudinal strain reveals impaired cardiac function in patients with reversible ischemia. *Echocardiography.* 2018;35(5):632-642. [\[CrossRef\]](#)