

A Rare Source of Iatrogenic Ventricular Tachycardia: Septal Aneurysm due to Premature Ventricular Complex Ablation

INTRODUCTION

Catheter ablation (CA) is a widely used successful intervention method in the treatment of symptomatic frequent premature ventricular complex (PVC) and ventricular tachycardia (VT). In this case, we present the successful VT ablation procedure in a patient with PVC ablation-associated ventricular septal aneurysm.

CASE REPORT

A 64-year-old male patient with a history of ischemic heart disease was admitted to our hospital with a complaint of palpitation. The patient had documented regular wide QRS tachycardia, which could not be clearly differentiated from VT/supraventricular tachycardia. Echocardiography was significant for a newly

CASE REPORT

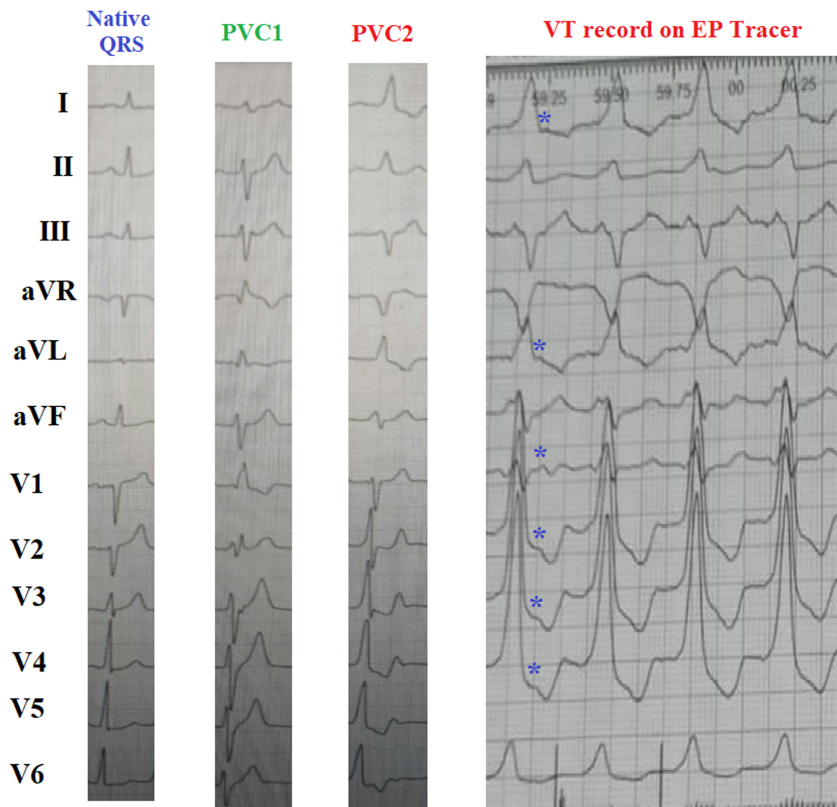


Figure 1. Two different PVC morphologies seen in the superficial ECG recording of the patient during the PVC ablation procedure performed 1 year ago. It is observed that PVC2 and the patient's VT morphology show a strong similarity. Atrioventricular (AV) dissociation is seen, supporting that the tachyarrhythmia is VT. *atrial depolarization waves; PVC, premature ventricular complex; VT, ventricular tachycardia.

Kübra Korkmaz ^{ID}
Yakup Yunus Yamantürk ^{ID}
Emir Baskovski ^{ID}
Başar Candemir ^{ID}
Ömer Akyürek ^{ID}
Ali Timuçin Altın ^{ID}

Department of Cardiology, Faculty of
Medicine, Ankara University, Ankara,
Türkiye

Corresponding author:

Kübra Korkmaz
✉ kubrakorkmaz1993@gmail.com

Cite this article as: Korkmaz K,
Yamantürk YY, Baskovski E, Candemir
B, Akyürek Ö, Altın AT. A rare source of
iatrogenic ventricular tachycardia:
septal aneurysm due to premature
ventricular complex ablation. *Anatol J
Cardiol.* 2023;27(8):494-496.



Copyright©Author(s) - Available online at anatoljcardiol.com.
Content of this journal is licensed under a Creative Commons Attribution-NonCommercial
4.0 International License.

DOI:10.14744/AnatolJCardiol.2023.2979

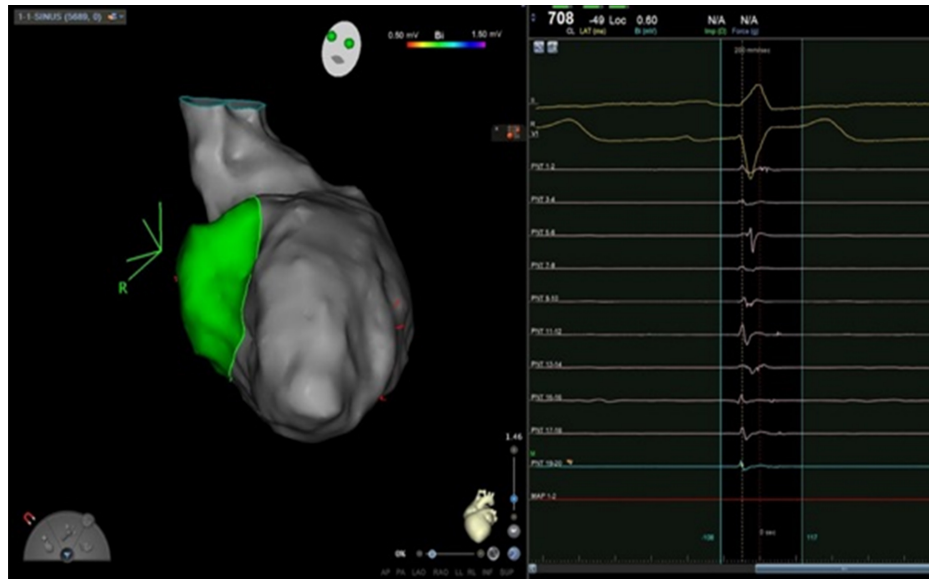


Figure 2. The areas were given radiofrequency (RF) ablation.

developed aneurysm in the interventricular septum. One year ago, the patient had a catheter ablation (CA) history for high PVC burden (15% of total beats, under maximal medical therapy). There was no aneurysm in the interventricular septum and ejection fraction (EF) value was measured 40%-45% in preprocedural transthoracic echocardiography. According to the prior procedure report, extensive ablation of basal-to-mid septum (4 different morphological PVCs were induced and ablated which were originated from posteromedial papillary muscle, apex, midseptum, and parahisian region) was performed for PVCs (Figures 1 and 2). Based on this and the absence of new-onset coronary events (confirmed by coronary angiography), it was presumed that the septal aneurysm may be related to the previous ablation procedure. During the electrophysiologic study, tachycardia was confirmed to be a VT. Ventricular tachycardia ablation was planned

primarily due to recurrent VT attacks that lead to hemodynamic instability. The left ventricle was mapped during sinus rhythm. Ventricular tachycardia was induced; however, it could not be mapped because of quick termination. Isochronal late activation mapping (ILAM) and Decrement-Evoked Potential (DeEP) mapping were performed. The pace-mapping correlation was found 95% from the inferior base of the septum (Figures 3 and 4). All target areas were ablated upon which VT was non-inducible.

One year ago, intracardiac defibrillator (ICD) implantation was not considered because EF was measured 40%-45% on echocardiography during VES ablation. In this admission, a newly onset decrease of EF value was detected on echocardiography, and since no new severe obstructive lesion was detected in coronary angiography, cardiac magnetic resonance imaging (MRI) and resting multigated acquisition

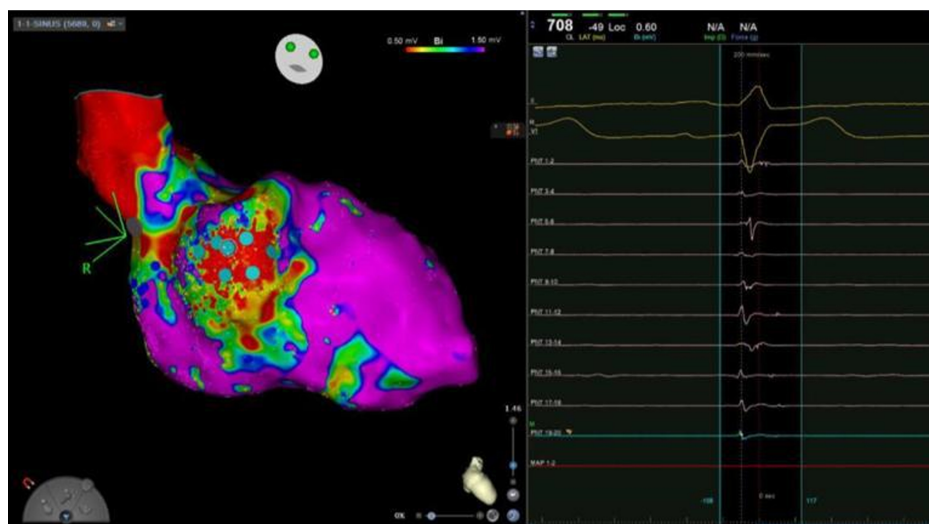


Figure 3. A septal aneurysm area with patchy scars is seen on voltage mapping. Areas with high correlation to VT morphology by pace-mapping technique are marked with blue dots.

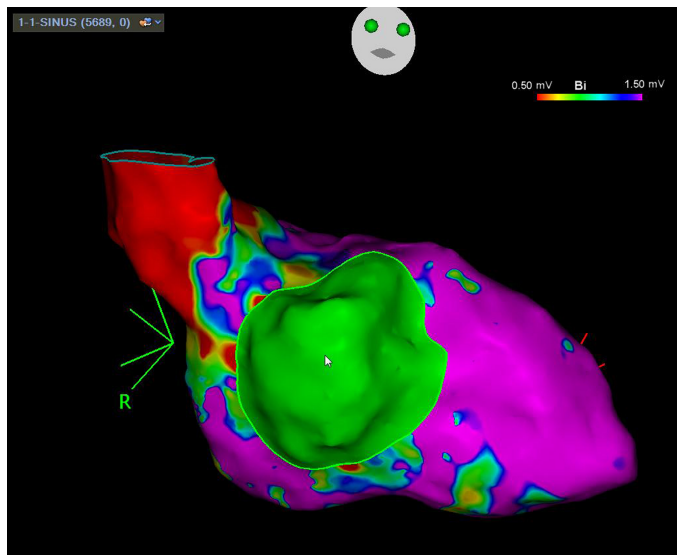


Figure 4. A septal aneurysm area with patchy scars is seen on voltage mapping. Areas with high correlation to VT morphology by pace-mapping technique are marked with blue dots.

scan (MUGA) were planned for ICD implantation decision to aim secondary prevention of sudden cardiac death. As per the cardiac imaging results, left ventricular ejection fraction (LVEF) was calculated as 30% and anterior and lateral walls were seen hypokinetic and the septum was akinetic and thin. Late gadolinium enhancement, which was detected in large areas, was correlated with the ischemic pattern. According to these results, in a separate procedure, a single-chamber ICD was implanted in the patient for secondary prevention of sudden cardiac death. No VT episode was detected in the patient's outpatient controls.

Extensive ablation of the basal-middle septum, newly developed interventricular aneurysm confirmed by MRI, the proximity of the VT originating area to the aneurysm, and the absence of any VT attack by the previous PVC burden suggest that VT is associated with aneurysm.

Due to an interventricular septum aneurysm and a recently extensive ablation procedure, anticoagulant therapy was

started. No septal leak or ventricular thrombus was observed in the control echocardiography.

DISCUSSION

In the literature, iatrogenic VT from PVC ablation-associated septal aneurysm has not been reported before. The patient had a predisposing factor to arrhythmia due to ischemic background and reduced LVEF. However, it was thought that the clinical VT episodes of the patient were mainly related to the reentry formed on the basis of periscar tissue due to the septal aneurysm developed as a result of ablation.^{1,2}

Aneurysm existence is a poor prognostic risk factor for the development of ventricular arrhythmias, heart failure, and thromboembolic events after PVC ablation. Especially in patients whose VT ablation target site is a septal aneurysm, the risk of septal rupture and thrombus formation during ablation is quite high. Despite all these factors, ablation was successfully performed.

In conclusion, it should be remembered that although the septum is usually a thick structure, extensive ablation may lead to aneurysm formation, which may even be a source of ventricular arrhythmias.

Informed Consent: Written informed consent was obtained from patient.

Declaration of Interests: The authors have no conflict of interest to declare.

Funding: The authors declared that this study has received no financial support.

REFERENCES

1. Uchida F, Fujii E, Matsuoka K, et al. Idiopathic left ventricular aneurysm associated with pleomorphic ventricular tachycardia: a case report. *J Cardiol.* 2002;40(6):275-282.
2. Santamaria M, Cireddu M, Riva S, Trevisi N, Della Bella P. Radiofrequency catheter ablation guided by noncontact mapping of ventricular tachycardia originating from an idiopathic left ventricular aneurysm. *J Interv Card Electrophysiol.* 2007;19(1):49-53. [[CrossRef](#)]