




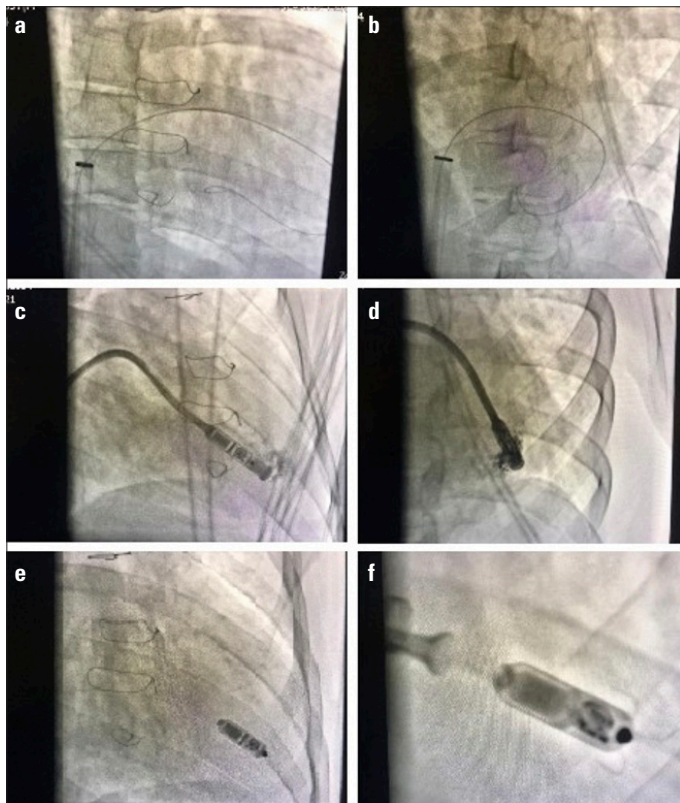


# Implantation of a leadless pacemaker in a patient after the Senning procedure—a case report

Wiktoria Kowalska\* , Ewa Jędrzejczyk-Patej\*\* ,  
Marta Jagosz\* , Zbigniew Kalarus<sup>1</sup> , Beata Średniawa<sup>1</sup>   
\*Student Scientific Circle at the \*\*Department of Cardiology,  
Congenital Heart Diseases and Electrotherapy, Silesian Center of  
Heart Diseases; Zabrze-Poland  
<sup>1</sup>School of Medicine with the Division of Dentistry in Zabrze, Medical  
University of Silesia; Katowice-Poland

## Introduction

Transposition of the great arteries (TGA) is a congenital cardiac malformation characterized by atrioventricular concordance and ventriculoarterial discordance. Its incidence is estimated at 1 in 3,500–5,000 live births, and surgery still remains the treatment of choice. The Senning procedure, which was a major operation decades ago, has recently been replaced by the arterial switch operation (e.g., Jatene procedure). One of the most serious complications is damage to the sinus node and atrial tissue, and over 20% of patients who have been surgically corrected, require a pacemaker (1).



**Figure 1.** (a, b) Contrast-enhanced imaging; (c-f) Location of the Micra™ device in fluoroscopy during the implantation procedure: c-RAO view, d-LAO view, e-final position of the device, f-pull and hold test

## Case Report

This case involves a 34-year-old patient who underwent the Senning procedure in childhood for the correction of TGA. The patient had a sinus node dysfunction and was frequently hospitalized to undergo cardioversion due to recurrent episodes of atrial fibrillation (AF) and atrial flutter (AFL) until a thrombus in the left atrium was recognized in 2013 and the following cardioversion was cancelled. AF persisted together with periodic atrioventricular conduction disturbances, resulting in symptomatic (presyncope) bradyarrhythmias. The longest registered pause due to arrest lasted nine seconds. Despite the discontinuation of  $\beta$ -blockers, the patient still experienced tachy- and bradyarrhythmias, making him eligible for leadless pacemaker implantation by the Heart Team. On admission, the subject was in a good condition, with a low physical activity tolerance (New York Heart Association class II). Routine transthoracic echocardiography demonstrated typical features of TGA after the Senning operation. The right (systemic) ventricle end-diastolic dimension was 48 mm, and small tricuspid regurgitation was observed.

Implantation of the leadless pacemaker Micra™ Transcatheter Pacing System (Micra TPS, Medtronic, Minneapolis, MN, USA) was performed under general anesthesia in the cath lab. An access through the left femoral vein with the use of a 23-Fr sheath (occluded right femoral vein) was obtained. The pacemaker was fixated into the apical-septal segment of the morphological left chamber. During the procedure, a single intravenous bolus of 5,000 units of heparin were administered. Pull and hold test was performed, exhibiting three nitinol tines fixated in the myocardium (Fig. 1a-1f). After removing the sheath, a hemostatic suture was placed and a pacemaker was programmed. No complications were observed. The fluoroscopy time was 10 minutes, exposition dose 664 mGy, and Dose Area Product (DAP) 6 170  $\mu\text{Gy}\cdot\text{m}^2$ . Electrical parameters during implantation were as following: sensing 2.9 mV, impedance 840 Ohm, and pacing threshold 0.25 V/0.24 ms.

Pharmacological treatment was optimized with  $\beta$ -blocker (carvedilol, then metoprolol) and anticoagulants (warfarin, recommended INR level: 2.0–3.0). During the follow-up of 782 days, no pre- and syncope were noted. After two years from implantation, electrical parameters were as following: R wave 8.3 mV, impedance 650 Ohms, pacing threshold 0.38V/0.24 ms, and stimulation percentage 33.5%.

## Discussion

The main finding of our case report is that the implantation of a leadless pacemaker is effective and feasible in patients with TGA after the Senning operation. The only case report of Micra™ implantation in a patient with TGA after the Mustard surgery has only been published as an abstract (2).

A transvenous pacemaker in a patient with congenital heart disease (CHD) is associated with a higher incidence of thromboembolic events and infection (3). Pacemaker implantation in this group is a challenge not only due to the abnormal anatomy of the heart, but also due to limited venous access. A transvenous lead might cause valve regurgitation and worsen patient's prognosis. Leadless pacing allows the elimination of complications associated with the presence of leads and the pulse generator (4). Even though the baffle had no narrowing, the absence of leads seemed to be a safer option in this specific anatomical presentation.

The Micra™ TPS is expected to have a battery life of over 10 years. The manufacturer provides that more than one (and up to three) devices may be fixed within the ventricle without any hemodynamic deterioration of its function (2, 5). This gives over twenty years of an effective therapy. At the same time, we hope and expect that the next 20 years will bring novel solutions to the pacing therapy. A new function has recently been introduced to the leadless pacemakers—the atrioventricular synchronous pacing. VDD stimulation has now become possible only after six years from the first Micra™ implantation. In case of the need for an implantable cardioverter defibrillator (ICD), a subcutaneous ICD (S-ICD) will be considered first, as it was published that it is feasible for adults with CHD patients (6).

## Conclusion

Implantation of a leadless pacemaker could be an effective and feasible solution in patients with transposition of TGA after the Senning procedure, with indications for pacing despite the need for pacing in unconventional sites. Nevertheless, although this new technology is promising, it still requires further observation and more experience.

**Informed consent:** Written informed consent was obtained from the patient and patient's family for publication of this case report and any accompanying images.

**Conflict of interest:** E.J.P. – consultant fees from Medtronic, Biotronik, Abbott, Boston Scientific; B.Ś. – consultancy fee Medtronic Bakken Research Center. No conflict of interest for other authors.

## References

1. Puley G, Siu S, Connelly M, Harrison D, Webb G, Williams WG, et al. Arrhythmia and survival in patients >18 years of age after the mustard procedure for complete transposition of the great arteries. *Am J Cardiol* 1999; 83: 1080-4. [\[Crossref\]](#)
2. Alasti M, Kotschet E, Alison J. Micra Transcatheter Pacing System implantation in a Patient with a History of Mustard Repair and Transposition of Great Arteries. *Heart, Lung and Circulation* 2018; 27 (Suppl 2): S178. [\[Crossref\]](#)
3. Karsenty C, Zhao A, Marijon E, Ladouceur M. Risk of thromboembolic complications in adult congenital heart disease: A literature review. *Arch Cardiovasc Dis* 2018; 111: 613-20. [\[Crossref\]](#)
4. Duray GZ, Ritter P, El-Chami M, Narasimhan C, Omar R, Tolosana JM, et al.; Micra Transcatheter Pacing Study Group. Long-term performance of a transcatheter pacing system: 12-Month results from the Micra Transcatheter Pacing Study. *Heart Rhythm* 2017; 14: 702-9. [\[Crossref\]](#)
5. Sánchez P, Apolo J, San Antonio R, Guasch E, Mont L, Tolosana JM. Safety and usefulness of a second Micra transcatheter pacemaker implantation after battery depletion. *Europace* 2019; 21: 885. [\[Crossref\]](#)
6. Moore JP, Mondésert B, Lloyd MS, Cook SC, Zaidi AN, Pass RH, et al.; Alliance for Adult Research in Congenital Cardiology (AARCC). Clinical Experience With the Subcutaneous Implantable Cardioverter-Defibrillator in Adults With Congenital Heart Disease. *Circ Arrhythm Electrophysiol* 2016; 9: e004338. [\[Crossref\]](#)

**Address for Correspondence:** Wiktoria Kowalska, MD,  
Department of Cardiology, Congenital Heart Diseases and Electrotherapy,  
Silesian Center for Heart Diseases, Skłodowskiej-Curie 9, 41-800 Zabrze - Poland  
Phone: 0048 32 37 33 682  
E-mail: vicky.kowalska@gmail.com  
©Copyright 2021 by Turkish Society of Cardiology - Available online at  
[www.anatoljcardiol.com](http://www.anatoljcardiol.com)  
DOI:10.14744/AnatolJCardiol.2020.36453

