

## Anomalous origin of the right coronary artery from the pulmonary artery in an asymptomatic child

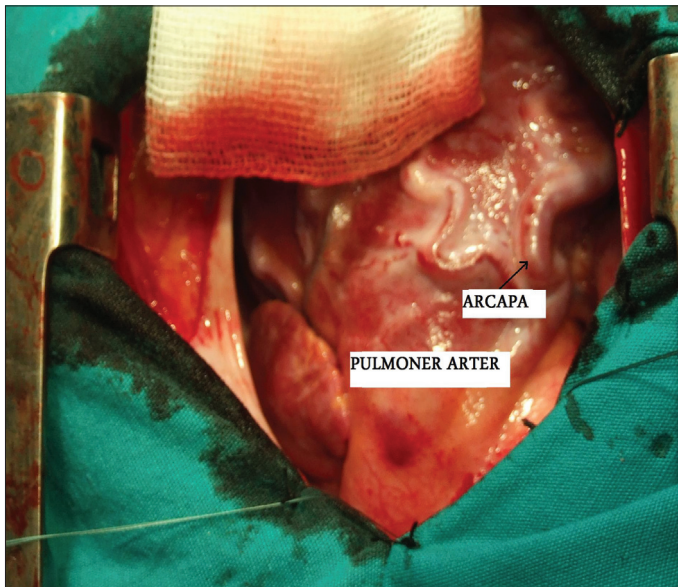


### *Asemptomatik bir çocukta pulmoner arterden çıkan anomal sağ koroner arter*

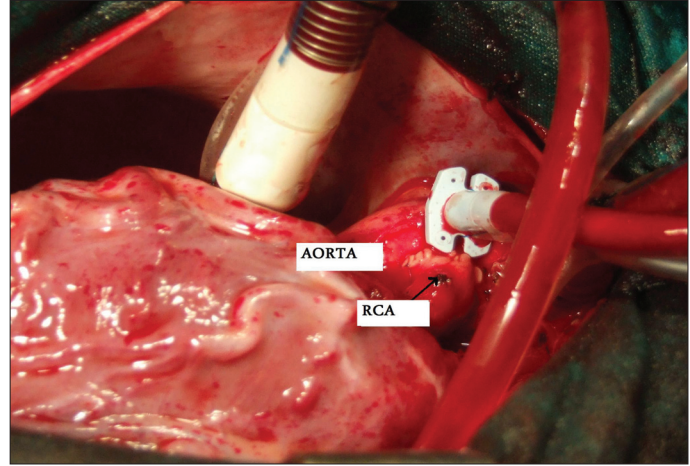
The abnormally originating right coronary artery from the pulmonary artery (ARCAPA) is a rare congenital anomaly. Although anomalous origin of the left coronary artery from the pulmonary artery (PA) presents in early infancy, symptoms in patients with the ARCAPA may rarely present in infancy. Only a few of them are discovered incidentally in childhood, most of the patients remain asymptomatic and they may be detected at the time of coronary angiography in later adult life. Therefore, the true incidence of this anomaly might be underdetermined.

A previously healthy asymptomatic 8-year-old boy was referred for the evaluation of a continuous murmur detected during school screening program. There were no diagnostic electrocardiographic or chest roentgenographic changes. Echocardiographic examination revealed spherical left ventricle shape with normal ventricular functions. Left coronary ostium was enlarged, but right coronary ostium could not be seen on echocardiographic examination. Selective left coronary arteriography showed retrograde filling of the right coronary artery from collateral vessels and opening to the PA (Video 1 and 2. See corresponding video/movie images at [www.anakarder.com](http://www.anakarder.com)). Aortic root injection also showed absent right coronary artery ostium originating from the aortic root.

The surgical correction is always recommended to avoid myocardial ischemia in later life and to abolish left- to- right shunt that causing volume overload. The operative correction in our patient was performed by detaching the anomalous right coronary artery from the PA and re-implantation it to the aorta, so double-ostium coronary system is restored (Fig. 1 and 2). The patient's postoperative course was uneventful.



**Figure 1. Preoperative view of right coronary artery originating from pulmonary artery**



**Figure 2. Re-implanted right coronary artery to aorta**

**Abdullah Erdem, Zübeyir Kılıç<sup>1</sup>, Ali Rıza Karacı, Celal Akdeniz, Ahmet Çelebi**  
**Department of Pediatric Cardiology, Dr. Siyami Ersek Thoracic and Cardiovascular Surgery Center and Research Hospital, İstanbul,**  
**<sup>1</sup>Department of Pediatric Cardiology, Faculty of Medicine, Eskişehir Osmangazi University, Eskişehir, Turkey**

**Address for Correspondence/Yazışma Adresi:** Dr. Abdullah Erdem, Başakşehir 4. Etap 1. Kısım Blok No: L-5, Daire No:16 Başakşehir, İstanbul, Türkiye  
Phone: +90 216 336 36 40 Fax: +90 216 337 97 19 E-mail: [drabdullaherdem@hotmail.com](mailto:drabdullaherdem@hotmail.com)

©Telif Hakkı 2010 AVES Yayıncılık Ltd. Şti. - Makale metnine [www.anakarder.com](http://www.anakarder.com) web sayfasından ulaşılabilir.  
©Copyright 2010 by AVES Yayıncılık Ltd. - Available on-line at [www.anakarder.com](http://www.anakarder.com)  
doi:10.5152/akd.2010.083

## Pseudoaneurysm of ascending aorta: a rare complication of mediastinitis following coronary artery bypass surgery

*Assandan aortanın psödoanevrizması: Koroner arter baypas cerrahisinden sonra gelişen mediastinitinin nadir bir komplikasyonu*

Postoperative mediastinal infection after open-heart surgery via median sternotomy is a devastating complication. A 58-year-old male patient had mediastinitis in the early postoperative period of coronary artery bypass graft operation because of three vessel coronary artery disease. The sternum was reopened; all necrotic and infected tissues were resected. Then sternum was closed with modified Robicsek technique and pectoralis major muscle flap. Broad-spectrum antibiotic was given according to the antibiogram results of drainage fluid. He did well and discharged 20 days after the second surgery. He delayed his control visits and two months later, he was admitted with pulsating sternum and bleeding over the incision line. Chest X ray and computed tomography (CT) of the chest showed enlargement of upper mediastinum and a huge retrosternal pseudoaneurysm originating from the ascending