

## Endovascular Management of Giant Isolated Iliac Artery Aneurysms: A Case Series

### INTRODUCTION

Isolated iliac artery aneurysms (IIAA) are rarely detected, which compose 2%-7% of all abdominal aneurysmal diseases. The Development of these increases with age and shows the highest incidence in the seventh to eighth decade of life.<sup>1-4</sup> It is seen 7 times more common in men and approximately 30% of these are bilateral. The majority of IIAA involve the common iliac artery (70%) and the internal iliac arteries (20%-25%).<sup>5,6</sup> Due to the difference in embryological origin and resistance to atherosclerotic degeneration, external iliac aneurysms are extremely rare.<sup>3,4</sup> The majority of IIAA are asymptomatic (65%-70%) and typically found incidentally during cross-sectional imaging made for other indications.<sup>7</sup> Large IIAA have a high risk of rupture. This condition is associated with significant morbidity and mortality. While the mortality rate of IIAA is about 11% during elective surgical treatment, this rate approaches to 40%-60% in emergency conditions.<sup>8,9</sup> Although the endovascular treatment was recognized as an alternative to surgical treatment for older patients having comorbidities, in particular, it is also considered the first treatment option for those having appropriate anatomy in recent years. It has been shown to be an effective and safe treatment modality based on medium and long-term results of trials.<sup>8-10</sup>

In this study, we aimed to present giant IIAA cases we encountered in our clinic and to designate the effectiveness of endovascular intervention in the treatment.

### CASE REPORTS

#### Case 1

Our first case was a 67-year-old male with no risk factors other than smoking. In the abdominal ultrasound of the patient presented with abdominal pain, aneurysm with a diameter of 41 mm was detected in the right common iliac artery. In the 6-month follow-up of the case, it was determined that the aneurysm diameter had reached 46 mm, and he was referred to our clinic for endovascular intervention. Due to the rapid increase in the diameter of the aneurysm, endovascular intervention was planned. Informed consent was obtained from the patient before the intervention. The right internal iliac artery in the aneurysm sac was cannulated through the left axillary route and closed with 9/12 Amplatzer Vascular Plug (AVP) II (St. Jude Medical, St. Paul, Minn, USA). The aneurysm sac was completely closed with an Endurant II graft stent (Medtronic Cardiovascular, Santa Rosa, Calif, USA), which was followed by a proximal post dilatation (Figure 1). The procedure was terminated without complications. In the 6-month follow-up, stent patency was maintained and no endoleak or ischemic complications were observed.

#### Case 2

Our second case was an 84-year-old male with a history of hypertension. He was admitted to our emergency outpatient clinic with complaints of pain, coldness, numbness, and bruising in his left leg. Physical examination revealed signs of ischemia in the left foot and mild motor neurologic loss. On computed tomography (CT), an 85 × 75 mm fusiform aneurysm was observed in the left external iliac artery, which was accompanied by a thrombotic occlusion in the popliteal artery. Endovascular intervention was planned. Informed consent was obtained from the

### CASE REPORT

Gönül Zeren<sup>ID</sup>

Fatma Can<sup>ID</sup>

İlhan İlker Avcı<sup>ID</sup>

Mustafa Azmi Sungur<sup>ID</sup>

Mehmet Fatih Yılmaz<sup>ID</sup>

Can Yücel Karabay<sup>ID</sup>

Department of Cardiology, Dr. Siyami Ersek Thoracic and Cardiovascular Surgery Training and Research Hospital, İstanbul, Turkey

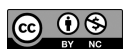#### Corresponding author:

Gönül Zeren

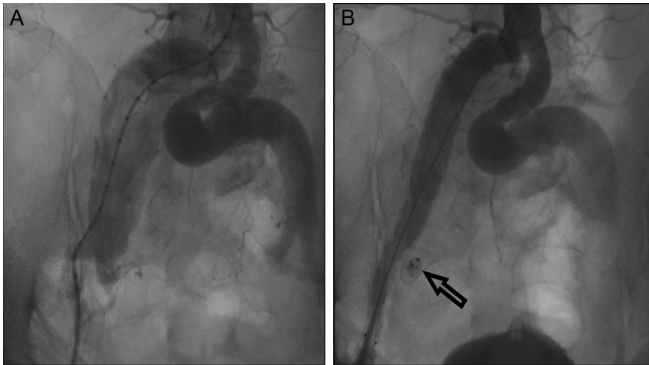
✉ gonulzeren@hotmail.com

**Cite this article as:** Zeren G, Can F, Avcı İ, Sungur MA, Yılmaz MF, Karabay CY. Endovascular management of giant isolated iliac artery aneurysms: A case series. *Anatol J Cardiol.* 2022;26(9):733-736.

DOI:10.5152/AnatolJCardiol.2022.1885



Copyright@Author(s) - Available online at anatoljcardiol.com.  
Content of this journal is licensed under a Creative Commons Attribution-NonCommercial 4.0 International License.



**Figure 1. (A): Image of right isolated iliac artery aneurysm; (B): Image after endovascular treatment, arrow: internal closure with AVP II. AVP, Amplatzer Vascular Plug.**

patient before the intervention. The aneurysm sac was completely closed with an Endurant® II graft stent (Figure 2). In the follow-up of the patient who was also anticoagulated for thrombus, it was observed that ischemic symptoms in the foot regressed and motor loss improved.

### Case 3

While investigating the complaint of leg pain in a 69-year-old male, a 53 × 47 mm diameter, fusiform, giant aneurysm was detected in the right common iliac artery in the CT scan and he was referred to our clinic for endovascular intervention. Endovascular intervention was planned. Informed consent was obtained from the patient before the intervention. In the procedure, right internal iliac artery was cannulated through the left femoral route and closed with 18 mm AVP® II. The aneurysm sac was successfully closed with an Endurant®II graft stent (Figure 3). No endoleak or any complication was observed in the follow-up.

### Case 4

Our last case was an 87-year-old male. Incidentally, a giant aneurysm with a diameter of 5 cm and a length of 6 cm was detected in the right common iliac artery and he was referred to our clinic for endovascular closure. In our case presented without any symptoms, endovascular intervention was planned due to high risk of rupture of the giant aneurysm. Informed consent was obtained from the patient before the intervention. The distance between the aneurysm sac and the bifurcation of the common iliac artery was

less than 1 cm. Due to the lack of neck distance where the graft stent can be placed safely, the bifurcated-graft stent procedure extended from the abdominal aorta to the right iliac artery was deemed appropriate. In the endovascular intervention, the aneurysm sac was successfully closed with a 28/16 mm Endurant® II graft stent after the closure of right internal iliac artery with 14 mm AVP® II, where no complication occurred (Figure 4).

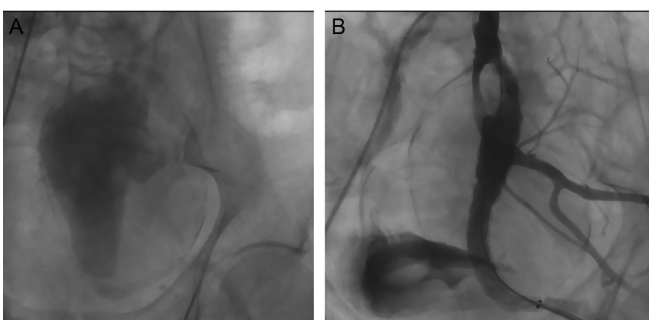
## RESULTS AND FOLLOW-UP

Endovascular intervention was successfully performed in all patients, and no major postoperative complications were developed in any of the patients. The mean hospital stay for all patients was 3 days. Computed tomography angiography at 6 and 12 months showed that all stent grafts were placed properly and stent patency was maintained without any evidence of endograft-related complications (e.g., stent fracture, stent thrombosis). No detectable type 1 or 2 endoleak was observed at the 12<sup>th</sup>-month follow-up.

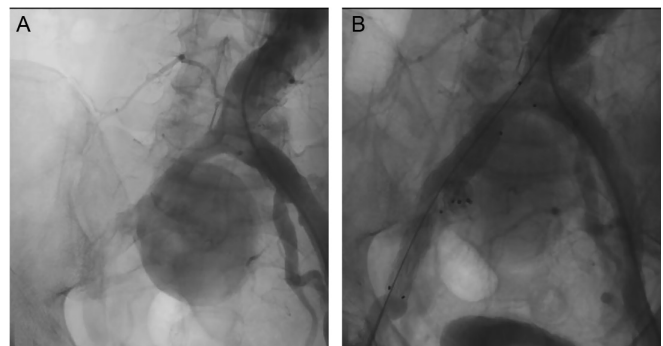
## DISCUSSION

In IIAA cases that have reached giant dimensions at the time of diagnosis, graft stent placement with endovascular intervention is an effective, safe, and appropriate treatment method.

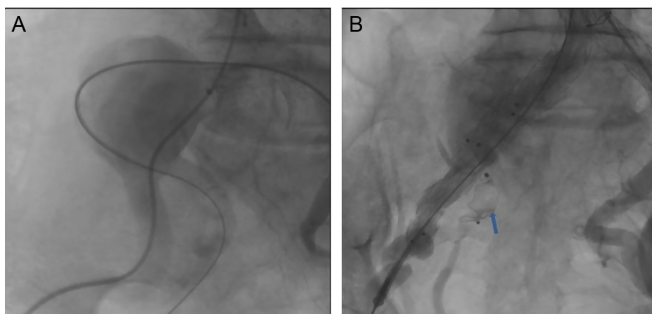
Isolated iliac artery aneurysms are rare and mostly asymptomatic (65%-70%), which are detected incidentally in particular during cross-sectional imaging for other indications.<sup>7</sup> However, as with abdominal aortic aneurysms (AAAs), iliac aneurysms can also cause symptoms due to thrombosis, embolism, rupture, and external compression. Complaints of vague lower abdominal and flank pain are also common.<sup>11-14</sup> Other symptoms include pyelonephritis from the compression of adjacent structures, sepsis from ureteral obstruction, pain during defecation from rectal compression, hip pain, and lower extremity paresthesia from the compression of the pelvic nerves.<sup>13-16</sup> Since these symptoms are not considered to be directly related to the vascular system, the diagnosis is usually delayed. Though IIAAs are quite harmless apart from their natural progress, they carry a significant risk of rupture when they reach a large size. Rupture is associated with significant morbidity and mortality, and thus, its early diagnosis and treatment remain of crucial



**Figure 2. Giant left-isolated iliac artery aneurysm. (A): Image of pre-endovascular treatment; (B): Image of post-endovascular treatment.**



**Figure 3. Giant right common iliac artery aneurysm on angiography. (A): Image of pre-endovascular treatment; (B): Image of post-endovascular treatment.**



**Figure 4. Giant right-isolated iliac artery aneurysm on angiography. (A): Image of pre-endovascular treatment; (B): Image of post-endovascular treatment, arrow: internal closure with AVP II. AVP, Amplatzer Vascular Plug.**

importance. Aneurysms were detected incidentally in 2 of our cases, thrombosis and ischemic symptoms developed in 1 of the other 2, and the other presented with leg pain.

Although the progression of aortic aneurysms is well known, there are no large-scale prospective studies on the progression of iliac aneurysms. While dilation rates reported in iliac aneurysms were slower under 3 cm of diameter (1.1 mm/year), they are similar to those of AAAs in the case of 3–5 cm of diameter and demonstrate significantly higher values (2.6 mm/year).<sup>12</sup> The mean aneurysm size at the time of detection is 5–6 cm. As with aortic aneurysms, diameter appears to be the most important determinant of rupture. No univocal consensus has been reported on the diameter threshold for treatment. Some authors have reported a growth rate of 4 mm/year and have recommended treatment when the diameter exceeds 30 mm. Other authors have suggested 35 mm as the threshold,<sup>7,15,16</sup> especially symptomatic IIAAs and IIAAs greater than 5 cm in diameter should be repaired immediately. Aneurysm diameter was found to be 46 mm in our first case, while giant aneurysms were detected in the other 3 cases.

Surgical treatment may be difficult due to their deep pelvic localization. While the mortality rate in elective surgery is around 11%, it approaches 40%–60% in emergency conditions.<sup>17,18</sup> The 30-day mortality and complication rate reaches 10% and 16%, respectively.<sup>4</sup> In recent years, interventional endovascular treatment options have become an alternative to open surgical repair. Although it is considered at the forefront in particular for the elderly and patients with comorbidities, endovascular treatment is also considered the first treatment option in patients with appropriate iliac anatomy (presence of proximal and distal neck, absence of folds and adequate diameters).<sup>16</sup> High success rates of endovascular treatment have been reported in the literature.<sup>9,10</sup> It has been shown with medium and long-term results that it is an effective and safe option. In elective endovascular therapy, perioperative mortality is less than 2% and perioperative morbidity is around 20%.<sup>4,19</sup> When endovascular treatment is compared with open surgery, it seems to provide an advantage in terms of mortality and morbidity in the early period. Its performance under local anesthesia in most cases prevents complications such as respiratory tract complications

and myocardial infarction associated with general anesthesia. In addition, the percutaneous transfemoral approach prevents the morbidity associated with transperitoneal and retroperitoneal approaches and ultimately reduces the length of hospital stay. All of our IIAA cases were repaired endovascularly. The average length of stay was 3 days. In the literature, endoleak rates are similar to AAAs and it was not observed in our patients' 6-month follow-up.

## CONCLUSION

Endovascular treatment is an effective, safe, and appropriate treatment option in IIAA, which is rare and reaches gigantic dimensions until it reaches the symptomatic stage.

**Informed Consent:** Written informed consent was obtained from the patients.

## REFERENCES

- Nachbur BH, Inderbitzi RG, Bär W. Isolated iliac aneuysms. *Eur J Vasc Surg.* 1991;5(4):375-381. [\[CrossRef\]](#)
- Richardson JW, Greenfield LJ. Natural history and management of iliac aneurysms. *J Vasc Surg.* 1988;8(2):165-171.
- McCready RA, Pairolero PC, Gilmore JC, Kazmier FJ, Cherry KJ Jr, Hollier LH. Isolated iliac artery aneurysms. *Surgery.* 1983;93(5):688-693.
- Sandhu RS, Pipinos II. Isolated iliac artery aneurysms. *Semin Vasc Surg.* 2005;18(4):209-215. [\[CrossRef\]](#)
- Wolf F, Loewe C, Cejna M, et al. Endovascular management performed percutaneously of isolated iliac artery aneurysms. *Eur J Radiol.* 2008;65(3):491-497. [\[CrossRef\]](#)
- Hiromatsu S, Hosokawa Y, Egawa N, Yokokura H, Akaiwa K, Aoyagi S. Strategy for isolated iliac artery aneurysms. *Asian Cardiovasc Thorac Ann.* 2007;15(4):280-284. [\[CrossRef\]](#)
- Uberoi R, Tsetis D, Shrivastava V, Morgan R, Belli AM, Subcommittee on Reporting Standards for Arterial Aneurysms of The Society for Vascular Surgery. Standard of practice for the interventional management of isolated iliac artery aneurysms. *Cardiovasc Intervent Radiol.* 2011;34(1):3-13. [\[CrossRef\]](#)
- Patel NV, Long GW, Cheema ZF, Rimar K, Brown OW, Shanley CJ. Open vs. endovascular repair of isolated iliac artery aneurysms: a 12-year experience. *J Vasc Surg.* 2009;49(5):1147-1153. [\[CrossRef\]](#)
- Bianchini Massoni CB, Freyrie A, Gargiulo M, et al. Perioperative and late outcomes after endovascular treatment for isolated iliac artery aneurysms. *Ann Vasc Surg.* 2017;44:83-93. [\[CrossRef\]](#)
- Power AH, Rapanos T, Moore R, Cina CS. Anaconda Endovascular Limbs for the treatment of isolated iliac artery aneurysms. *Vascular.* 2009;17(1):23-28. [\[CrossRef\]](#)
- Guru KA, Sarle RC, Reddy D, Peabody JO. Iliac artery aneurysm: a fatal cause of urinary retention. *J Endourol.* 2003;17(4):221-222. [\[CrossRef\]](#)
- Metcalfe MJ, Hanna MS, Gill S, Burfitt NJ, Mitchell AW, Franklin IJ. Hydronephrosis after embolization of internal iliac artery aneurysms. *J Vasc Interv Radiol.* 2010;21(4):571-573. [\[CrossRef\]](#)
- Wu C, Nguyen BD, Regan F. An internal iliac artery aneurysm masquerading as a rectal mass. *Clin Radiol.* 2000;55(4):319-320. [\[CrossRef\]](#)
- Jaz S, Geroulakos G. Ruptured internal iliac artery aneurysm mimicking a hip fracture. *Int Angiol.* 2001;20(2):1187-1189.
- Santilli SM, Wernsing SE, Lee ES. Expansion rates and outcomes for iliac artery aneurysms. *J Vasc Surg.* 2000;31(1 Pt 1):114-121. [\[CrossRef\]](#)

16. Wanhainen A, Verzini F, Van Herzele I, et al. Editor's choice-European Society for Vascular Surgery (ESVS) 2019 clinical practice guidelines on the management of abdominal aorto-iliac artery aneurysms. *Eur J Vasc Endovasc Surg.* 2019;57(1):8-93. [\[CrossRef\]](#)
17. Chaer RA, Barbato JE, Lin SC, Zenati M, Kent KC, McKinsey JF. Isolated iliac artery aneurysms: a contemporary comparison of endovascular and open repair. *J Vasc Surg.* 2008;47(4):708-713. [\[CrossRef\]](#)
18. Dorigo W, Pulli R, Troisi N, et al. The treatment of isolated iliac artery aneurysm in patients with non-aneurysmal aorta. *Eur J Vasc Endovasc Surg.* 2008;35(5):585-589. [\[CrossRef\]](#)
19. Edwards JM, Teefey SA, Zierler RE, Kohler TR. Intraabdominal paraanastomotic aneurysms after aortic bypass grafting. *J Vasc Surg.* 1992;15(2):344-50; discussion 351. [\[CrossRef\]](#)