

## A surgical salvage case with active endocarditis and aortic coarctation

### *Aktif endokarditli aort koarktasyonlu olguda kurtarıcı cerrahi girişim*

*Ahmet Şaşmazel, Atıf Akçevin\*, Halil Türkoğlu\*, Cihangir Ersoy\*, Tijen Alkan\*,  
Tufan Parker\*, Vedat Bayer\*, Aydın Aytaç\**

Department of Cardiovascular Surgery, Anadolu Health Center, Gebze, İzmit, Turkey

\*Department of Cardiovascular Surgery, VKV American Hospital, İstanbul, Turkey

There is little information concerning patients with active native valve endocarditis and the aortic coarctation. We report our experience of valve replacement with active valve endocarditis and extensive aortic surgery in a 23 years old man.

He was admitted to our hospital with complaints of headache, fever (39.5 C $\infty$ ), sweating, weakness and coughing. Physical examination revealed heart rate 102 beat/min, blood pressure 130/60 mmHg in his upper extremities and 80 mmHg in the lower extremities, conjunctival and splinter hemorrhages, Osler nodules. Cardiac examination showed grade 3/6 holosystolic murmur at the lower sternal border, which radiated to the axilla, and grade 4/6 early diastolic murmur at the upper left sternal border. The first control echocardiography demonstrated aortic insufficiency (+3), mitral insufficiency (+1) and 1.5cm in diameter vegetation on the mitral anterior leaflet. Intravenous blind antibiotic therapy was commenced with penicillin and gentamycin. Two strains of Meticillin sensitive Staphylococcus Aureus were isolated from blood cultures. Thereafter, Vancomycin was added. Despite treatment with appropriate antibiotics he remained pyrexial and 17 days after the admission to the hospital his general condition worsened. On that day second control echocardiography revealed perforation of mitral anterior leaflet (Fig. 1) and grossly dilated, poorly contracting left ventricle. Urgently, he had been transferred to surgery as a salvage case. A concomitant operation was planned for left thoracotomy for aortic coarctation and median split for open heart surgery. Through the left thoracotomy incision, the coarcted segment of aorta was resected and a 16-mm vascular graft was interposed. Thereafter, the aortic and the mitral valves were replaced with mechanical prosthesis through median sternotomy approach,. Dilated ascending aorta was replaced with supracoronary positioned 28mm vascular graft. Uneventful recovery was seen on his postoperative course.

There is still no consensus on whether a one-stage or a two-stage approach should be used. Mulay and associates preferred to use a two-stage procedure (1). Firstly, the intracardiac le-

sion restored thereafter aortic coarctation was repaired. Their clarification for this approach was to prevent the sudden decrease in systemic vascular resistance. Regrettably, Mulay and associates do not pointed out left ventricular function at time of the operation and the weaning of patients from cardiopulmonary bypass with the poor left ventricular function (1). For this type of cases our approach is to relief the aortic coarctation first. Thereafter, the intracardiac procedure can be performed. As a result, compromised left ventricular functions and weaning from the extracorporeal circulation can be achieved by off-loading left ventricle before. In this esteem, in the presence of compromised left ventricular function we accept as true that the aortic coarctation should be dealt with first.

### References

1. Mulay AV, Ashraf S, Watterson KG. Two-stage repair of adult coarctation of the aorta with congenital valvular lesions. Ann Thorac Surg 1997; 64: 1309-11.

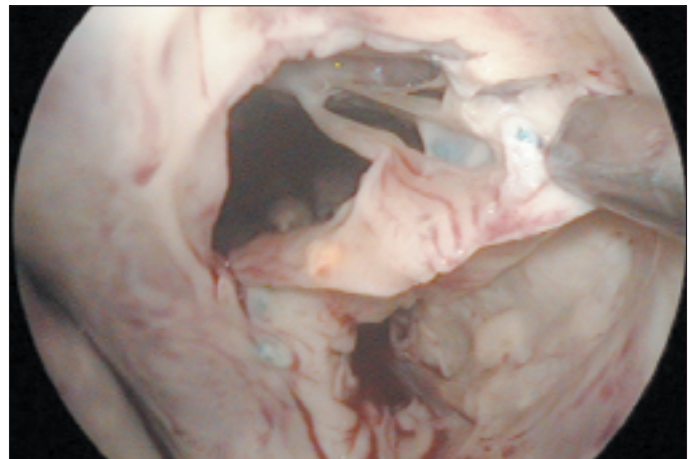


Figure 1. Mitral valve with endocarditis