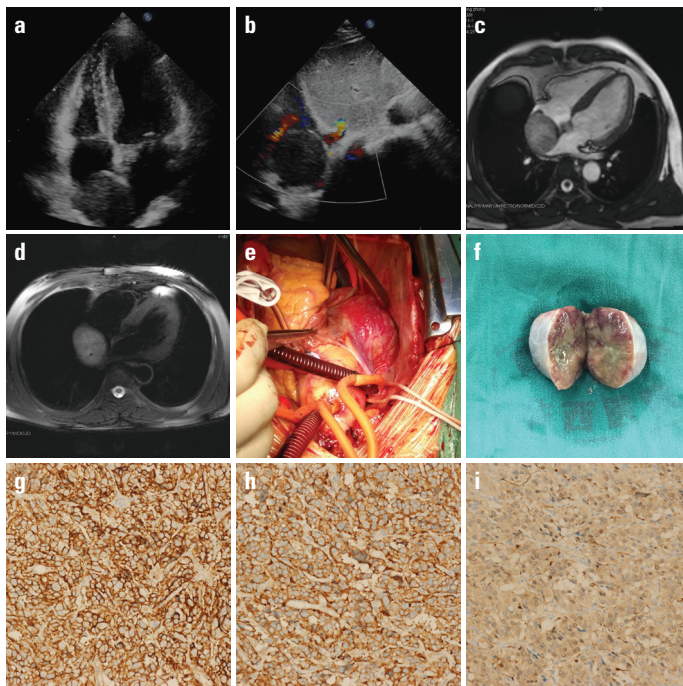


## Functional paraganglioma in the right atrium

A 39-year-old male presented to our clinic because of nocturnal intermittent palpitation for 2 years. His medical history showed a high blood pressure of 200/100 mm Hg. Transthoracic echocardiography revealed a 54×46-mm mass in the right atrium (Figure 1a, 1b). In addition, cardiac magnetic resonance imaging confirmed the tumor and highly suggested it to be a malignant tumor (Figure 1c, 1d). An almost 50-fold increase in the blood catecholamine metabolites was detected. Further, positron emission tomography/computed tomography found no other tumor. Given the symptoms and the functional intra-atrial tumor, surgical removal was agreed by our surgical team and the family. During the surgery, we found that the tumor had invaded into the right atrial wall and inter-atrial septum (Figure 1e, 1f). Following the complete removal of the tumor, we reconstructed the right atrium and inter-atrial septum with bovine pericardium. Intraoperative echocardiography showed no shunt between the atria and reflow of the pulmonary veins were clear. Pathological analysis revealed the tumor to be a paraganglioma with negative CK and EMA expressions and positive CD56, Syn, and S-100 expressions



**Figure 1.** Transthoracic echocardiography images showed a tumor in the right atrium (a, b). Cardiac magnetic resonance imaging showed an equal T1 and long T2 signal shadow in the right atrium, which was suspected as a malignant tumor (c, d). Intraoperative images and the gross anatomy of the tumor (e, f). Immunohistochemical study of the tumor for CD56 expression (g). Immunohistochemical study of the tumor for Syn expression (h). Immunohistochemical study of the tumor for S-100 expression (i)

(Figure 1g–1i). The patient fully recovered and was discharged on postoperative day 7 with a normal blood pressure. At the 6-month follow-up, the patient was still free of symptoms and catecholamine metabolites were normal. Intra-atrial paraganglioma is an extremely rare and functional primary cardiac neoplasm, and our experience suggests multimodality evaluations and complete surgical removal be performed.

Jingxiu Fan<sup>#</sup>, Zhong Wu<sup>#</sup>, Yan Kang<sup>1</sup>

Departments of Cardiovascular Surgery, and <sup>1</sup>Department of Critical Care Medicine, West China Hospital/West China School of Medicine, Sichuan University; Chengdu-*People's Republic of China*

<sup>#</sup>These authors contribute equally to this article.

**Address for Correspondence:** Yan Kang, M.D.

Department of Critical Care Medicine, West China Hospital/West China School of Medicine, Sichuan University, Chengdu 610041, *People's Republic of China*.

Address: Guo Xue Alley 37, Chengdu, Sichuan, *People's Republic of China*, 610041

Phone: +86 028 85422234

E-mail: kang\_yan\_123@163.com

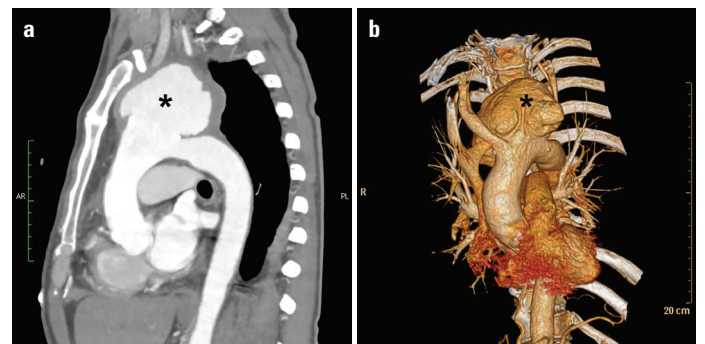
©Copyright 2018 by Turkish Society of Cardiology - Available online

at [www.anatoljcardiol.com](http://www.anatoljcardiol.com)

DOI:10.14744/AnatolJCardiol.2017.8241

## Spontaneous giant pseudoaneurysm in the upper segment of the aortic arch

A 57-year-old male patient was referred to the Department of Emergency with a chief complaint of a 2-month history of back pain and short of breath for 1 day. Meanwhile, he developed hypertension 1 month ago that was not treated. The patient denied any history of trauma, operation, allergy, any types of hepatitis, or other potential infectious diseases. Thoracic computed tomography angiography on admission indicated a giant pseudoaneurysm in the upper segment of the aortic arch with a maximum



**Figure 1.** (a) Thoracic computed tomography angiography (CTA) showed a giant pseudoaneurysm in the initiating part of the upper segment of the aortic arch. (b) Three-dimensional reconstruction thoracic CTA showed a close relationship between the aneurysm and the three main branches from the aortic arch