

stenosis, mild mitral regurgitation, MVA was calculated as 1.2 cm<sup>2</sup> with planimetry and 1.35 cm<sup>2</sup> with Doppler. The maximum and mean gradients across the mitral valve were 19 and 11 mmHg respectively. TEE revealed a thrombus at LAA base, not protruding into LA and measured as 1.2x1.5 cm. The Wilkins valve score was calculated as 9 (Fig. 3). The patient refused to undergo open-heart surgery for mitral valve replacement. Based on the success of the previous case, and the same type of thrombus, which was restricted to the base of the LAA, PMBV was offered and the risk of the procedure was explained in detail. PMBV was performed with the help of TTE. After completion of the procedure without any complication, echocardiographic parameters were as follows, MVA was 1.7cm<sup>2</sup>, systolic PAP was 35 mmHg, maximum and mean gradients across the valve were 10 mmHg and 5 mmHg respectively.

## Discussion

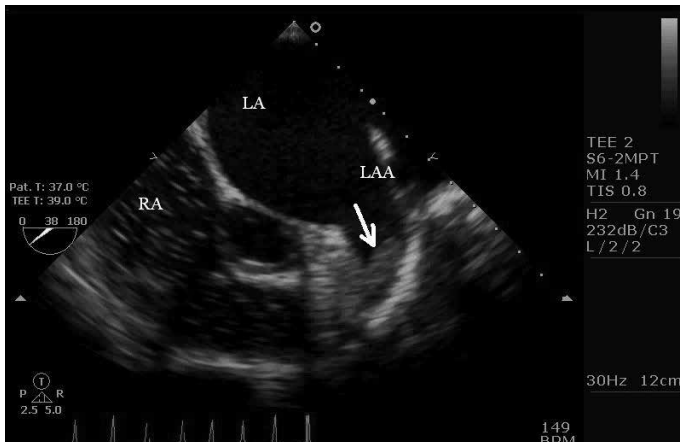
PBMV is the treatment of choice for patients with rheumatic mitral stenosis and suitable valve anatomy. Stroke was one of the catastrophic complications of PBMV. While ACC/AHA guidelines emphasizes LA thrombus as a contraindication for PBMV (level of evidence C), there is no solid evidence for cases with left atrial appendage thrombus (3).

Some operators do not consider LAA thrombus as an absolute contraindication (4).

Koca et al. (5) performed PBMV to nine patients with symptomatic mitral stenosis and thrombus restricted to the LAA. These procedures were performed under TEE guidance and there were no thromboembolic events. Consequently, researchers concluded that in selected cases, PBMV under TEE guidance was safe and thrombus restricted to the LAA is not an absolute contraindication to the procedure.

The most comprehensive research about this comes from small scale trials comprising 28 and 30 patients. Manjunath et al. (4) performed PBMV to 30 patients with LAA thrombus and observed no systemic thromboembolic event. In this study, Manjunath et al. (4) grouped LA thrombus into five subtypes. In patients with type 1a (LAA thrombus confined to appendage), type 1b (LA appendage thrombus protruding into LA cavity) and type 2a (LA roof thrombus limited to a plane above the plane of fossa ovalis) thrombus, PBMV was considered as safe and effective with modified techniques. Shaw et al. (6) performed PBMV to 28 patients with LAA thrombus and none of the patients experienced embolic event.

Our patients had type 1a thrombus according to the classification denoted by Manjunath et al. (4). The procedures were performed with lower septal puncture and with less manipulation. Contrary to previous researchers, we used TTE.



**Figure 3.** Transesophageal echocardiography shows LAA thrombus at mid-esophageal aortic valve short-axis view (Case 2). Arrow-thrombus in LAA

LA - left atrium, LAA - left atrial appendage, RA - right atrium

## Conclusion

PBMV is a safe option for patients with suitable valve anatomy and thrombus localized to LAA. Systemic thromboembolism is rare if performed by an experienced operator. TTE seems as a safe and effective alternative to TEE.

**Hakan Akıllı, Alpay Arıbaş, Gökhan Altunbaş, Kurtuluş Özdemir**  
Department of Cardiology, Necmettin Erbakan University, Meram  
Faculty of Medicine, Konya-Turkey

## References

1. Inoue K, Owaki T, Nakamura T, Kitamura F, Miyamoto N. Clinical application of transvenous mitral commissurotomy by a new balloon catheter. J Thorac Cardiovasc Surg 1984; 87: 394-402.
2. Tessier P, Mercier LA, Burelle D, Bonan R. Results of percutaneous mitral commissurotomy in patients with a left atrial appendage thrombus detected by transesophageal echocardiography. J Am Soc Echocardiogr 1994; 7: 394-9.
3. Bonow RO, Carabello BA, Chatterjee K, de Leon AC Jr, Faxon DP, Freed MD, et al. 2008 focused update incorporated into the ACC/AHA 2006 guidelines for the management of patients with valvular heart disease: a report of the American College of Cardiology/American Heart Association Task Force on Practice Guidelines (Writing Committee to revise the 1998 guidelines for the management of patients with valvular heart disease). Endorsed by the Society of Cardiovascular Anesthesiologists, Society for Cardiovascular Angiography and Interventions, and Society of Thoracic Surgeons. J Am Coll Cardiol 2008; 52: e1-142. [CrossRef]
4. Manjunath CN, Srinivasa KH, Ravindranath KS, Manohar JS, Prabhavathi B, Dattatreya PV, et al. Balloon mitral valvotomy in patients with mitral stenosis and left atrial thrombus. Catheter Cardiovasc Interv 2009; 74: 653-61. [CrossRef]
5. Koca V, Bozat T, Yavuz Ş, Özdemir A. Sol atriyal apendiks trombüsü olan romatizmal mitral darlığı olgularında perkütan mitral balon valvülotomi. Turk Kardiyol Dern Arş 2000; 28: 302-5.
6. Shaw TR, Northridge DB, Sutaria N. Mitral balloon valvotomy and left atrial thrombus. Heart 2005; 91: 1088-9. [CrossRef]

**Address for Correspondence/Yazışma Adresi:** Dr. Hakan Akıllı  
Necmettin Erbakan Üniversitesi Meram Tıp Fakültesi, Kardiyoloji  
Sekreterliği, Meram, 42090 Konya-Türkiye  
Phone: +90 332 223 79 41 Fax: +90 332 223 68 81  
E-mail: hakanakilli@hotmail.com

**Available Online Date/Çevrimiçi Yayın Tarihi:** 05.11.2012

©Telif Hakkı 2013 AVES Yayıncılık Ltd. Şti. - Makale metnine www.anakarder.com web sayfasından ulaşılabilir.

©Copyright 2013 by AVES Yayıncılık Ltd. - Available on-line at www.anakarder.com doi:10.5152/akd.2013.011



## The role of two-dimensional speckle-tracking echocardiography in a patient with Behçet's disease

*Behçet hastalığı olan hastada iki boyutlu benek takip yöntemi ekokardiyografinin önemi*

## Introduction

Behçet's disease (BD) is a systemic inflammatory disorder of unknown origin characterized by variable clinical manifestations. Most

common forms of clinical presentation are recurrent oral and genital aphthous ulceration, uveitis and erythema nodosum (1). Cardiac involvement is relatively uncommon (2) and may present in the form of pericarditis, conduction system disturbances, coronary arteritis, intracavitary thrombosis, endomyocardial fibrosis or valvular insufficiency (3). We reported a case of 24-year-old man with right ventricular thrombus and endomyocardial fibrosis diagnosed with BD during routine echocardiography examination.

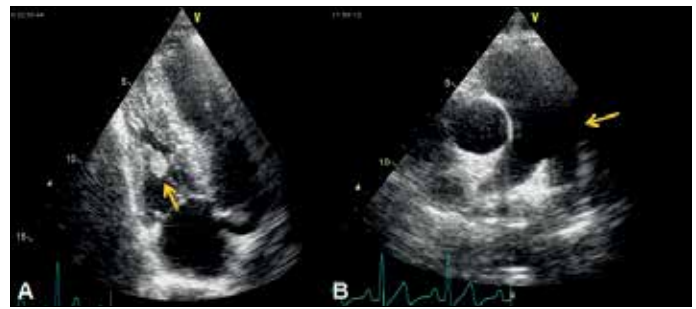## Case Report

A 24-year-old man, with a family history of sudden cardiac death of a brother at age of 26, was referred to our institution for cardiovascular investigation. He had no complained on admission. He was not a smoker. Past medical history was unenlightening except recurrent aphthous stomatitis and tonsillitis. Clinical examination detected 2/6 mid-systolic murmur over the left second space. He was a febrile and his blood pressure was 110/76 mmHg with a heart rate of 95. A pedunculated homogenous mass (16x20 mm) mobile with tricuspid valve suspected to be a thrombus in the right ventricle (RV) and increased thickness and echogenicity (Fig. 1A, Video 1. See corresponding video/movie images at [www.anakarder.com](http://www.anakarder.com)) of right ventricular free wall and slightly dilated main pulmonary artery (3.2 cm) with normal estimated pulmonary artery pressure (Fig. 1B) were found on echocardiographic examination. Speckle tracking echocardiographic evaluation of right ventricular free wall revealed decreased regional longitudinal strain value of -10 (Fig. 2) (4). CT pulmonary angiography pointed out pulmonary arterial aneurysms. Coagulation studies and immune indexes including lupus anticoagulant were normal. Serologic investigation did not yield any evidence of bacterial or fungal infections. On further investigation, genital aphthous ulcerations, positive pathergy test and positive human leukocyte antigen B51 (HLA-B51) serologic typing were detected. According to international study group criteria for BD (5), he was diagnosed with BD. Bright echoes, increased thickness and decreased longitudinal strain and strain rate in the right ventricular free wall were thought to be result of endomyofibrosis secondary to BD. A regimen of pulse methylprednisolone and monthly intravenous cyclophosphamide infusion combined with oral colchicines was initiated. Concomitantly, we started unfractionated heparin infusion and activated partial thromboplastin time was maintained 1.5 to 2.5 times the control value. After two weeks of therapy, there was complete resolution of right ventricular thrombus on echocardiography. At 3 months' follow-up, he was doing well on the same therapy.

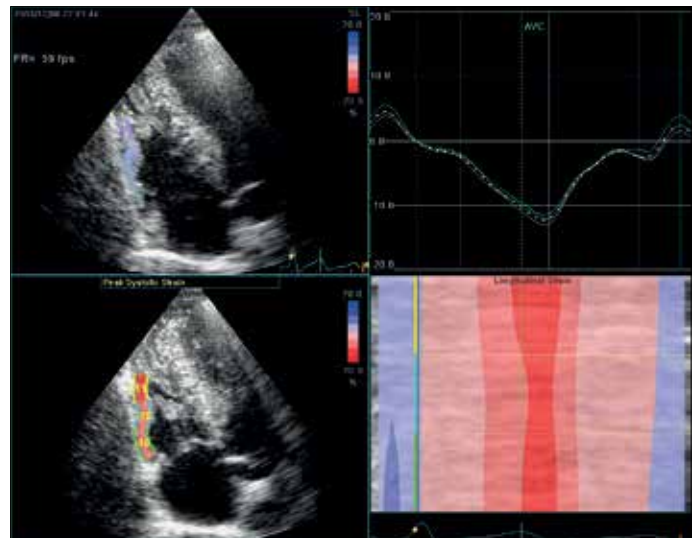
## Discussion

Behcet's disease, currently classified as a vasculitis, is a systemic inflammatory disorder first described in 1937 as a triple symptom complex of aphthae, genital ulcers, and hypopyon uveitis (6). Although mucocutaneous features such as recurrent oral ulceration are the most common presenting symptoms, BD lacks pathognomonic clinical or laboratorial findings and the diagnosis is made on the basis of a group of clinical features.

Cardiac involvement of BD is uncommon and found in 7-46% of the patients in clinical series (3). BD usually involves the right side of the heart. Endomyocardial fibrosis is a sequel of vasculitis that involves the endocardium, myocardium, or both, and has a tendency toward bacterial endocarditis or intraventricular thrombosis. It is seen as diffuse, bright, thickened endocardium on echocardiography and can cause segmental wall motion abnormalities. Two-dimensional speckle tracking echocardiography (STE) allows the study of regional myocardial deformation expressed by strain and strain rate. Subtle cardiac involvement



**Figure 1. A) A mobile pedunculated, homogeneous mass in the right ventricle (arrow) B) - Parasternal short -axis view showing dilated main pulmonary artery (arrow)**



**Figure 2. Two-dimensional speckle tracking echocardiography revealing decreased right ventricular free wall longitudinal strain values**

of various diseases can be detected by STE reliably. Moreover, it has been proven that; peak regional longitudinal strain and strain rate values are significantly lower in fibrotic areas than normal myocardium (7).

Decreased strain and strain rate values are clues to myocardial or endomyocardial involvement of the disease process. Yağmur et al. (8) have proven that left ventricular longitudinal systolic strain is significantly impaired and NT-proBNP is increased in correlation with mean left ventricular longitudinal strain in patients with BD compared with the healthy controls.

## Conclusion

Speckle tracking echocardiography, a novel non-invasive method, can be used for the assessment of subclinical right ventricular dysfunction in BD. Further clinical studies are needed to define the eventual role of STE in the determination of RV functions in BD.

**Regayip Zehir, Can Yücel Karabay, Ahmet Çağrı Aykan,  
Mehmet Özkan**

**From Clinic of Cardiology, Kartal Koşuyolu Heart and Research  
Hospital, İstanbul-Turkey**

**Video 1.** Views of a pedunculated homogenous mass (16x20 mm) mobile with tricuspid valve suspected to be a thrombus in the right ventricle (RV) with increased thickness and echogenicity

## References

1. Yazıcı H, Fresko I, Yurdakul S. Behçet's syndrome: disease manifestations, management, and advances in treatment. *Nat Clin Pract Rheumatol* 2007; 3: 148-55. [CrossRef]
2. Özkan M, Emel O, Özdemir M, Yurdakul S, Koçak H, Özdoğan H, et al. M-mode, 2-D and Doppler echocardiographic study in 65 patients with Behçet's syndrome. *Eur Heart J* 1992; 13: 638-41.
3. Gürgün C, Ercan E, Ceyhan C, Yavuzgil O, Zoghi M, Aksu K, et al. Cardiovascular involvement in Behçet's disease. *Jpn Heart J* 2002; 43: 389-98. [CrossRef]
4. Meris A, Faletta F, Conca C, Klersy C, Regoli F, Klimusina J. Timing and magnitude of regional right ventricular function: a speckle tracking-derived strain study of normal subjects and patients with right ventricular dysfunction. *J Am Soc Echocardiogr* 2010; 23: 823-31. [CrossRef]
5. Criteria for diagnosis of Behçet's disease. International Study Group for Behçet's Disease. *Lancet* 1990; 335: 1078-80.
6. Behçet H. Über rezidivierende, aphthöse, durch ein Virus verursachte Geschwüre am Munde, am Auge und an den Genitalien. *Dermatologische Wochenschrift* 1937; 36: 1152-7.
7. Mondillo S, Galderisi M, Mele D, Cameli M, Lomoriello VS, Zacà V, et al. Speckle-tracking echocardiography: a new technique for assessing myocardial function. *J Ultrasound Med* 2011; 30: 71-83.
8. Yağmur J, Şener S, Açıkgöz N, Cansel M, Ermiş N, Karıncaoğlu Y. Subclinical left ventricular dysfunction in Behçet's disease assessed by two-dimensional speckle tracking echocardiography. *Eur J Echocardiogr* 2011; 12: 536-41. [CrossRef]

**Address for Correspondence/Yazışma Adresi:** Dr. Can Yücel Karabay Kartal Koşuyolu Eğitim ve Araştırma Hastanesi, Kardiyoloji Kliniği, 34846, Kartal, İstanbul-Türkiye  
Phone: +90 216 459 40 41 Fax: +90 216 459 63 21  
E-mail: karabaymd@yahoo.com



**Available Online Date/Çevrimiçi Yayın Tarihi:** 05.11.2012

©Telif Hakkı 2013 AVES Yayıncılık Ltd. Şti. - Makale metnine [www.anakarder.com](http://www.anakarder.com) web sayfasından ulaşılabilir.

©Copyright 2013 by AVES Yayıncılık Ltd. - Available on-line at [www.anakarder.com](http://www.anakarder.com)  
doi:10.5152/akd.2013.012

## Aneurysm of ascending and descending aorta in a 10-year-old-boy with Wiskott-Aldrich syndrome

*Wiskott-Aldrich sendromlu 10 yaşındaki erkek çocukta çıkan ve inen aortada anevrizmatik dilatasyon*

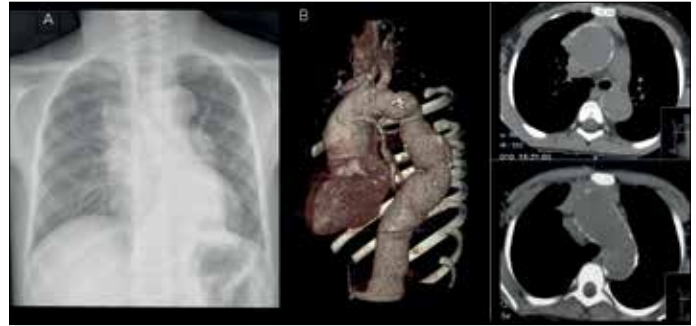
### Introduction

Wiskott-Aldrich Syndrome (WAS) is a recessive genetic disorder linked to the X-chromosome characterized by immune deficiency, eczema and thrombocytopenia. To the best of our knowledge, a few cases of vasculitis or aneurysmal formation have been reported in this syndrome, but the association has not been well established (1-6). We report a patient with WAS and extensive aortitis causing severe aneurysmal dilatation in the everywhere of the aorta who underwent successful first stage operation involving replacement of ascending aorta.

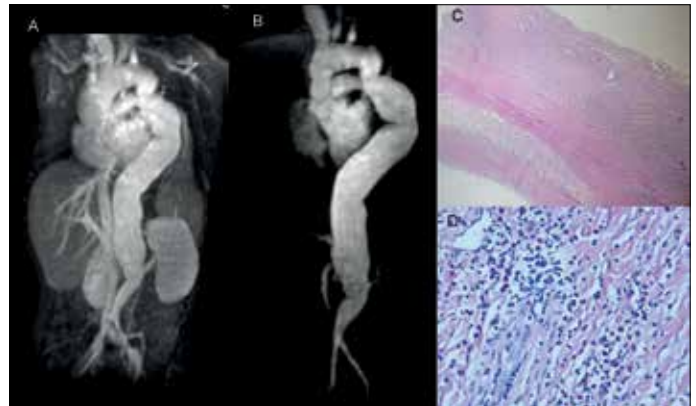
### Case Report

A 10-year-old boy had been followed up with the diagnosis of chronic idiopathic thrombocytopenic purpura (ITP) for 2 years. There

was no history of eczema and repeating infections suggesting immunodeficiency. Because of persistent caught in the last two months, chest X-ray was performed and it suggested an ascending aortic aneurysm (Fig. 1). Echocardiography showed mild aortic regurgitation without aortic stenosis and aneurysmatic dilatation of ascending and descending aorta. 3D computed tomography revealed dilatation of the ascending, descending and abdominal aorta with extreme calcification and plaque (Fig. 1). He had two maternal cousins with the diagnosis of WAS. One of them had died with septicemia after splenectomy. There was no history of aneurysm in his cousins. Flow cytometry showed absence of WAS protein. We planned two-stage operation beginning with replacement of the ascending aorta due to high risk of rupture. Pulse methylprednisolone therapy (30 mg/kg/day for 3 days) was tried to correct the thrombocytopenia prior to cardiac surgery. The platelet count increased from 45.000 to 103.000/mm<sup>3</sup>. 0.5 gr/kg IVIG was administered monthly. Apheresis thrombocytes were also given before the operation. He underwent valve sparing surgery. Vascutek® graft (24 mm) was replaced to aortic root and ascending aorta (Fig. 2). The luminal surface of the aorta was found to be covered by ulcerated and calcified necrotic plaques. Postoperative recovery was uneventful and no excessive



**Figure 1.** A) Preoperative roentgenogram shows the dilated thoracic aorta; B) Reconstructed three-dimensional computed tomography shows significant dilatation of the ascending, descending and abdominal aorta with calcification and plaque and transverse computed tomographic image demonstrates the dilated ascending and descending aorta with medial calcification



**Figure 2.** A) Preoperative MRI showing dilatation throughout the whole aorta; from the aortic root to the iliac bifurcation (the diameter at the ascending thoracic aorta was 47.5 mm, aortic arch 31 mm, descending thoracic aorta 38 mm and abdominal aorta 36 mm); B) Postoperative MRI revealed a satisfactory repair of the aneurysm of ascending aorta; C) Degenerating changes, inflammation and hyalinization in the full thickness of the aorta (HEX40); D) Mixed inflammatory inflammation with eosinophil leucocytes (HEX200)

MRI - magnetic resonance imaging