

## Rectus sheath hematoma due to cough attacks in an elderly patient on oral anticoagulant therapy

*Oral antikoagulan kullanan yaşlı bir hastada öksürük ataklarına bağlı gelişen rektus kası hematomu*

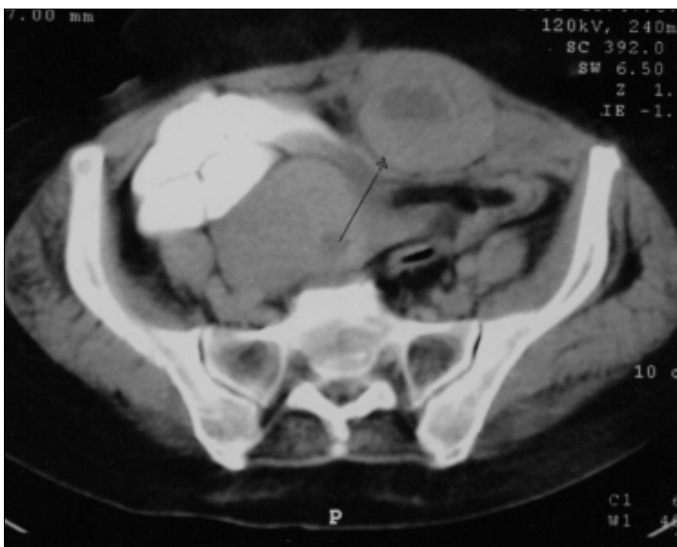
*Ercan Varol, Mehmet Özyaydın\**

Department of Cardiology, Isparta State Hospital, Isparta

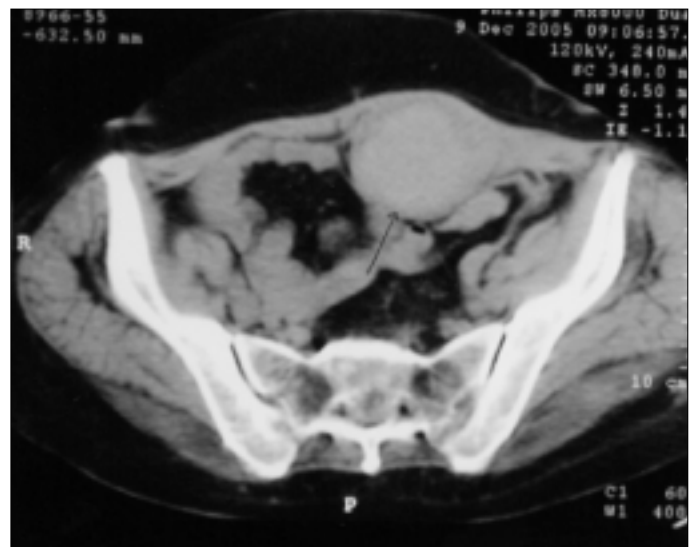
\* Department of Cardiology, Medical Faculty, Suleyman Demirel University, Isparta, Turkey

A 61-year-old woman with mitral regurgitation and atrial fibrillation was hospitalized due to palpitation, severe cough attacks and sputum with an early diagnosis of acute bronchial infection. She was taking digoxin, furosemide, and warfarin for prevention of thromboembolic events. The blood pressure was 110/80 mmHg. The heart rate was 98 beats/min and irregularly irregular. There was an apical systolic murmur on cardiac examination and there were rales and ronchi in the left lower lung area. Laboratory testing revealed the following values: glucose - 145 mg/dl, hemoglobin - 11.4 mg/dl, thrombocyte-224000/mm<sup>3</sup> and INR - 2.8. A sudden, severe abdominal pain and infraumbilical solid sensitive mass developed in the patient on the third day of antibiotic treatment. The leukocyte count was normal and the hemoglobin level decreased to 9 g/dl. Ultrasound examination and computed tomography were

performed with the proposal of general surgery department. A 5x5.5x9 cm hematoma in the left rectus abdominis muscle was detected in computed tomography (Fig. 1). Medical pursuit has been proposed by general surgery department. Anticoagulant treatment was stopped immediately, one unite of blood and vitamin K were given intravenously. Conservative treatment was effective and the pain has disappeared on the fifth day. A hematoma began to resorb and a 4x5x9 cm organized hematoma was detected on control tomography on the seventh day (Fig. 2). An ecchymosis has appeared in lower abdominal area on the sixth day (Fig. 3). We thought that vigorous cough attacks in our patient with bronchitis probably caused rectus muscle sheath hematoma in the base of oral anticoagulant drugs use. Repetitive injury during cough attacks may cause intense contraction of the rectus muscle

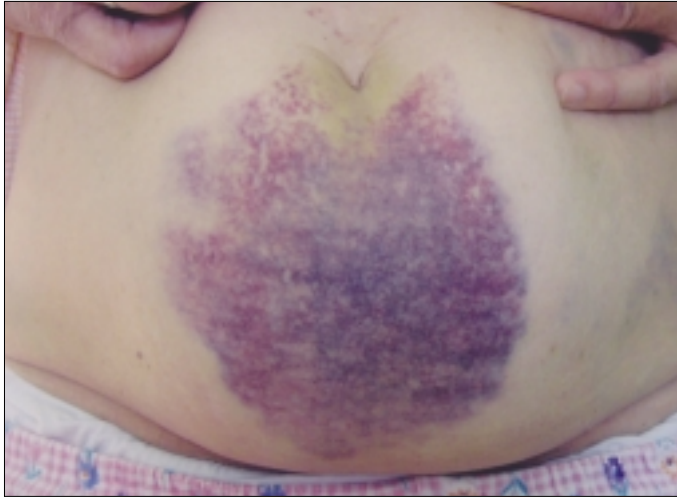


**Figure 1.** Computed tomography view of a hematoma in the left rectus abdominis muscle



**Figure 2.** Computed tomography view of an organized hematoma in the left rectus abdominis muscle seen on the 7th day

with tearing and bleeding from the perforating branches of the inferior epigastric vessels within muscles (1). However, to develop a hematoma some specific risk factors seem to co-exist in elderly subjects; the atrophy of cutaneous and subcutaneous tissues reducing the trauma neutralization,



**Figure 3. A diffuse ecchymotic appearance of abdomen on the 6th day**

vascular fragility or fat involution limiting the external compression during vascular leakage (2). Acute abdominal pain with evidence of abdominal mass and anemic syndrome in patients using oral anticoagulants, especially with severe cough attacks must alert physicians for diagnosis of rectus sheath hematoma (3, 4).

### References

1. Maharaj D, Ramdass M, Teelucksingh S, Perry A, Naraynsingh V. Rectus sheath hematoma: a new set of diagnostic features. *Postgrad Med J* 2002; 78: 290-2.
2. Manckoundia P, Zarouala B, Lalu-Fraisse A, Besancenot JF, Lorcerie B, Pfitzenmeyer P. Muscle hematoma in the very elderly receiving low-molecular-weight heparins (letter) *Presse Med* 2000; 29: 702.
3. Berna JD, Zuazu I, Madrigal M, Garcia-Medina V, Fernandez C, Guirado F. Conservative treatment of large rectus sheath hematoma in patients undergoing anticoagulant therapy. *Abdom Imaging* 2000; 25: 230-4.
4. Tuncer C, Sokmen G, Guven A, Koleoglu M, Oncel H, Suner A. A patient with an acute coronary syndrome and abdominal rectus sheath haematoma mimicking acute coronary syndrome. *Anadolu Kardiyol Derg* 2004; 4: 372-3.