

showed a peak systolic 90 mmHg gradient at valvular level, severe tricuspid and pulmonary regurgitation (Fig. 1A-C.). Intraoperatively, severely enlarged RVOT and MPA were observed to be reconstructed with a heavily calcified synthetic material back in 1978 (Fig. 2A.) and it was encroaching on MPA just distal to valvular level while causing regurgitation through the semilunar valve due to inadvertent enlargement (Fig. 2B) (Video 1. See corresponding video/movie images at www.anakarder.com). Reconstruction of RVOT and the MPA to the level of pulmonary bifurcation was achieved with a 22 mm Contegra® (Medtronic, Inc., Minneapolis, MN, USA) valved conduit (Fig. 3.). She was discharged after an uneventful postoperative course on aspirin on day 7 without any complications.

Since the first successful use of human tissue graft valves for RVOT reconstruction, various prosthetic conduits have been developed. Patch material over RVOT was not identifiable in our patient due to heavy calcification leading to a cumbersome proximal anastomosis. Contegra® has been advocated for its "off-shelf availability", wide range of conduit size, surgical pliability and encouraging short to mid-term results in addition to favorable hemostatic characteristics. Bovine jugular vein valved conduits may offer an optimal alternative when widely-accepted homografts are not available for in RVOT reconstruction in the adult.

**Onur S. Göksel, Serdar Badem, *Ahmet Bilge Kaya,
Emin Tireli, Enver Dayıoğlu**
From Departments of Cardiovascular Surgery and *Cardiology,
İstanbul Medical Faculty, University of İstanbul, İstanbul, Turkey

Address for Correspondence/Yazışma Adresi: Dr. Onur S. Göksel
4. Gazeteciler Sitesi, C3 Blok, Da: 16, 1. Levent, İstanbul, Turkey
Fax: +90 212 534 22 32 E-mail: onurgokseljet@gmail.com

Extrapleural hematoma, a rare post-operative complication of coronary bypass grafting with left internal mammary artery

Sol internal mammaryal arterin kullanıldığı koroner baypas greft operasyonu sonucunda gelişen nadir bir komplikasyon-ekstraplevral hematom

Extrapleural hematoma is a rare but life threatening complication caused by the blood collection between parietal pleura and endothoracic fascia. Generally seen after chest traumas, the complication may rarely be seen as a result of iatrogenic procedures such as central venous catheterization and coronary bypass graft (CABG) operation.

A 52-year-old man was admitted to our hospital for follow-up control 5 days after the CABG surgery. In his history, he had been suffered an

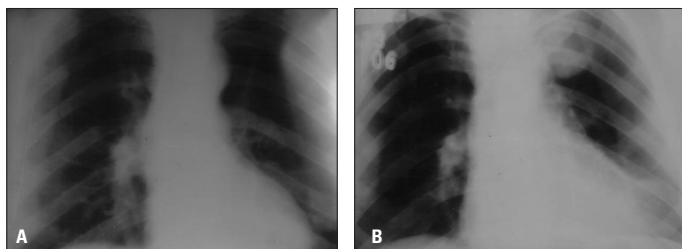


Figure 1. (A) A normal chest X ray imaging obtained before the coronary artery bypass surgery. (B) Postero-anterior chest roentgenogram demonstrating an intense, round, homogeneous density, 5x5cm in size, in the upper zone of the left hemithorax

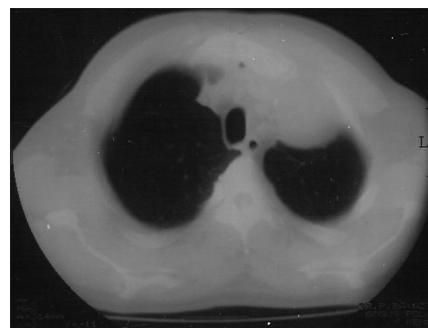

Figure 2. Chest computed tomography imaging of aloculated extrapleural effusion in the left apical hemithorax

anterior myocardial infarction and multi-vessel disease coronary artery diseases was documented on coronary angiography. Thus, he had been revascularized by left internal mammary artery (LIMA) to left anterior descending artery (LAD) graft and two saphenous venous grafts to circumflex and right coronary arteries. On the follow-up chest X-ray, we observed an intense, round, homogeneous density, 5x5cm in size, which was absent before the CABG surgery (Fig. 1A-1B). Chest computerized tomography revealed a loculated extrapleural effusion in the left superior hemithorax. (Fig. 2) An extrapleural hematoma developed after LIMA-LAD CABG surgery in this case. Because the patient was asymptomatic and hemodynamically stable, we left the extrapleural hematoma for spontaneous resolution. After the 2 months follow-up, we observed that the hematoma fully disappeared. A simple chest X-ray was the diagnostic imaging method in a rare and life threatening case.

**Yelda Tayyareci, *Çağla Pınar Taştan, *Pelin Bayazit,
♦Hacı Akar,**Uğur Yılmaz, ♦♦Tevrat Özalp, ***Osman Şengün**
From Departments of Cardiology, *Pulmonary Diseases, **Radiology
and ***Internal Medicine, Merzifon Public Hospital, Amasya,
♦Department of Cardiovascular Surgery, Samsun Public Hospital, Samsun
♦♦Department of Thoracic Surgery, Amasya Public Hospital
Amasya, Turkey

Address for Correspondence/Yazışma Adresi: Yelda Tayyareci, MD
Merzifon Public Hospital, Department of Cardiology, Merzifon, Amasya
Mobile: 0 533 362 37 72 Fax: 0358 514 08 30 E-mail: yeldatayyareci@hotmail.com

Early detection of retained surgical sponge by the lateral chest radiography

Yan göğüs radyografisi ile unutulmuş cerrahi gazlı bezin erken tespiti

Postoperative retention of a foreign body is rare but well-recognized complication. They cause either an aseptic reaction without significant symptoms or an exudative reaction which results in early but nonspecific symptoms. We describe a case of extracardiac mass in a patient submitted to an open-chest coronary artery bypass operation. At postoperative period, plain radiography of the chest revealed a hypodense mass with a thick peripheral rim, characteristic whirl-like pattern, suggestive of foreign body on the right heart border (Fig. 1). The lateral radiographic projection showed a radiopaque marker confirming a retained sponge (Fig. 2). On computerized tomography scan, an inhomogenous,

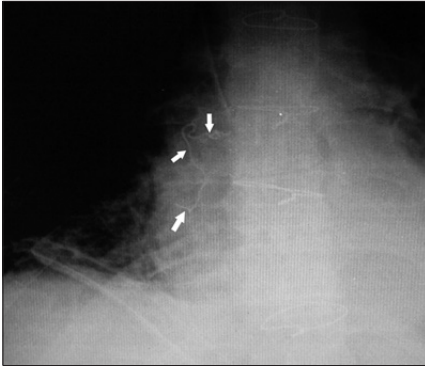


Figure 1. Plain radiograph of the chest revealed a hypodense mass with a thick peripheral rim, characteristic whirl-like pattern

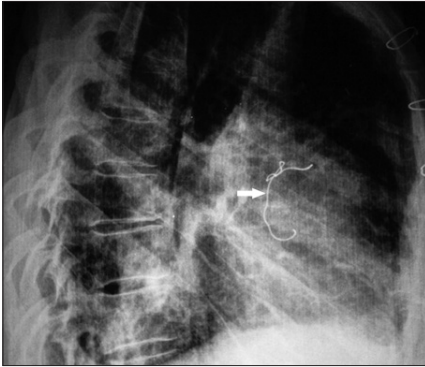


Figure 2. The lateral radiographic projection showed a radiopaque marker confirming a retained sponge.

hypodense mass with a thick peripheral rim made the diagnosis of a retained surgical gauze likely. The patient was taken for second operation (Fig. 3). The retained sponge was between the ascending aorta and the right pleura, and was removed uneventfully (Fig. 4). The patient was discharged from the hospital in good condition. This case illustrates the central role of lateral chest projections for the diagnosis and treatment of patients with suspected retained surgical sponges.

Although radiographic detection of the sponges on standard antero-posterior projections is difficult because of exposure factors, other confusing linear markers, and metallic densities such as sternal sutures, knowledge of the typical location of a lost sponge and use of lateral radiographic projections may aid in early detection of this rare

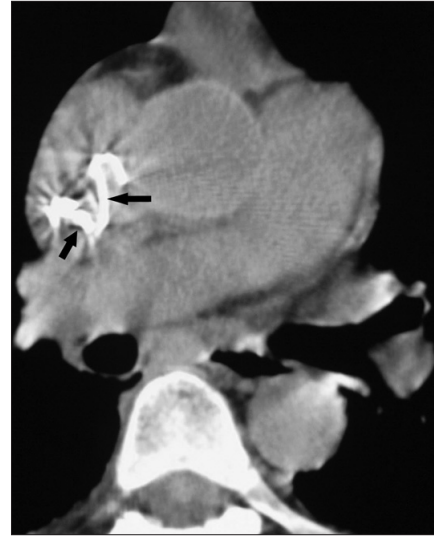

Figure 3. On computer tomography scan, an inhomogeneous, hypodense mass with a thick peripheral rim made the diagnosis of a retained surgical gauze likely

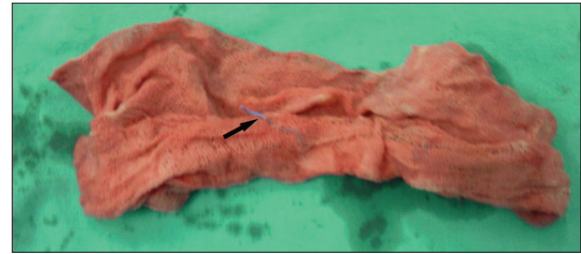


Figure 4. Postoperatively retained surgical gauze

complication. We believe that it is important to ensure that every effort is made to prevent such occurrences because of social and medicolegal problems.

**Mehmet Cengiz Çolak, Hasan Kocatürk*,
Feryaz Kızıltan, Ednan Bayram*
From Departments of Cardiovascular Surgery and *Cardiology,
Medical Center, Erzurum, Turkey**

Address for Correspondence/Yazışma Adresi: Dr. Mehmet Cengiz Çolak
Şifa Hastanesi Ilıca Yolu Üzeri, Erzurum – Turkey
Phone: +90 442 3290000
E-mail: drmccolak@yahoo.com