

## Using Common Carotid Artery for Vascular Access and Closure in a Patient Undergoing Primary Angioplasty: A Case Report

### INTRODUCTION

Percutaneous vascular access and closure of the common carotid artery are a viable options for patients requiring coronary arteriography and/or angioplasty when no other vascular access is appropriate for the patient. We hereby present a successful transcarotid procedure of primary angioplasty in a patient who has no limbs due to Buerger's disease.

### CASE REPORT

A 47-year-old male presented to the emergency room of our hospital with severe chest pain and shortness of breath for the last 2 hours. The patient's electrocardiography findings were consistent with acute anterior myocardial infarction (Figure 1A). His past medical history revealed that he smoked 2 packs of cigarettes per day for 25 years and all 4 extremities of the patient had been amputated 4 and 5 years ago due to severe Buerger's disease (Figure 1B). Thus, blood pressure measurement using a conventional sphygmomanometer was failed. Primary angioplasty instead of fibrinolytic therapy was considered for the patient. Doppler ultrasonography revealed total occlusion of both axillary and common femoral arteries. Vascular access was attempted through right superficial temporal artery puncture with ultrasound guidance, but small diameter and tortuosity of the artery prevented the advancement of the guidewire, and introducer sheath could not be inserted. Subsequently, it was decided to perform coronary angiography by direct carotid artery puncture. Under ultrasonographic guidance, right common carotid artery puncture was achieved at the closest point to the skin line passing through the right internal jugular vein (Figure 1C). A 6 French glide sheath (Terumo, Japan) was inserted without difficulty (Figure 2A and Video 1). Left coronary arteriography was performed with a 6 French EBU 3,5 Launcher guiding catheter Medtronic (Minneapolis, USA). Left coronary arteriography demonstrated critical stenosis at the level of first diagonal branch (Video 2). Provisional stenting was planned, and after predilation of the stenosis, a Promus of 3.0 × 16 mm drug-eluting stent Boston Scientific (Boston, USA) was implanted at the stenosis. Finally, provisional balloon angioplasty of the first diagonal artery with a 2.0 × 15 mm Solarice balloon (Medtronic) was done and TIMI-3 (Thrombolysis in Myocardial Infarction-3) flow was observed in both LAD (Left anterior descending) and D1 (Diagonal 1) arteries (Video 3). Instead of manual compression, 6 French Angioseal St Jude Medical (Minnesota, USA) vascular closure device was used for closure of the common carotid artery access. Immediate hemostasis was achieved after the release of the vascular plug. No neurological complications were observed at the follow-up visits. Post-procedural carotid ultrasonography did not show any limitation of carotid artery and internal jugular vein blood flow (Figure 2B and 2C). The patient was discharged 2 days later with dual antiplatelet therapy, statin, angiotensin-converting enzyme inhibitor, and beta-blocker treatment.

### DISCUSSION

Direct carotid artery puncture can be used during endovascular neurological interventions in patients with peripheral artery occlusions.<sup>1</sup> In 8 patients undergoing direct carotid artery puncture, the use of angioseal closure device was

### CASE REPORT



Ertan Vuruşkan

İrfan Veyisel Düzen

Mehmet Kaplan

Gökhan Altunbaş

Fatma Yılmaz Coşkun

Mehmet Murat Sucu

Department of Cardiology, Gaziantep University School of Medicine, Gaziantep, Turkey

#### Corresponding author:

Ertan Vuruşkan

✉ ertanvuruskan@hotmail.com

**Cite this article as:** Vuruşkan E, Düzen İV, Kaplan M, Altunbaş G, Coşkun FY, Sucu MM. Using common carotid artery for vascular access and closure in a patient undergoing primary angioplasty: A case report. *Anatol J Cardiol.* 2022;26(3):229-231.

DOI:10.5152/AnatolJCardiol.2021.659



Copyright©Author(s) - Available online at anatoljcardiol.com.  
Content of this journal is licensed under a Creative Commons Attribution-NonCommercial 4.0 International License.

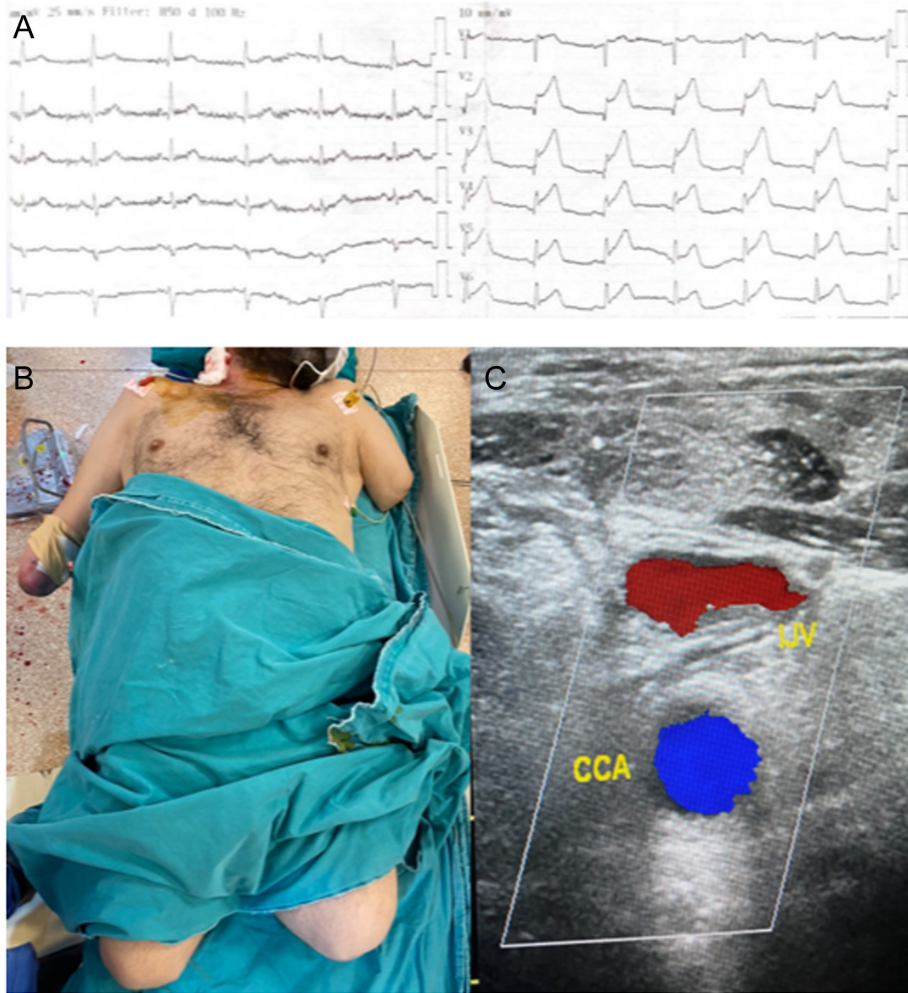


Figure 1. (A) Baseline electrocardiogram showing acute anterior myocardial infarction. (B) All the 4 extremities of the patient were amputated due to Beurger's disease. (C) Doppler ultrasonography reveals common carotid artery at the closest point to the skin line below internal jugular vein.

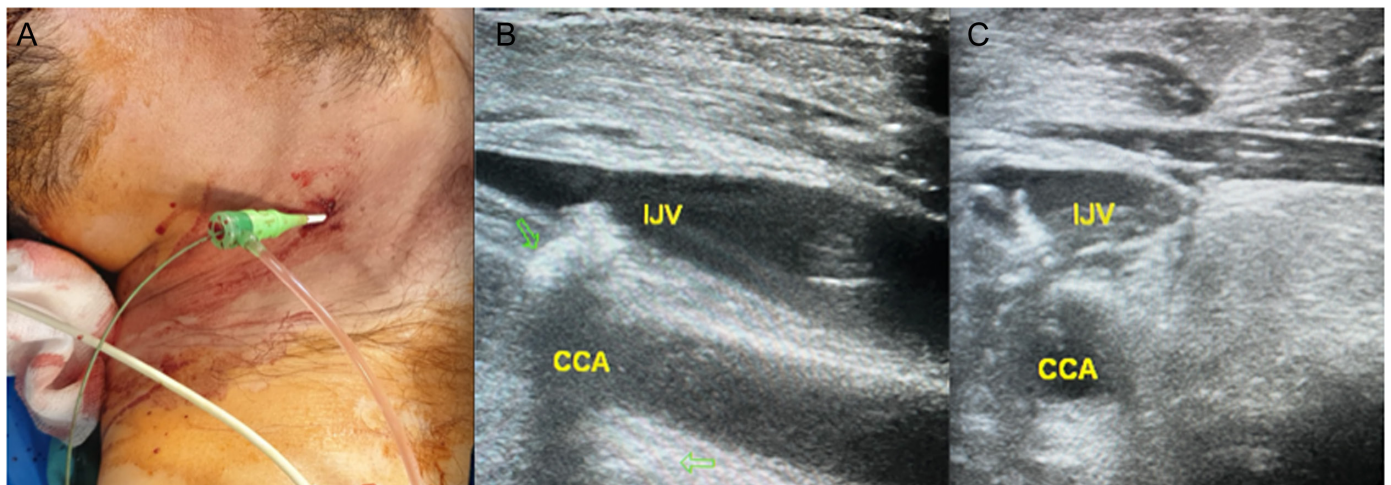


Figure 2. (A) A 6 French glide sheath was inserted by ultrasonographic guidance toward heart. (B) Longitudinal appearance of angioseal device extending from common carotid artery to the internal jugular vein. (C) Cross-sectional appearance of angioseal device extending from common carotid artery to the internal jugular vein.

demonstrated to be safe both clinically and hemodynamically.<sup>2</sup> Recently, a case was reported for the first time in the literature in a patient undergoing coronary angiography for myocardial infarction where the superficial temporal artery was used for vascular access.<sup>3</sup> Superficial temporal artery tortuosity, small diameter, and vasospasm may limit the use of superficial temporal artery for this purpose. Similarly, tortuosity restricted our ability to use superficial temporal artery, which led us to use the right common carotid artery for coronary angiography and angioplasty. To the best of our knowledge, this is the first case report of coronary angiography and primary angioplasty performed via fully percutaneous common carotid artery puncture and hemostasis with a plug-based closure device. In conclusion, the common carotid artery has the potential to be utilized as vascular access route when no other option is available such as in our case.

### CONCLUSION

Our case report demonstrates that vascular access and vascular closure with a plug-based device via common carotid artery for coronary angiography and/or angioplasty with ultrasonographic guidance are safe for patients who have no options for other vascular access.

**Informed Consent:** Written informed consent was taken from the patient for publication of this case report and accompanying images.

**Video 1:** 6 French sheath was inserted in right common carotid artery and angiography showing occlusion of the right axillary artery.

**Video 2:** Coronary angiography demonstrated critical stenosis in the left anterior descending artery.

**Video 3:** TIMI 3 flow in LAD and diagonal artery was achieved after stenting.

### REFERENCES

1. Colombo E, Rinaldo L, Lanzino G. Direct carotid puncture in acute ischemic stroke intervention. *Stroke Vasc Neurol.* 2020;5(1):71-79. [\[CrossRef\]](#)
2. Cuellar H, Guimaraens L, Ambekar S, Vivas E, Theron J. Angioseal™ as a hemostatic device for direct carotid puncture during endovascular procedures. *Interv Neuroradiol.* 2015;21(2):273-276. [\[CrossRef\]](#)
3. Csavajda A, Olivier B, Merkely B, et al. Superficial temporal artery access for percutaneous coronary artery stenting during the COVID-19 pandemic: a case report. *Eur Heart. J Case Rep.* 2020;5:520.