

Transcatheter aortic valve implantation through extra-anatomic iliac graft in a patient with unsuitable iliofemoral and subclavian anatomy

Ali Doğan, Emrah Özdemir, Denyan Mansuroğlu*, Kenan Sever*, Yelda Saltan, Behzat Özdemir, Ulviye Yılmaz, Nuri Kurtoğlu
Departments of Cardiology and *Cardiovascular Surgery, Faculty of Medicine, Gaziosmanpaşa Hospital, İstanbul Yeni Yüzyıl University; İstanbul-Turkey

Introduction

Transcatheter aortic valve implantation (TAVI) has emerged as a promising alternative for patients with severe, symptomatic aortic stenosis who are not candidates for surgery due to high comorbidity and operation mortality (1, 2). Transfemoral approach (TF) is the generally accepted route for TAVI. However, small vessel diameter and peripheral arterial disease hinder this access (3). Presently described is experience with TAVI through extra-anatomic iliac graft as an alternative approach.

Case Report

A 73-year-old female was admitted to the clinic with dyspnea and hospitalized with diagnosis of acute pulmonary edema. Patient had history of hypertension and hyperlipidemia, and had undergone coronary artery bypass graft and carotid endarterectomy 6 years prior. After treatment for acute heart failure, echocardiographic examination revealed severe aortic stenosis with peak gradient of 109 mm Hg, mean gradient of 60 mm Hg, and aortic valve area of 0.6 cm² with left ventricular ejection fraction of 57% and pulmonary hypertension (systolic pulmonary artery pressure: 63 mm Hg).

Patient had calculated logistic EuroSCORE of 37.9%, Society of Thoracic Surgeons score of 16.8% and New York Heart Association (NYHA) class III functional capacity. Multislice computed tomography (MSCT) indicated that bilateral common femoral arteries were severely calcified with diameter diminished to 4.0 and 3.8 mm (right and left femoral arteries, respectively) (Fig. 1). It also revealed that right and left subclavian artery had 5.0 mm and 5.2 mm diameter, respectively. Right subclavian artery was severely calcified.

MSCT was used for valve size calculation. Aortic annulus diameter, area, and perimeter measurements were 21x25 mm, 428 mm², and 74 mm, respectively. Before TAVI procedure, due to unsuitable iliofemoral anatomy for conventional TF approach, extra-anatomic bypass grafting to left iliac artery was performed by vascular surgeons under general anesthesia. Common iliac artery was reached with left retroperitoneal incision, and 8 mm

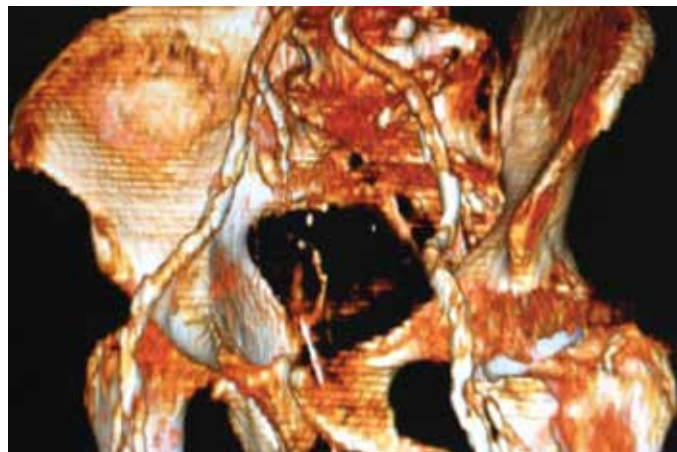


Figure 1. Multislice computed tomography (3-dimensional reconstruction) showing stenosis of femoral arteries, making them unsuitable for TAVI. Common femoral arteries were severely calcified with diameter 4.0 and 3.8 mm (right and left femoral arteries, respectively)

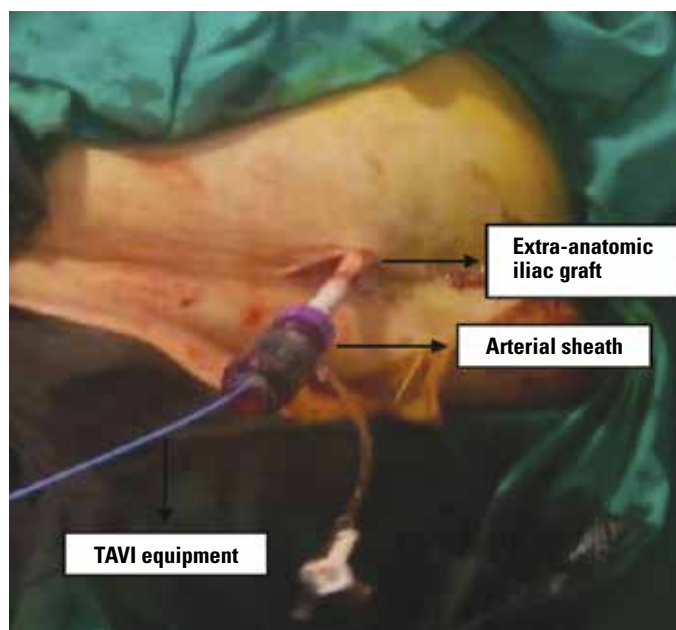


Figure 2. Polytetrafluoroethylene graft was removed for insertion of TAVI equipment

expanded polytetrafluoroethylene graft (Carboflo,® Impra Inc., Tempe, AZ, USA) was sutured end to side. Graft was removed from incision and clamped (Fig. 2). Afterward, TAVI procedure was initiated. A pigtail catheter was placed in aortic root through right femoral artery, a temporary pacemaker lead was placed in right ventricle through right femoral vein and procedure was performed through left aortoiliac graft. Amplatz 0.035 inch, 260 cm super stiff guidewire (Boston Scientific Corporation; Natick, Mass., USA), was passed through pigtail catheter to reach left ventricle apex. After dilatation with 25x40 mm balloon, 26 mm Edwards SAPIEN bioprosthesis (Edwards Lifesciences LLC; Irvine, Calif., USA) valve was deployed optimally. No complication or

aortic regurgitation was observed after procedure. Postoperatively, graft was ligated and sutured 2 cm above anastomotic line. Echocardiography showed that peak and mean transvalvular gradients decreased to 18 and 7 mm Hg, respectively, and valve area increased to 1.9 cm². Patient's functional capacity was improved to NYHA 1 during first month of follow-up.

Discussion

In a study investigating use of Edwards SAPIEN 3, TF route could be used only in 64% of patients (4). Transapical, subclavian, carotid, and direct aortic access routes have been developed as alternatives to TF approach (5). Recently, a study based on UK TAVI registry revealed transapical and direct aortic approach had higher mortality than TF route. Subclavian access mortality was found to be similar to TF and evaluated as safest nonfemoral access route for TAVI (6).

In present case, TAVI was performed through left iliac graft. Heart team decided not to use transapical or direct aortic approach because of higher mortality rates. Carotid approach was not selected due to patient's history of carotid endarterectomy. For subclavian approach, artery diameter should be at least 6 mm for 18 French sheath in absence of calcification (5). However, patient's subclavian arteries were not appropriate for this access due to reduced vessel size and severely calcified nature of right subclavian artery.

To our knowledge, this is the first report of extra-anatomic iliac graft for TAVI. There is 1 study in the literature that used TF approach through left aorto-iliac graft to deploy Edwards SAPIEN valve; however, that case involved a patient who had existing bilateral aortoiliac graft (7). Present patient was treated successfully and no complication was observed during follow-up. Caution should be taken with regard to graft size for insertion of TAVI equipment and anastomosis-related complications such as hematoma and infection.

Conclusion

In patients with anatomy unsuitable to femoral or subclavian access, extra-anatomic iliac graft can be used safely and it could be accepted as an alternative, novel route for TAVI.

References

1. Cribier A, Eltchaninoff H, Bash A, Borenstein N, Tron C, Bauer F, et al. Percutaneous transcatheter implantation of aortic valve prosthesis for calcific aortic stenosis: first human case description. *Circulation* 2002; 106: 3006-8. [Crossref](#)
2. Bourantas CV, Farooq V, Onuma Y, Piazza N, Van Mieghem NM, Serruys PW. Transcatheter aortic valve implantation: new developments and upcoming clinical trials. *EuroIntervention* 2012; 8: 617-27. [Crossref](#)
3. Moat NE, Ludman P, de Belder MA, Bridgewater B, Cunningham AD, Young CP, et al. Long-term outcomes after transcatheter aortic valve implantation in high-risk patients with severe aortic stenosis:

the U.K. TAVI (United Kingdom Transcatheter Aortic Valve Implantation) Registry. *J Am Coll Cardiol* 2011; 58: 2130-8. [Crossref](#)

4. Webb J, Gerosa G, Lefèvre T, Leipsic J, Spence M, Thomas M, et al. Multicenter evaluation of a next-generation balloon-expandable transcatheter aortic valve. *J Am Coll Cardiol* 2014; 64: 2235-43.
5. Toggweiler S, Leipsic J, Binder RK, Freeman M, Barbanti M, Heijmen RH, et al. Management of vascular access in transcatheter aortic valve replacement: part 1: basic anatomy, imaging, sheaths, wires and access routes. *JACC Cardiovasc Interv* 2013; 6: 643-53.
6. Fröhlich GM, Baxter PD, Malkin CJ, Scott DJ, Moat NE, Hildick-Smith D, et al. Comparative Survival After Transapical, Direct Aortic, and Subclavian Transcatheter Aortic Valve Implantation (data from the UK TAVI registry). *Am J Cardiol* 2015; 116: 1555-9. [Crossref](#)
7. Gül M, Akgül O, Ertürk M, Eksik A, Yıldırım A. Transcatheter aortic valve implantation through a left aortoiliac graft. *Tex Heart Inst J* 2012; 39: 898-900.

Address for Correspondence: Dr. Ali Doğan
İstanbul Yeni Yüzyıl Üniversitesi Tıp Fakültesi
Gaziosmanpaşa Hastanesi, Kardiyoloji Bölümü, Gaziosmanpaşa
İstanbul-*Türkiye*
E-mail: drdali@hotmail.com

©Copyright 2016 by Turkish Society of Cardiology - Available online
at www.anatoljcardiol.com

DOI:10.14744/AnatolJCardiol.2016.7097



The first case of chronic Q fever endocarditis and aortitis from Turkey: A 5-year infection before diagnosis with drain in sternum

Serap Şimşek Yavuz, Ezgi Özbek, Seniha Başaran, Bekir Çelebi¹, Ebru Yılmaz*, Murat Başaran**, Berrin Umman***, Haluk Eraksoy
Departments of Infectious Diseases and Clinical Microbiology,
*Nuclear Medicine, **Cardiovascular Surgery, ***Cardiology,
İstanbul Faculty of Medicine, İstanbul University; İstanbul-Turkey
¹Department of Reference Microbiology Laboratories, Turkish Public Health Institute; Ankara-Turkey

Introduction

Q fever is a zoonotic disease caused by *Coxiella burnetii*. The acute form of the disease may present as flu-like illness and pneumonia, whereas chronic form presents mainly as infective endocarditis (IE) (1).

Although acute cases and small epidemics of Q fever have been defined (2), herein we report the first case of chronic Q fever endocarditis in Turkey.

Case Report

A woman aged 29 years was admitted to hospital with symptoms of fever, weakness, and rash on her legs. She had undergone aortic surgery 3 times between 1997 and 2010: aortic commissurotomy because of rheumatic valve disease, aortic valve