

Electrocardiographic Diagnosis of Acute Myocardial Ischemia During His Bundle Pacing

INTRODUCTION

Resting 12-lead electrocardiogram (ECG) is the first-line diagnostic tool in the evaluation of patients with the suspected acute coronary syndrome (ACS)¹; however, in pacemaker (PMK) recipients, ECG morphological changes related to right ventricular (RV) pacing, even in intermittent paced forms, make it difficult to correctly diagnose myocardial ischemia, also due to the phenomenon known as cardiac memory.² It is therefore evident that the aforementioned alterations in the electrogenesis of ventricular repolarization may be at the basis of a diagnostic delay or even misrecognition of ACS.³

In recent years, we have witnessed a progressive interest of the scientific community in His bundle (HB) pacing as an alternative to RV pacing.⁴ His bundle pacing is rightly considered physiological, since, unlike RV pacing, the electrical impulse travels through the normal conduction system and, therefore, does not result in ventricular electrical dyssynchrony.^{3,4} As a result, paced ventricular complexes show morphological features that are completely superimposable to those evident in the baseline ECG.³⁻⁶ Although HB pacing, in contrast to RV pacing, should not affect the ventricular repolarization phase, there are no data in the literature about the electrocardiographic diagnosis of myocardial ischemia during HB pacing.

Therefore, below, we introduce a clinical case of a PMK recipient in which the HB pacing mode allowed us to diagnose a non-ST elevation myocardial infarction (NSTEMI).

CASE REPORT

We report the clinical case of a 76-year-old Caucasian man with hypertension, obesity (body mass index 34 kg/m²), paroxysmal atrial fibrillation, ischemic dilated cardiomyopathy, and low left ventricular ejection fraction (LVEF) who was treated with percutaneous transluminal coronary angioplasty in 2015. In 2017, the patient underwent successful cardiac resynchronization therapy (CRT-D) implantation because of advanced atrioventricular block and 30% LVEF despite optimal medical therapy. In November 2019, he was hospitalized for acute aggravation of heart failure due to iatrogenic dyssynchrony because of LV lead dislocation.

As a rescue, an upgrade to HB pacing was performed during the same hospitalization; the surface ECG showed selective HB pacing with a capture threshold value of 1.25 V for 1 millisecond (Figure 1A). The patient promptly responded to the upgrade, showing a marked improvement in his clinical status already after 1 week (NYHA class II), as well as an increase in LVEF to 40% after 4 months. In January 2021, he presented to the emergency department reporting chest pain and dyspnea, which started 3 hours before arrival; medical therapy included acetylsalicylic acid, bisoprolol, amiodarone, furosemide, sacubitril/valsartan, atorvastatin, and apixaban.

CASE REPORT

Leonardo Marinaccio ¹

Francesco Vetta ²

Giuliana Ginocchio ¹

Giuseppe Maria Marchese ³

Domenico Marchese ¹

¹Department of Cardiology, Immacolata Concezione Hospital, Piove di Sacco, Italy

²Saint Camillus International University of Health Sciences, Roma, Italy

³Department of Cardiology, Madre Teresa di Calcutta Hospital, Monselice, Italy

Corresponding author:

Leonardo Marinaccio

✉ leonardo.marinaccio@aulss6.veneto.it

Cite this article as: Marinaccio L, Vetta F, Ginocchio G, Maria Marchese G, Marchese D. Electrocardiographic diagnosis of acute myocardial ischemia during his bundle pacing. *Anatol J Cardiol* 2022;26(4):328-330.

DOI:10.5152/AnatolJCardiol.2021.648



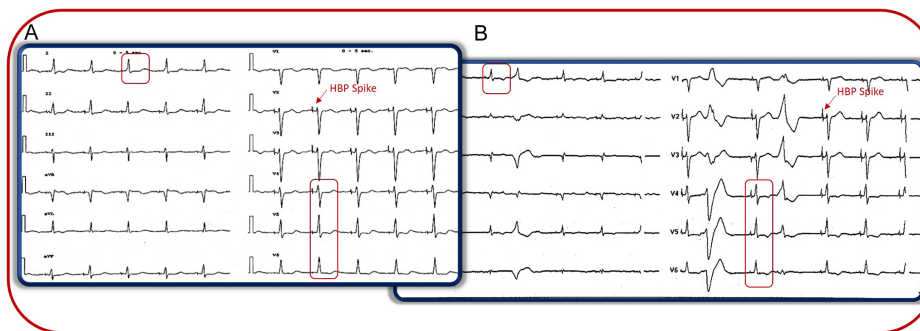
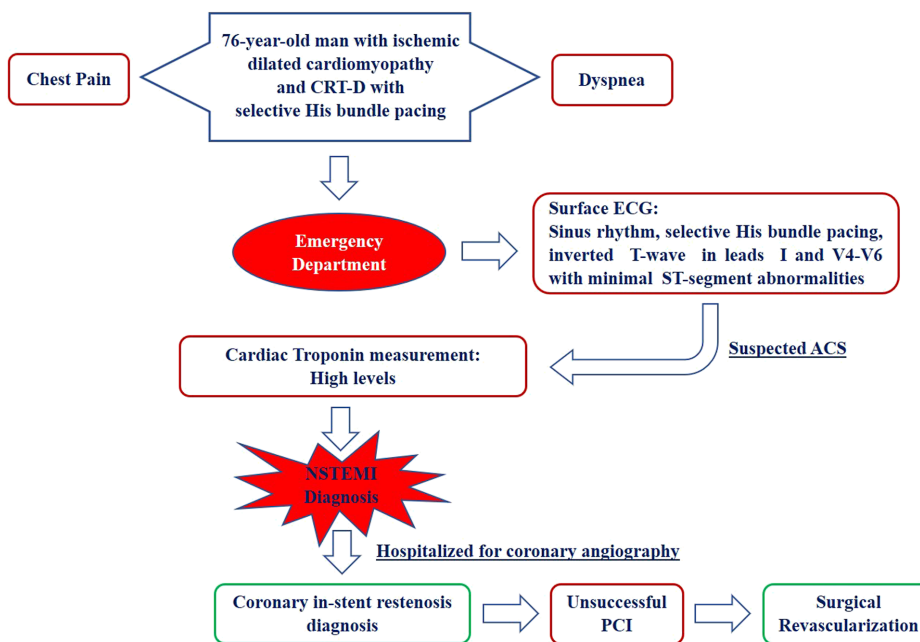


Figure 1. (A) Surface 12-lead ECG at rest: it shows sinus rhythm and selective His bundle pacing. (B) Surface 12-lead ECG at hospital admission, during chest pain: it shows sinus rhythm, selective His bundle pacing, and lateral subendocardial ischemia with inverted T-wave in leads I (red square) and V4-V6 (red rectangle) with minimal ST-segment abnormalities. Red arrow: PMK spike; HBP, his bundle pacing; ECH, electrocardiogram.

At the hospital admission, ECG showed sinus rhythm with 85 beats/min, selective HB pacing with narrow QRS complexes, and inverted T wave in leads I, V4-V6 with minimal ST-segment abnormalities revealing lateral subendocardial myocardial ischemia (Figure 1B), not present in a previous ECG (Figure 1A); laboratory test results were significant for troponin I: 570 ng/mL (normal range 0.00-0.04 ng/mL), and hemoglobin value 7.7 g/dL.

He was then admitted with an NSTEMI diagnosis; trans-thoracic echocardiography showed LVEF of 30% (40% at the previous check of 6 months before) and hypokinesia involving anterior and lateral walls of the left ventricle. Two units of red blood cell concentrate were administered,

and the hemoglobin value changed to 12.1 g/dL. The next day, the patient was asymptomatic but, although the troponin value decreased, electrocardiographic abnormalities persisted. After giving informed consent, the patient underwent coronary angiography which diagnosed critical restenosis with stent under-expansion at the left anterior descending coronary in its proximal tract, where a previous PCI was performed in the context of a stable coronary syndrome. Unfortunately, the stent expansion attempt was unsuccessful, then the patient was successfully subjected to surgical revascularization (Figure 2). After 3 months, the patient was asymptomatic with the confirmed clinical improvement that was also demonstrated by an LVEF value of 45%.



Educational Message

ACS diagnosis is very challenge in PMK carriers because of ECG morphological alterations resulting from right ventricular pacing . Cardiac activation during HB pacing occurs via the normal conduction system and it does not result in ventricular electrical dyssynchrony, therefore paced QRS complexes morphology is comparable to basal ECG. This peculiarity immediately allowed us to notice the small ECG abnormalities and to achieve a timely NSTEMI diagnosis

Figure 2. Diagram representing the decision/diagnosis strategy. CRT-D, cardiac resynchronization therapy; ACS, acute coronary syndrome; PMK, pacemaker; NSTEMI, non-ST elevation myocardial infarction.

DISCUSSION

Acute coronary syndrome diagnosis is more complex in PMK recipients, often leading to delays in treatment with a subsequent worse prognosis.³ Right ventricular pacing typically produces a left bundle-branch block (LBBB)-like pattern in septal and anterior precordial leads, with a predominantly negative QRS complex followed by ST elevation and positive T-waves.^{7,8} Sgarbossa criteria can help identify myocardial infarction with ST-segment elevation (STEMI) in LBBB patients, allowing at least in some cases, timely access to reperfusion therapy. However, the low sensitivity of these criteria (between 18% and 55%) results in a low negative predictive value to exclude an acute coronary event.⁷⁻¹⁰ Finally, these criteria cannot be applied in cases of NSTEMI. Among the options to evaluate a patient with RV-paced rhythm for acute ST abnormalities, we can include temporary cessation of ventricular pacing (through pacemaker reprogramming), which, besides not being possible if the patient has complete atrioventricular block (pacemaker-dependent patient), is also poorly useful in non-pacemaker-dependent patients, because of the mentioned phenomenon of "T-wave memory" that may mask ST changes caused by myocardial ischemia.^{2,8,10}

Occurring through the normal conduction system, HB pacing should generate in addition to a depolarization also physiological myocardial repolarization resulting in a paced QRS complex with morphology and duration equal to the basal ECG, without alterations in the ventricular repolarization phase. As proof of the above, it was possible to appreciate the mild electrocardiographic abnormalities that allowed a timely diagnosis of NSTEMI in a clinical case.

CONCLUSIONS

The clinical case reported has the advantage of demonstrating, for the first time, the possibility of establishing a diagnosis of NSTEMI during stimulation of the physiological conduction system.

Therefore, in light of the current data and evidence on the feasibility and safety of HBP, it seems reasonable to consider

HB pacing also in patients at high risk of ischemic heart disease who require pacing.

Informed Consent: Written informed consent was obtained from all participants who participated in this study.

REFERENCES

1. Collet JP, Thiele H, Barbato E, et al. 2020 ESC Guidelines for the management of acute coronary syndromes in patients presenting without persistent ST-segment elevation. *Eur Heart J*. 2021;42(14):1289-1367. [\[CrossRef\]](#)
2. Shvilkin A, Huang HD, Josephson ME. Cardiac memory: diagnostic tool in the making. *Circ Arrhythm Electrophysiol*. 2015;8(2):475-482. [\[CrossRef\]](#)
3. Abraham AS, Vinson DR, Levis JT. ECG diagnosis: acute myocardial infarction in a ventricular-paced rhythm. *Perm J*. 2019;23:19-001.
4. Vetta F, Marinaccio L, Vetta G. Alternative sites of ventricular pacing: His bundle pacing. *Monaldi Arch Chest Dis*. 2020;90(2):218-223. [\[CrossRef\]](#)
5. Vijayaraman P, Dandamudi G, Zanon F, et al. Permanent His bundle pacing: recommendations from a Multicenter His bundle Pacing Collaborative Working Group for standardization of definitions, implant measurements, and follow-up. *Heart Rhythm*. 2018;15(3):460-468. [\[CrossRef\]](#)
6. Catanzariti D, Maines M, Manica A, Angheben C, Varbaro A, Vergara G. Permanent His-bundle pacing maintains long-term ventricular synchrony and left ventricular performance, unlike conventional right ventricular apical pacing. *Europace*. 2013;15(4):546-553. [\[CrossRef\]](#)
7. Khurshid S, Epstein AE, Verdino RJ, et al. Incidence and predictors of right ventricular pacing-induced cardiomyopathy. *Heart Rhythm*. 2014;11(9):1619-1625. [\[CrossRef\]](#)
8. Browning AC, Schaefer S. What lies beneath: posterior ST elevation myocardial infarction with underlying right ventricular-paced rhythm. *Exp Clin Cardiol*. 2013;18(1):e55-e56.
9. Barold SS, Herweg B, Curtis AB. Electrocardiographic diagnosis of myocardial infarction and ischemia during cardiac pacing. *Cardiol Clin*. 2006;24(3):387-99, ix. [\[CrossRef\]](#)
10. Nestelberger T, Cullen L, Lindahl B, et al. Diagnosis of acute myocardial infarction in the presence of left bundle branch block. *Heart*. 2019;105(20):1559-1567. [\[CrossRef\]](#)