

Consecutive Narrower Fixation Beats as a Marker of Lead Advancement into the Septum During Left Bundle Branch Pacing

INTRODUCTION

His bundle pacing (HBP) started as the most promising physiological pacing method, but nowadays, most of the implanters shifted their attention toward left bundle branch pacing (LBBP). There are several methods to confirm interventricular septal perforation during lead screwing. We present an LBBP case in which consecutive ectopic beats of progressive morphology from left to right bundle branch block (RBBB) pattern occurring during lead fixation served as a marker for reaching the targeted left endocardium.

CASE REPORT

A 77-year-old male patient was admitted for recurrent presyncope episodes. His baseline echocardiography (ECG) showed sinus rhythm with complete atrioventricular (AV) block and a ventricular escape rhythm with an RBBB morphology (Figure 1A). The laboratory results and echocardiography were unremarkable. A dual-chamber pacemaker was indicated, and an LBBP strategy was chosen. As has been described by Huang et al¹ a Medtronic C315 His sheath and a 3830 Selectsecure lead (Medtronic, Minneapolis, Minnesota, USA) first recorded the His bundle recording, showing an infra-Hisian AV block (Figure 2A). The ensemble was then advanced 1.5 cm toward the apex and maintained perpendicular to the septum. With slow and continuous clockwise rotations, the lead was advanced into the septum under ECG and fluoroscopic monitoring. During lead progression, the tracing in Figure 2B was recorded: after an initial intrinsic QRS complex with an RBBB morphology, several ectopic beats were mechanically generated by the lead tip (Video 1). The first one (marked with an asterisk) had a pure LBB block morphology as the focus was on the right side of the septum. The next ones were progressively narrower from beat to beat, as the lead tip protruded deeper into the septum. The ninth beat (marked with an arrow) showed a Qr pattern in V1 meaning that the left side of the septum was reached. Pacing at this site resulted in a very narrow QRS complex with a left ventricular activation time of 75 ms (proof for LBB recruitment) and a pacing threshold of 0.5V at 0.4 ms (Figure 1B).

DISCUSSION

Left bundle branch pacing is superior to HBP due to a significantly larger target zone, very good and stable pacing and sensing thresholds, and a high success rate irrespective of the level of conduction block.²

In a recent meta-analysis published by Tokavanich et al³ which evaluated the QRS duration in different pacing strategies compared to right ventricular pacing, HBP achieved the narrowest paced complex, followed closely by LBBP.

Our case confirmed these findings because the morphology of the ectopic beats induced by the lead tip as it moved from the right to the left side of the septum showed progressively shorter durations.

The "sine qua non" condition to perform LBBP is to successfully penetrate the interventricular septum. Several methods are used to follow lead advancement,

CASE REPORT



Catalin Pestrea ^{ID}^{1,2}

Ecaterina Cicala ^{ID}¹

Alexandra Gherghina ^{ID}³

Florin Ortan ^{ID}¹

¹Interventional Cardiology Unit, Brasov County Clinical Emergency Hospital, Brasov, Romania

²Department of Cardiology, "Iuliu Hatieganu" University of Medicine and Pharmacy, Clinical Rehabilitation Hospital, Cluj-Napoca, Romania

³Intensive Coronary Care Unit, Brasov County Clinical Emergency Hospital, Brasov, Romania

Corresponding author:

Catalin Pestrea

✉ pestrea.catalin@gmail.com

Cite this article as: Pestrea C, Cicala E, Gherghina A, Ortan F. Consecutive narrower fixation beats as a marker of lead advancement into the septum during left bundle branch pacing. *Anatol J Cardiol.* 2022;26(6):495-497.

DOI:10.5152/AnatolJCardiol.2022.1383



Copyright©Author(s) - Available online at anatoljcardiol.com.
Content of this journal is licensed under a Creative Commons Attribution-NonCommercial 4.0 International License.

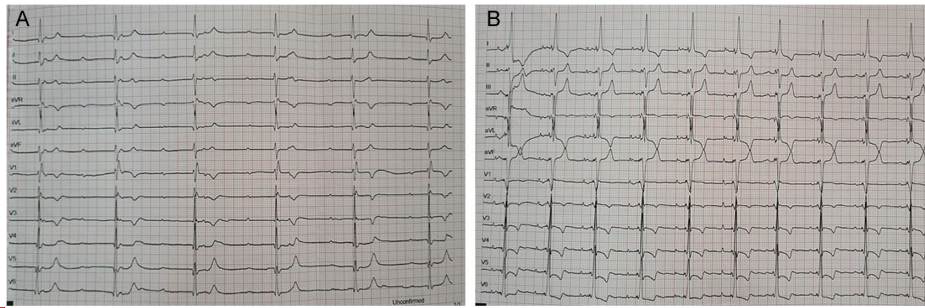


Figure 1. (A) Baseline ECG showing complete AV block. (B) Final ECG showing QRS complexes suggestive of left bundle branch pacing. ECG, electrocardiography; AV, atrioventricular.

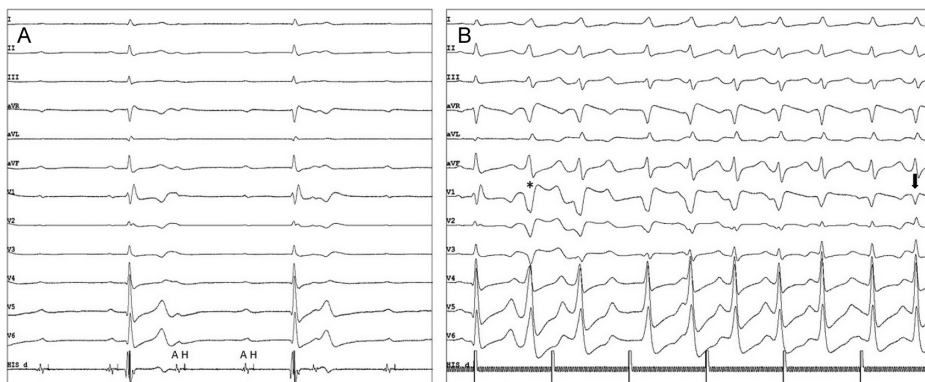


Figure 2. (A) His bundle electrogram shows complete infra-Hisian block. (B) Fixation beats with progressively narrower duration during lead advancement into the septum (see text for details).

including imagistic (fluoroscopic or echocardiographic) or electrocardiographic (QR or RBBB pattern in lead V1, left ventricular activation time in lead V6 less than 85 ms).⁴

In 2020, Jastrzębski et al⁵ first described the so-called “fixation beats” as ectopic beats generated by the lead tip during fixation. They showed that these beats occur in virtually all patients when the lead tip reaches the left endocardium. On the other hand, a significantly less proportion of patients encountered ectopic beats generated at different levels of septal penetration, a fact that may be explained by reduced excitability at these levels.

We also believe that the screwing technique may play a part in the pattern of the ectopic beat generation. If the rotations are very fast and the lead advances quickly into the septum, after a first ectopic beat, the myocardium becomes refractory and thus inexcitable, with the subsequent ectopic beats appearing only when the lead is already close to the left side.

In our case, we have shown that a gradual and slower movement of the lead into the septum (Video 2) can generate consecutive narrower QRS complexes, proving the progression of the lead tip. Once a Qr or an RBBB pattern is seen, the screwing must stop to avoid perforation into the left ventricle.⁶

CONCLUSIONS

The prerequisite for LBBP is effective septal penetration. Imagistic methods cannot precisely prove that the left side of

the septum has been reached. On the other hand, mechanical induced ectopic beats act as a precise localization tool of the lead tip position, in order to increase the success rate and minimize complications.

Informed Consent: Written informed consent has been obtained from the patients to publish this paper.

Funding: Dr. Catalin Pestrea received modest proctorship fees and travel grants from Medtronic.

Video 1: Real-time recording of fixation beats during lead screwing into the septum.

Video 2: Left anterior oblique fluoroscopic image during lead fixation into the septum.

REFERENCES

- Huang W, Chen X, Su L, Wu S, Xia X, Vijayaraman P. A beginner's guide to permanent left bundle branch pacing. *Heart Rhythm*. 2019;16(12):1791-1796. [\[CrossRef\]](#)
- Su L, Wang S, Wu S, et al. Long-term safety and feasibility of left bundle branch pacing in a large single-center study. *Circ Arrhythm Electrophysiol*. 2021;14(2):e009261. [\[CrossRef\]](#)
- Tokavanich N, Prasitlumkum N, Mongkonsritragoon W, et al. A network meta-analysis and systematic review of change in QRS duration after left bundle branch pacing, His bundle pacing, biventricular pacing, or right ventricular pacing in patients requiring permanent pacemaker. *Sci Rep*. 2021;11(1):12200. [\[CrossRef\]](#)

4. Sundaram S, Vijayaraman P. Left bundle branch pacing. *Herzschrittmacherther Elektrophysiol.* 2020;31(2):124-134. [\[CrossRef\]](#)
5. Jastrzębski M, Kiełbasa G, Moskal P, et al. Fixation beats: a novel marker for reaching the left bundle branch area during deep septal lead implantation. *Heart Rhythm.* 2021;18(4):562-569. [\[CrossRef\]](#)
6. Liu P, Wang Q, Sun H, Qin X, Zheng Q. Left bundle branch pacing: current knowledge and future prospects. *Front Cardiovasc Med.* 2021;8:630399. [\[CrossRef\]](#)