

An anomalous left coronary artery detected by multislice computed tomography

Çok kesitli bilgisayarlı tomografi ile tespit edilen bir sol koroner arter anomalisi

A 57-year-old man was referred to the hospital with atypical chest pain and dyspnea. He had history of dyslipidemia for 10 years, smoking for 25 years and had hypertension for 5 years. He was on antihypertensive treatment. His electrocardiogram showed in sinus rhythm. His cardiovascular stress test was non-diagnostic, so we decided to perform a multislice computed tomography (MSCT). We performed MSCT (16 slice Aquillion) of coronary arteries using an electrocardiography gated standard protocol. An atypical left coronary artery (LCA) ostia originating from the right sinus of Valsalva was demonstrated just posterior to the right coronary ostia and its course was posterior to the aorta (Fig. 1). We could see the origin of both LCA and right coronary artery and proximal courses of them excellently. However, we could not see the distal course clearly. Therefore, we could not exclude obstructive coronary artery disease and decided to perform a coronary angiography. During the coronary angiography, we demonstrated the atypical origin of LCA and its course (Fig. 2, Video 1. See corresponding video/movie images at www.anakarder.com). There were insignificant lesions in the right and left coronary systems.

M. Gürkan Kutucularoğlu, A. Savaş Çelebi, Özlem Özcan, Erdem Diker
Department of Cardiology, Ankara Numune Research and Education Hospital, Ankara, Turkey

Address for Correspondence/Yazışma Adresi: Dr. M. Gürkan Kutucularoğlu
Ankara Numune Research and Education Hospital, Cardiology Department
Samanpazarı, Altındağ, Ankara, Turkey
Phone: +90 312 310 30 30/3405 - +90 312 346 14 50 E-mail: drgurkan78@yahoo.com

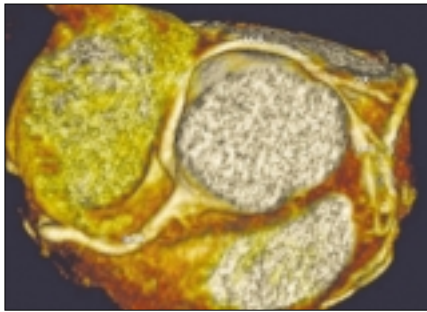


Figure 1. Multislice computerized tomography image of the LCA ostia originating from the right sinus of Valsalva, just posterior to the right coronary ostia and its course is seen posterior to the aorta
Cx- circumflex artery, LAD- left anterior descending artery, LCA- left coronary artery, RCA- right coronary artery

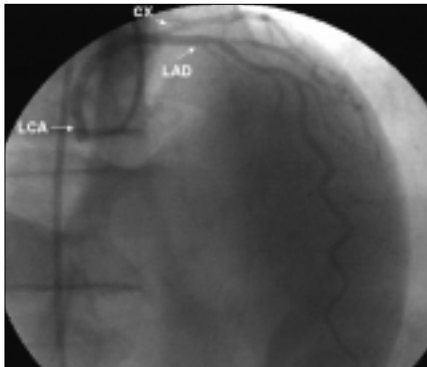


Figure 2. Angiographic demonstration of LCA and its course
Cx - circumflex artery, LAD- left anterior descending artery, LCA- left coronary artery

An uncommon coincidence of congenital quadricuspid aortic valve accompanied by hypertrophic obstructive cardiomyopathy

Konjenital kuadriküspid aort kapak ile hipertrofik kardiyomiopatinin nadir birlikteliği

Quadricuspid aortic valve (QAV) is a rare congenital anomaly with the incidence rate of 0.008%- 0.033% (1). Most of the cases can incidentally be diagnosed during aortography, aortic valve replacement or autopsy. At present, quadricuspid aortic valve is easy to recognize due to technological improvements in both transthoracic and transesophageal echocardiography (2, 3).

A 35-year-old man was admitted to our department with symptoms of progressive dyspnea and a sharp chest pain during exertion for the last two years. Physical examination revealed a blood pressure of 130/80 mmHg, regular heart rate of 68/min and a grade 3/6 systolic ejection murmur which was loudest at the 2nd right intercostal space. The 12 lead- electrocardiogram showed normal sinus rhythm, left ventricular hypertrophy and nonspecific ST segment and T wave abnormalities (Fig. 1). Chest radiography demonstrated mild cardiomegaly with left ventricular hypertrophy. Transthoracic and transesophageal echocardiography revealed massive concentric hypertrophy (Fig. 2A). Septal thickness was 22mm while free wall thickness was 15mm (septal to free wall ratio 1,5: 1. Additionally, an abnormal systolic anterior motion of the mitral valve and 64 mmHg of left ventricular outflow tract pressure gradient were determined (Fig. 2B). In parasternal short-axis view, the aortic valve demonstrated four thin equal cusps with a squared image of the open cusps in systole and an X - shape of the closed cusps in diastole (Fig. 2C-D). A mild degree of central aortic insufficiency resulting from incomplete diastolic coaptation of the cusps was detected by continuous Doppler echocardiography. Left ventricular dimensions and systolic functions were in normal ranges. Because the anomaly of the quadricuspid aortic valve can also cause aortic stenosis, we performed cardiac catheterization to establish the main cause of the pressure gradient. During cardiac catheterization, coronary arteries were found normal and the measured pressure was 185/10mmHg in the left ventricular cavity, 130/80 mmHg at the level of the aortic valves, and 150/10mmHg at the lower level of the aortic valves. The transaortic pressure gradient was 55 mmHg and a severe left ventricular hypertrophy and mild aortic insufficiency were detected (Video 1. See corresponding video/movie images at www.anakarder.com). The aortography could not show the morphology of the aortic cusps. These findings suggested an uncommon developmental anomaly of aortic valves coexisting with hypertrophic obstructive cardiomyopathy.

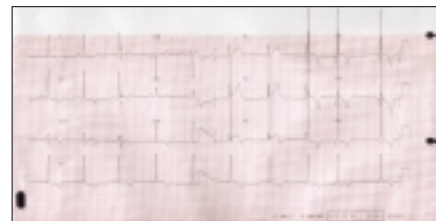


Figure 1. The 12 lead- electrocardiogram showed normal sinus rhythm, left ventricular hypertrophy and nonspecific ST segment and T wave abnormalities