

Periodic recurrence of wide QRS tachycardia in myocardial infarction and vasospasm: utility of heart rate variability to assess autonomic nervous system activity on vasospasm-induced lethal arrhythmia

Miyokard infarktüsü ve vasospazma eşlik eden geniş QRS taşikardinin periyodik tekrarlanması: Vasospazma bağlı ölümcül aritmide otonom sinir sistemi aktivitesinin değerlendirilmesinde kalp atım hızı değişkenliğinin yararı

Bonpei Takase, Kazuo Kimura, Akira Hamabe*, Akimi Uehata*, Hattori Hidemi¹, Masayuki Ishihara¹, Akira Kurita

From Departments of Intensive Care Medicine and*Internal Medicine, Self Defense Forces Central Hospital
¹Division of Biomedical Engineering, National Defense Medical College Research Institute, Saitama, Japan

Introduction

The episode of coronary vasospasm with lethal arrhythmias sometimes shows diurnal feature, and heart rate variability (HRV) reflects the autonomic nervous control of the heart (1, 2). This case presents the role of HRV analysis in understanding the pathophysiology of periodic occurrence of vasospasm with lethal arrhythmias.

Case report

A 62-year-old man with acute myocardial infarction (MI) in whom the duration between the last episode of chest pain and admission exceeded 12 h was treated in our hospital. Coronary risk factors included a smoking. Electrocardiogram (ECG) was compatible for anterior MI with frequent premature ventricular contractions (Fig. 1). Upon admission, transient ST-segment elevation in the inferior leads was observed (Fig. 1) and emergency coronary angiogram was performed.

Coronary angiography revealed a 90% luminal diameter stenosis in the proximal portion of the left descending coronary artery, but TIMI III flow was observed without other significant lesions. Because of time window (>12 h) and satisfied flow, emergency percutaneous coronary intervention was postponed. The blood flow to inferior region of left ventricle was supplied by the right coronary artery. Inferior lead ST-segment elevation observed on the ECG was considered as coronary vasospasm. Nifedipine (40 mg q.d.) and isosorbide dinitrate (20 mg b.i.d.) were initiated.

Sudden onset of wide QRS tachycardia with hemodynamic collapse occurred at 09:10 on the 5th day of hospitalization needed direct current defibrillation. Despite lidocaine treatment, the patient experienced recurrence of the wide QRS tachycardia at the same time on the 6th and 7th days of admission (Fig. 2). The patient remained stable after propafenone was added.

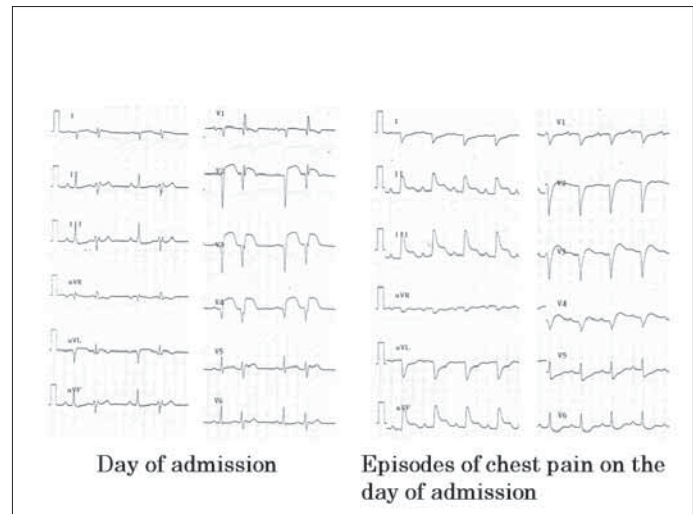


Figure 1. A 12-lead electrocardiogram displays frequent premature ventricular contractions and marked ST-segment elevation, accompanying worsening of chest discomfort in a patient

Nonsustained wide QRS tachycardia recurred periodically on the 18th, 19th, 20th, 29th, and 30th day of hospitalization (Fig. 2) and amiodarone therapy started. ECG on the 18th day showed left bundle branch block with inferior axis wide QRS tachycardia (Fig. 3).

Ambulatory ECG monitoring performed on the 8th and 29th day documented ST-segment elevation prior to onset of the wide QRS tachycardia (Fig. 4). Amiodarone therapy was effective and electrophysiological study showed no inducible ventricular tachycardia. Patient refused elective percutaneous coronary intervention and ergonovine or acetylcholine provocation test for coronary vasospasm.

Address for Correspondence/Yazışma Adresi: Bonpei Takase, MD, Department of Intensive Care Medicine, National Defense Medical College, 3-2 Namiki, Tokorozawa, Saitama, Japan, 359-8513, Phone: +81 42 9951597 Fax: +81 42 9250967 E-mail: bonpeit@ndmc.ac.jp and dui1577@db3.so-net.ne.jp

© Telif Hakkı 2009 AVES Yayıncılık Ltd. Şti. - Makale metnine www.anakarder.com web sayfasından ulaşılabilir.
© Copyright 2009 by AVES Yayıncılık Ltd. - Available on-line at www.anakarder.com

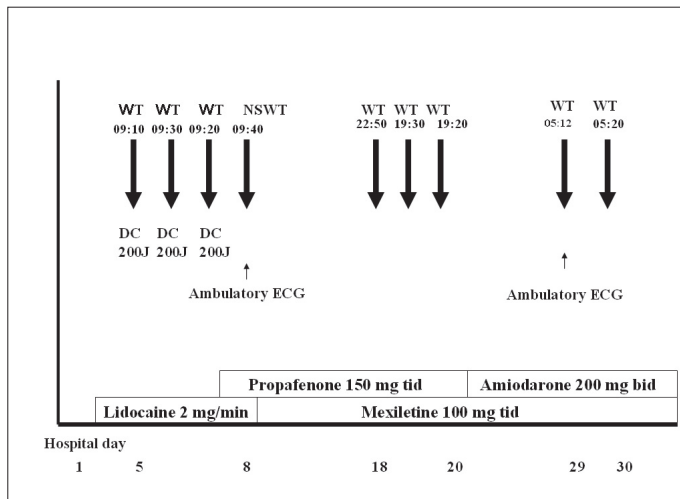


Figure 2. Clinical course after admission and management of periodic episodes of wide QRS tachycardia

DC - direct current defibrillation, NSWT - nonsustained wide QRS tachycardia, WT - wide QRS tachycardia, Mexiletine is substitute for Lidocaine

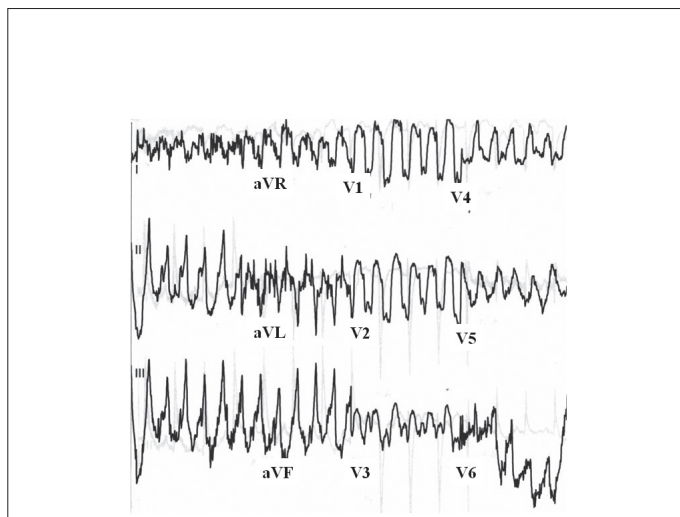


Figure 3. Monitoring of 12-lead ECG findings of wide QRS tachycardia (WT): left bundle branch block with inferior axis wide QRS tachycardia
ECG - electrocardiogram

Heart rate variability analysis was performed with commercial software (MemCalc/PRO, Suwa Trust Inc., Tokyo, Japan) using the two available ambulatory ECG monitoring recorded during tachycardia episodes. The power spectral density was calculated, including low frequency spectra (LF, 0.04-0.15 Hz), high frequency spectra (HF, 0.15-0.40 Hz), and the ratio of low frequency and high frequency spectra (LF/HF). LF and LF/HF were high on the night before onset of wide QRS tachycardia. Further, immediately before wide QRS tachycardia, there was a marked increase in HF (Fig. 5).

Discussion

This case demonstrates that the sympathetic nerve hyperactivity followed by marked vagal surge precedes periodic vasospasm complicated with lethal arrhythmias occurring early in the morning and that the phenomenon is reproducible in two available analysis of HRV. Thus, periodic occurrence of vasospasm-induced lethal arrhythmias in this patient may be associated with baseline vulnerability of autonomic nerve state in a day (the morning and evening).

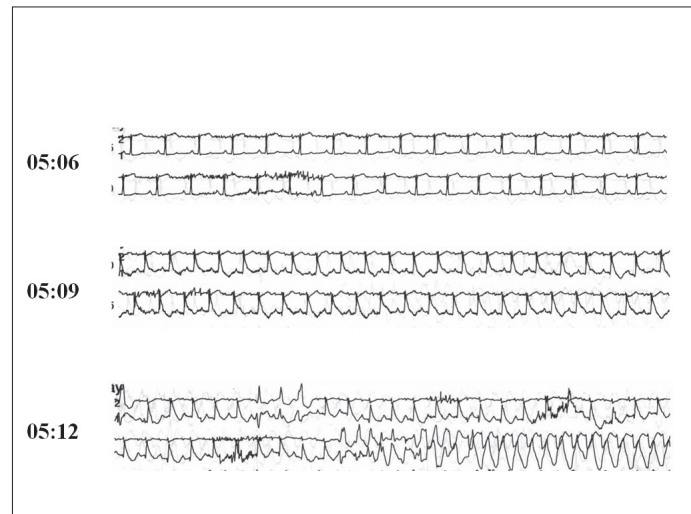


Figure 4. Ambulatory ECG reading on the 29th day: ST-segment elevation preceded these wide QRS tachycardia

ECG - electrocardiogram

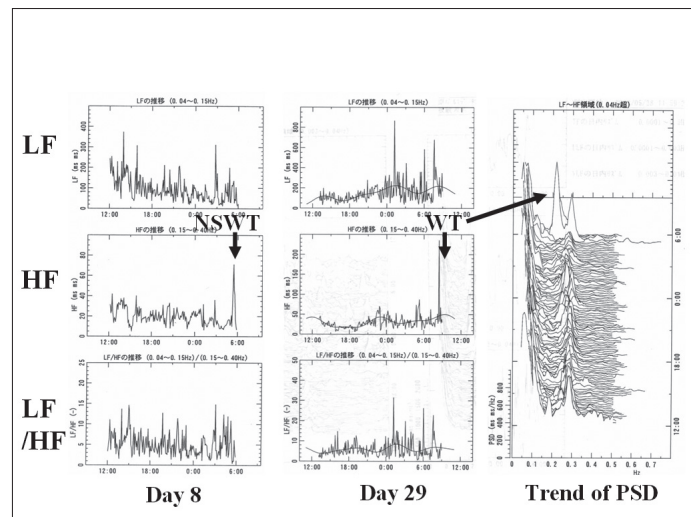


Figure 5. Changes in heart rate variability during nonsustained and sustained wide QRS tachycardia

NSWT - nonsustained wide QRS tachycardia, PSD - power spectral density of heart rate variability, WT - wide QRS tachycardia

Direct comparison between autonomic activity and occurrence of either vasospasm or lethal arrhythmias has not been investigated in the clinical settings because of the technical difficulty. HRV is a common modality that indirectly measures cardiac autonomic nerve activity. Some reports showed a marked increase in the sympathetic nerve activity indices of HRV whereas others reported increased vagal ones (3, 4). Increased vagal nerve activity can possibly trigger coronary artery vasospasm by causing abnormal endothelial function (5). In addition, an increase in vagal activity can trigger ventricular fibrillation in Brugada syndrome (6). The findings in this case agree with the earlier reports showing a typical diurnal pattern of lethal arrhythmias in MI (7-9).

Amiodarone therapy was considered to be successful even if the control (without amiodarone) electrophysiological study and electrophysiological study under the medication of amiodarone could not be directly compared because of the longer life time of amiodarone metabolism.

Conclusion

Heart rate variability may be a useful modality for understanding the pathophysiology of periodic lethal arrhythmias and for judging the efficacy of treatments. However, these findings should be duplicated and confirmed in larger cohort.

References

1. Pomeranz B, Macaulay RJ, Caudill MA, Kutz I, Adam D, Gordon D, et al. Assessment of autonomic function in humans by heart rate spectral analysis. *Am J Physiol* 1985; 248 (1 Pt 2): H151-3.
2. Sakata K, Yoshida H, Hoshino T, Kurata C. Sympathetic nerve activity in the spasm-induced coronary artery region is associated with disease activity of vasospastic angina. *J Am Coll Cardiol* 1996; 28: 460-4.
3. Miwa K, Igawa A, Miyagi Y, Nakagawa K, Inoue H. Alterations of autonomic nervous activity preceding nocturnal variant angina: sympathetic augmentation with parasympathetic impairment. *Am Heart J* 1998; 135: 762-71.
4. Yamagishi M, Ito K, Tsutsui H, Miyazaki S, Goto Y, Nagaya N, et al. Lesion severity and hypercholesterolemia determine long-term prognosis of vasospastic angina treated with calcium channel antagonists. *Circ J* 2003; 67: 1029-35.
5. Kawano H, Motoyama T, Yasue H, Hirai N, Waly HM, Kugiyama K, et al. Endothelial function fluctuates with diurnal variation in the frequency of ischemic episodes in patients with variant angina. *J Am Coll Cardiol* 2002; 40: 266-70.
6. Antzelevitch C, Brugada P, Borggreffe M, Brugada J, Brugada R, Corrado D, et al. Brugada syndrome: report of the second consensus conference: endorsed by the Heart Rhythm Society and the European Heart Rhythm Association. *Circulation* 2005; 111: 659-70.
7. Lombardi F, Porta A, Marzegalli M, Favale S, Santini M, Vincenti A, et al. Implantable Cardioverter Defibrillator-Heart Rate Variability Italian Study Group. Heart rate variability patterns before ventricular tachycardia onset in patients with an implantable cardioverter defibrillator. Participating Investigators of ICD-HRV Italian Study Group. *Am J Cardiol* 2000; 86: 959-63.
8. Tofler GH, Gebara OC, Mittleman MA, Taylor P, Siegel W, Venditti FJ Jr, et al. Morning peak in ventricular tachyarrhythmias detected by time of implantable cardioverter/defibrillator therapy. The CPI Investigators. *Circulation* 1995; 92: 1203-8.
9. Lucente M, Rebuzzi AG, Lanza GA, Tamburi S, Cortellessa MC, Coppola E, et al. Circadian variation of ventricular tachycardia in acute myocardial infarction. *Am J Cardiol* 1988; 62 (10 Pt 1): 670-4.

Aortic dissection provoked by electrical storm



Elektriksel fırtına nedeni ile gelişen aort disseksiyonu

Oladipupo Olafiranye, Louis Salciccioli, Jason M. Lazar

Division of Cardiovascular Medicine, State University of New York Downstate Medical Center, Brooklyn, New York, USA

Introduction

Acute aortic dissection is the most common catastrophe of the aorta. Although maneuvers that increase intra-thoracic pressure (ITP) have been reported to trigger aortic dissection, there is no report of aortic dissection in the setting of multiple automated implantable cardioverter defibrillator (AICD) shocks. We report and discuss the case of a man who developed aortic dissection following multiple AICD shocks.

Case report

A 76-year old man with a history of congestive heart failure (CHF) was brought to the emergency department after having multiple AICD shocks.

Two weeks earlier, the patient was admitted with shortness of breath and was found to be in CHF exacerbation and atrial fibrillation. He was treated medically. Transthoracic echocardiogram (TTE) and transesophageal echocardiogram (TEE) studies revealed a left ventricular ejection fraction of 20-25%, dilated atria, mild aortic

regurgitation, without evidence of thrombus or aortic dissection (Fig. 1. Video 1. See corresponding video/movie images at www.anakarder.com). He underwent dual chamber AICD (Medtronic Virtuoso DR) implantation with right ventricular defibrillation impedance of 29 ohms, pacing impedance of 392 ohms and threshold of 1 volt at 0.4 millisecond.

On this admission, he denied palpitations, chest pain, dizziness or loss of consciousness. He was alert and oriented, blood pressure (BP) was 142/88 mmHg and his heart rate was irregularly irregular at 132 beats/min. The rest of the physical examination was unremarkable. His electrocardiogram (ECG) revealed atrial fibrillation with a rapid ventricular response of 130 beats/min and left ventricular hypertrophy. Chest X-ray showed mild cardiomegaly. Laboratory tests were unremarkable.

On the 3rd hospital day, he experienced 3 episodes of AICD shocks accompanied by jerky movements that coincided with unsustained ventricular tachycardia on telemetry. Subsequently, his BP increased to 170-185/95-110 mmHg from baseline of 120-145/75-88 mmHg, and was difficult to control with multiple antihypertensive medications. Within 24 hours of the electrical storm, he complained of non-radiating pre-

Address for Correspondence/Yazışma Adresi: Jason M. Lazar, MD, State University of New York Downstate Medical Center 450 Clarkson Avenue, Box 1199 Brooklyn, NY 11203-2098 Phone: +001 7182215222 Fax: +001 7182215220 E-mail: Jason.lazar@downstate.edu

©Telif Hakkı 2009 AVES Yayıncılık Ltd. Şti. - Makale metnine www.anakarder.com web sayfasından ulaşılabilir.

©Copyright 2009 by AVES Yayıncılık Ltd. - Available on-line at www.anakarder.com