

Beta-blocker treatment in an adolescent with amitriptyline intoxication

Amitriptilin zehirlenmesi tanısı alan bir adölesanda beta-bloker tedavisi

Tamer Baysal, Bülent Oran, Mustafa Doğan, Derya Çimen, Şefika Elmas, Sevim Karaaslan

Department of Pediatrics, Section of Pediatric Cardiology, Meram Medical Faculty, Selçuk University, 42080, Konya, Turkey

Introduction

Amitriptyline is one of the major tricyclic antidepressants (TCA) (1). Among the antidepressants, TCAs have been the most common poisons used in suicide (2). Tricyclic antidepressants poisoning results in hypotension, cardiac dysrhythmia, depression of the central nervous system (CNS) and seizures, and is a major cause of death by poisoning in the UK (3). The most common cause of death after TCA overdose is myocardial depression with refractory hypotension, ventricular tachycardia, or ventricular fibrillation (4). Current therapy includes vasopressors for hypotension, sodium bicarbonate for dysrhythmias, and benzodiazepines for seizures (3). We report a case of a child who was successfully treated with beta-blocker in severe amitriptyline intoxication.

Case report

A 16-year old previously healthy girl was brought to our hospital with coma (Glasgow coma score 3). It was estimated that she took approximately 46 mg/kg of amitriptyline about 4 hours before admission. Her blood pressure was 90/50 mmHg, heart rate 180/min, respiration rate 28/min, and temperature 35.3 °C. She had generalized tonic-clonic seizures. Laboratory findings including total blood count, serum electrolytes, renal function tests, liver function tests were normal. Her chest radiography showed bilateral infiltration. Arterial pH was 7.25 with a serum bicarbonate concentration of 21.4 mmol/l. Plasma amitriptyline concentration of the girl was 3580 µg/l at the time of admission to our hospital. Electrocardiography (ECG) showed ventricular tachycardia with wide QRS (16 ms) complexes (Fig.1). She was monitored and intravenous isotonic solution (2000 ml/m²) infusion was started. We gave intravenous diazepam (a single dose of 10 mg) for seizures. Activated charcoal was administered via nasogastric tube. We started a dose of 2 mEq/kg sodium bicarbonate infusion as an initial therapy. Intravenous lidocaine was also given twice as a 1 mg/kg bolus followed by 20 µg/kg per min for treatment of ventricular tachycardia. As her ventricular tachycardia did not improve with these two drugs; we gave intravenous metoprolol tartrate, a selective beta-blocker, 2 times in a dose of 5 mg with about 15 minutes intervals. She had a very good clinical response, QRS duration returned to normal (8 ms) on her ECG tracing and no complication was observed (Fig. 2). Her mental status returned to normal on the 12th hour of her admittance. She was discharged from hospital on the 4th day after being visited by a child psychiatrist.

Discussion

Tricyclic-antidepressant poisoning causes more deaths than any other acute prescription drug poisoning (1, 5). Toxicity is encountered

at 10-30 mg/kg and fatality is possible at 50 mg/kg (6, 7). The most severe toxic effects of TCA poisoning are coma, seizures, dysrhythmia, and hypotension. While coma and seizures may be life threatening, they can usually be treated with standard therapies as in our case. However, the cardiovascular effects are often refractory to standard therapy and the ultimate cause of death (3, 4). In our case, we treated the patient successfully with standard therapy and beta-blocker.

Tricyclic-antidepressant overdose affects the cardiovascular, respiratory, autonomic, and central nervous systems. The toxic effects of tricyclics are caused by four main pharmacological properties: inhibition of norepinephrine reuptake at nerve terminals, direct alpha- adrenergic block, a membrane stabilizing or quinidine-like effect on the myocardium and anticholinergic action. Generally, anticholinergic effects do not cause serious clinical problems (8). The cardiovascular effects of TCA in the context of both therapeutic dosing and intentional drug overdose have been well documented. Tricyclic antidepressants act primarily on sodium (fast) channels but also on delayed rectifier potassium (IKr) channels. The sodium-channel-blocking effects of tricyclic antidepressants may diminish the effect of IKr blockade on the QT interval. Tricyclic antidepressants' capacity to block sodium (fast) channels cannot be the only mechanism explaining QT interval prolongation, but also block potassium channels (9). Thus, the most important toxic effect of TCAs is the slowing of depolarization of the cardiac action potential by inhibition of the sodium current and this delays propagation of depolarization through both myocardium and conducting tissue. This results in prolongation of the QRS complex and the PR/QT intervals with a predisposition to cardiac arrhythmias (8). Serum alkalization with sodium bicarbonate is the mainstay therapy for reversing rhythm disturbances (3). Increasing the blood pH causes conformational changes in sodium channels. Increasing the extracellular concentration of sodium may overcome the inhibition of

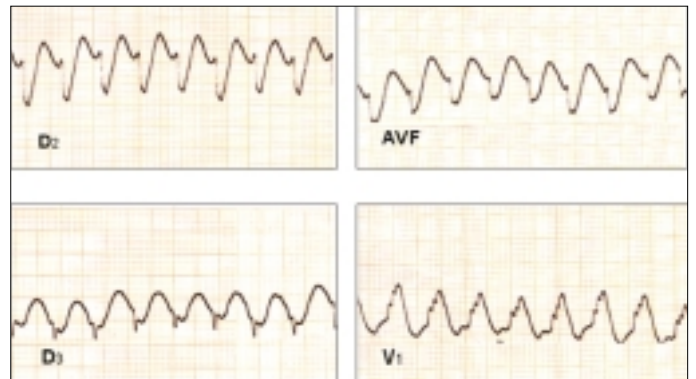


Figure 1. Electrocardiography shows ventricular tachycardia with wide QRS complexes at the time of admission.

sodium channels by TCA (6). The use of sodium bicarbonate in tricyclic poisoning has been shown to have beneficial effects (7).

In a review of 91 patients treated with sodium bicarbonate, hypotension was corrected in 20 of 21 patients (96%) within one hour and QRS prolongation was corrected in 39 of 49 patients (80%). The administration of hypertonic sodium chloride to rats with desipramine toxicity has been shown to be as effective as sodium bicarbonate in reversing QRS prolongation and hypotension (8). In the light of this knowledge, the first drug that we administered to our patient was sodium bicarbonate infusion, but it did not make any change in the cardiac rhythm. So, we gave lidocaine and beta-blocker to solve the problem.

Our patient's arrhythmia gave a good response to beta-blocker

therapy. In the literature, use of beta-blockers is reported as being effective in treating arrhythmias both in humans (8) and animals (10), but as a side effect, a marked decrease in blood pressure was reported in all cases. We did not record a marked decrease in our patient's blood pressure. It was either because she did not have hypotension or having been given intravenous isotonic crystalloid solution from the time of admittance.

Because our patient gave a good response to beta-blocker therapy, we suggest that selective beta-blockers may be an effective treatment modality in children with ventricular tachyarrhythmias, which is due to severe amitriptyline intoxication especially when there is no hypotension.

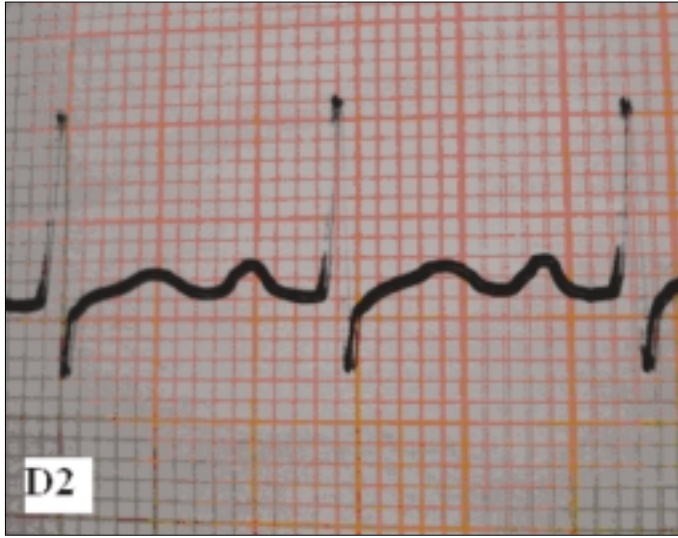


Figure 2. ECG tracing (D2) of the patient after the beta-blocker therapy
ECG- electrocardiogram

References

1. Rang H P, Dale M M, Ritter J M, editors. Pharmacology. New York: Churchill Livingstone; 1999.
2. Vieweg WV, Linker JA, Anum EA, Turf E, Pandurangi AK, Sood B, et al. Child and adolescent suicides in Virginia: 1987 to 2003. J Child Adolesc Psychopharmacol 2005; 15: 655-63.
3. Heard K, O'Malley GF, Dart RC. Treatment of amitriptyline poisoning with ovine antibody to tricyclic antidepressants. Lancet 1999; 354: 1614-5.
4. Dönmez O, Çetinkaya M, Canbek R. Hemoperfusion in a child with amitriptyline intoxication. Pediatr Nephrol 2005; 20: 105-7.
5. Prahlow J A, Landrum J E. Amitriptyline abuse and misuse. Am J Forensic Med Pathol 2005; 26: 86-8.
6. Vernon DD and Gleich MC. Poisoning and drug overdose. Crit Care Clin 1997; 13: 647-67.
7. Shanon M, Liebelt E L. Toxicology reviews: Targeted management strategies for cardiovascular toxicity from tricyclic antidepressant overdose: The pivotal role for alkalisation and sodium loading. Ped Emerg Care 1998; 14: 293-8.
8. Kerr GW, McGuffie AC, Wilkie S. Tricyclic antidepressant overdose: a review. Emerg Med J 2001; 18: 236-41.
9. Vieweg WVR, Wood MA. Tricyclic antidepressants, QT interval prolongation, and torsade de pointes. Psychosomatics 2004; 45: 371-7.
10. Brown TCK. Tricyclic antidepressant overdosage: Experimental studies on the management of circulatory complications. Clin Toxicol 1976; 9: 255-72.

Infective endarteritis in a 2-month-old infant associated with silent patent ductus arteriosus

Sessiz patent ductus arteriozus'lu 2 aylık bir çocukta infektif endarterit

Ahmet Çelebi, Abdullah Erdem, Haluk Çokuğraş*, Gülay Ahunbay**

Department of Pediatric Cardiology, Dr. Siyami Ersek Thoracic and Cardiovascular Surgery Center and Research Hospital
Departments of *Pediatric Cardiology and** Pediatric Infectious Disease, Cerrahpaşa Medical Faculty University of İstanbul, İstanbul, Turkey

Introduction

Infective endarteritis (IE), which was a serious complication of clinically apparent patent ductus arteriosus (PDA), has become extremely rare because of early closure of PDA (1-3). However, it is not known if silent PDA, which is not detectable by cardiac auscultation but can be recognized only by colored-flow echocardiography, increases the risk of IE or not (4). Thus, antibiotic prophylaxis or closure

of silent PDA against the risk of IE is not recommended (4-6). There are only a few reports of IE associated with silent PDA in medical literature (7, 8). In this article a case of IE in a 2 month-old infant with silent PDA is reported.

Case report

A 2-month-old male infant was hospitalized because of fever lasting for three days. His physical examination revealed 37.6 C° axil-