

Sea star coronary artery

Deniz yıldızı koroner arter

A 46-year-old female, who had a history of stable angina pectoris and hypertension was admitted to our hospital, because of worsening anginal symptoms. On admission, the electrocardiogram showed negative T waves and marked ST segment depression on leads DII-DIII and aVF with elevated cardiac biomarkers. An urgent coronary angiography was performed. There was no coronary artery on left selective coronary angiography. Right coronary angiography revealed that, all major coronary arteries were arising from the right aortic sinus with separate ostia, giving the appearance of a sea star (Fig. 1A and B, Video 1 and 2. See corresponding video/movie images at www.anakarder.com). Dominant right coronary artery (RCA) had significant (80%) stenosis on the proximal segment (Fig. 1B, arrow). An elective angioplasty was applied to RCA without any complication, which was followed by a 64-slice computed tomography (Fig. 1C) to define the complete anatomy and the course of the left anterior descending coronary artery (LAD).

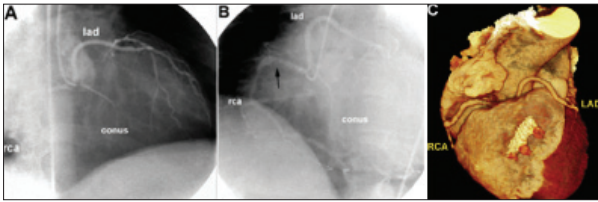


Figure 1. Coronary angiography (A, B) and multislice computed tomography (C) views of coronary arteries arising from the right aortic sinus with separate ostia

Arising of all coronary arteries from the right aortic sinus with separate ostia is a very rare entity. The risk of this coronary anomaly depends on the course of LAD. An LAD coursing between the aorta and the pulmonary artery is potentially responsible for myocardial ischemia and sudden death, while an LAD, coursing anterior to the right ventricle (like the presented case, C), or behind the aorta carries low risk for future adverse events. Multi-slice computed tomography is a new diagnostic modality and a reliable complementary tool for coronary angiography for defining coronary artery anomalies.

Akın İzgi, Bülent Mutlu, Cevat Kıрма, Zafer Kaya*
 Department of Cardiology, Koşuyolu Yüksek İhtisas
 Education and Research Hospital, İstanbul
 *Sonomed Cardiac Imaging Center, İstanbul, Turkey

Address for Correspondence/Yazışma Adresi: Dr. Akın İzgi
 Meriç Cad. Kardelen Blokları, 4/12, No:10, Ataşehir, Kadıköy, İstanbul, Türkiye
 Phone: +90 216 459 40 41/1146 Fax: +90 216 459 63 21 E-mail: draizgi@gmail.com

Uncommon course of sinus nodal artery: Is it a known pathway?

Sinus düğüm arterinin sık görülmeyen seyri: Bilinen bir yol mu?

A 69-year-old male, with a prior history of rheumatic valvular disease, presented with dyspnea. Echocardiography revealed severe mitral stenosis with a valve area 0.9 cm² and severe left atrial dilatation (11cm). Coronary angiography demonstrated normal coronary arteries but severe mitral stenosis was visualized on cardiac catheterization. Coronary

angiography (30° right anterior oblique, 35° caudal and 60° left anterior oblique projections of the left coronary system) demonstrated a rare anatomical variation, in which the sinus node artery had a long course originating from the distal part of the left circumflex artery below or behind the left auricle (Fig. 1; Video 1. See corresponding video/movie images at www.anakarder.com), and coursing in counter-clockwise direction postero-superiorly with a reverse U- shape to the territory of the sinus node (Fig. 2; Video 2A,2B. See corresponding video/movie images at www.anakarder.com). No other accessory nodal artery was visualized.

The sinus node is usually supplied by the sinoatrial branch via the right coronary artery in 55% of cases and via the left circumflex artery in 45 % of cases.

We describe herein a rare and unusual variation, found in a patient with severe mitral stenosis and left atrial dilatation, in which a posterior sinus node artery originate from the posterior segment of the circumflex artery, coursed postero-superiorly and entered the sinus node from superiorly. Although abnormal course of sinus nodal artery may be an anatomical variation, it could partly be considered that severe dilatation of the left atrium led to abnormal course of posterior sinus node artery.

**Hasan Kocatürk, Mehmet Cengiz Çolak, Abdürrezzak Börekçi,
 Ednan Bayram*, Sebahattin Ateşal****
 Cardiology Service, Şifa Hospital, Erzurum
 *Cardiology Service, Numune Hospital, Erzurum
 **Department of Cardiology, Faculty of Medicine,
 Atatürk University, Erzurum, Turkey

Address for Correspondence/Yazışma adresi: Dr. Hasan Kocatürk
 Osman bektaş mah. Sekili sok. Osmanlılar apart. A blok 3/5
 25070 Erzurum, Turkey
 Phone: +90.442.329 00 00 Fax: +90.442.329 04 20 E-mail: haskturk@hotmail.com

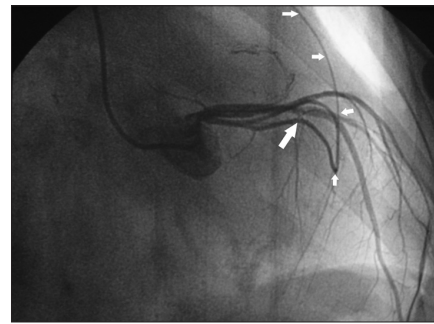

Figure 1. Figure shows sinus node artery (small white arrows) originating from distal circumflex artery (big white arrow)

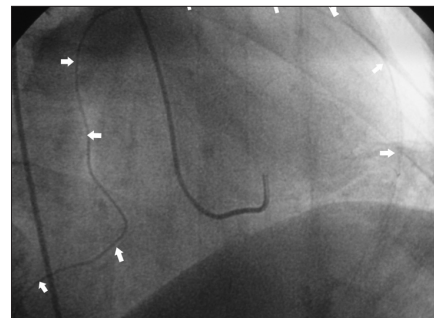


Figure 2. Arrows indicate abnormal course of posterior sinus nodal artery with reverse U-shape