

GuideLiner catheter application in complex coronary lesions: experience of two centers

Hüseyin Dursun, Ahmet Taştan¹, Zülkif Tanrıverdi², Erdem Özel¹, Dayimi Kaya

Department of Cardiology, Faculty of Medicine, Dokuz Eylül University; İzmir-Turkey

¹Department of Cardiology, Faculty of Medicine, Şifa University; İzmir-Turkey

²Clinic of Cardiology, İdil State Hospital; Şırnak-Turkey

ABSTRACT

Objective: GuideLiner catheter provides adequate back-up support and a coaxial guide engagement for stent delivery in complex coronary anatomies. In this study, we aimed to present one of the largest series of experience with GuideLiner catheter utilized for challenging percutaneous coronary interventions in two centers.

Methods: We retrospectively collected the coronary angiography records of 64 patients between January 1, 2012 and August 1, 2014 in whom conventional techniques failed for stent delivery and 5-in-6 Fr GuideLiner catheter was used for this purpose. The data were assessed in terms of the lesion characteristics, procedural success, and complications. Descriptive statistics and frequencies were used in statistical analyses.

Results: The mean age of the patients was 69.8±10.0 years. Femoral approach was employed in all cases. Lesions were mostly (90.6%) class B2 or C according to the AHA/ACC lesion classification. The GuideLiner catheter was mainly used to increase back-up of the guide catheter (85.9%), and in 95.3% of all cases, the procedure was successful. The mean depth of the GuideLiner catheter intubation was 30.3±21.6 mm. None of the patients had coronary dissection or major complications.

Conclusion: In this study, we presented a large registry of two centers used the GuideLiner catheter. The device effectively allowed stent delivery in challenging lesions, where conventional techniques have failed, without major complications. (*Anatol J Cardiol* 2016; 16: 333-9)

Keywords: percutaneous coronary intervention, complex lesions, GuideLiner catheter

Introduction

The back-up support of the guide catheter is a crucial step in complex percutaneous coronary interventions (PCI) particularly in the case of severe calcification and tortuosity. In such lesions, failure of the stent delivery still continues to be a major problem occurring in up to 5% cases (1, 2). Using more supporting guide catheters with deep intubation, straightening the artery with a second buddy wire or anchoring balloons, and modifying with rotational atherectomy are strategies to overcome these obstacles (3, 4).

The GuideLiner catheter (Vascular Solutions Inc., Minneapolis, MN, USA) is a coaxial guide extension. Its monorail structure provides easy handling and does not require disconnection of the hemostatic valve (5-7). The soft distal tip has a low risk of dissecting vessels. It has been utilized in both femoral and radial approaches for complex coronary and graft or peripheral interventions, as demonstrated in one case of renal artery stenosis (8-10).

This catheter is mainly used for two indications in clinical practice: deep intubation for improving back-up guide catheter support and coaxial alignment in case of a difficult coronary ostium take off. Furthermore, it has been used for many other applications such as selective visualization of target vessels, thrombus aspiration in acute myocardial infarction, guiding catheter exchange over a coronary wire, and delivering rotational atherectomy burrs in tortuous vessels (11-15).

The purpose of this study was to present the experience of two centers with the GuideLiner catheter in terms of the lesion characteristics, procedural success, and complications.

Methods

We retrospectively selected a consecutive series of patients who underwent complex PCI with the use of the GuideLiner catheter between January 1, 2012 and August 1, 2014 in two centers. The patients presented with stable angina or acute

Address for Correspondence: Dr. Hüseyin Dursun, Dokuz Eylül Üniversitesi Tıp Fakültesi, Kardiyoloji Anabilim Dalı, 35420, Balçova/İzmir-Türkiye

Phone: +90 505 719 21 50 Fax: +90 232 433 07 56 E-mail: drhuseyindursun@gmail.com

Accepted Date: 28.04.2015 **Available Online Date:** 18.06.2015

The study was done in Cardiology Departments of Dokuz Eylül University and Şifa University, İzmir, Turkey.

©Copyright 2016 by Turkish Society of Cardiology - Available online at www.anatoljcardiol.com
DOI:10.5152/AnatolJCardiol.2015.6214



coronary syndromes. The PCI procedures were performed according to standard clinical protocols via the femoral route; there was no crossover from radial approach. Standard Judkins left or right guiding catheters were used in all procedures. In cases where conventional techniques failed, the 5-in-6 Fr GuideLiner catheter was used for stent delivery instead of using more supporting guiding catheters that will also have a higher risk of dissection. We recorded various clinical and procedural data of these patients: age, target vessel, lesion characteristics, types of stents, the indication for GuideLiner use, vessel intubation depth, and procedural and device success with complications. Each lesion in the epicardial coronary artery was classified as Type A, B1, B2, and C according to the definition by the American Heart Association/American College of Cardiology (AHA/ACC) (16). Coronary tortuosity was identified by the finding of ≥ 3 bends (defined as $\geq 45^\circ$ change in vessel direction) along the main trunk of at least one artery that is present in both the systole and diastole. Calcification was recorded based on the density as visualized in the wall of the vessel before injecting the contrast dye (17). The success of the procedure was defined as the achievement of $< 20\%$ diameter stenosis with TIMI 3 flow in the target vessel (18).

Statistical analysis

Statistical analysis was performed using SPSS for Windows version 22.0 (SPSS Inc., Chicago, IL, USA). Continuous variables were expressed mean \pm standard deviation, and categorical data were recorded as percentage.

Results

The GuideLiner catheter was used for 64 patients with a mean age of 69.8 ± 10.0 years. Lesion characteristics, procedural details, and complications are shown in Table 1. Nine 14.1% patients presented with acute myocardial infarction (four with ST elevation myocardial infarction). The primary indications for the use of the GuideLiner were to increase the back-up of the guide catheter in 85.9% of the cases and to improve the coaxial alignment of the guide catheter in the remaining cases.

The target vessel was the right coronary artery (RCA) in 46.9%, left circumflex artery (LCX) in 25%, left anterior descending artery in 21.9%, saphenous vein graft (SVG) in 4.7%, and left main coronary artery (LMCA) in 1.6% of patients. Most of the lesions were class B2 or C (90.6%) according to the AHA/ACC lesion classification. The Guideliner was used in 55 cases (85.9%) for back-up support (22 cases with heavy calcification, 14 cases with proximal tortuosity, five cases of CTO, three cases of SVG, and 11 cases that were not included in previously defined lesion types but required back-up support) and in the remaining nine cases (14.1%) to improve coaxial alignment.

Successful stent implantation was performed in 95.3% of the cases. The mean width and length of the stents were 2.9 ± 0.4 mm and 20.0 ± 5.5 mm, respectively. Stent failure occurred in three

Table 1. Lesion characteristics, procedural details, and complications

Access type, n (%)	
Femoral	64 (100)
Target vessel, n (%)	
LAD	14 (21.9)
LCX	16 (25)
RCA	30 (46.9)
SVG	3 (4.7)
LMCA	1 (1.6)
Lesions type, n (%)	
A/B1	6 (9.4)
B2/C	58 (90.6)
Severe calcification	22 (34.4)
Proximal tortuosity	14 (21.9)
Chronic total occlusion	5 (7.8)
Stent width, mm	2.9 ± 0.4
Stent length, mm	20.0 ± 5.5
Stent type, n (%)	
BMS	35 (54.7)
DES	26 (40.6)
Depth of intubation, mm	30.3 ± 21.6
Primary indication, n (%)	
Back-up support	55 (85.9)
Alignment of the guide	9 (14.1)
Procedural success, n (%)	61 (95.3)
Stent failure, n (%)	3 (4.7)
Complications, n (%)	
Major complication	0
Coronary dissection	0
Minor complication	1 (1.6)
BMS - bare metal stent; DES - drug eluting stent; LAD - left anterior descending artery; LCX - left circumflex artery; LMCA - left main coronary artery; RCA - right coronary artery; SVG - saphenous vein graft	

(4.7%) patients. Of these cases, two were very proximal lesions of RCA in which the GuideLiner could not be properly advanced and one was an LCX lesion with excessive calcification in which the GuideLiner was successfully engaged; however, the stent could not be delivered despite multiple attempts.

The GuideLiner was successful in 62 cases (96.9%). The mean depth of intubation was 30.3 ± 21.6 mm. (min. 8 mm, max. 110 mm). None of the patients had coronary dissection because of the GuideLiner catheter. In one patient, a 4.5-mm-sized bare metal stent (BMS) was stripped off its delivery balloon and became deformed while advancing it from the GuideLiner metallic collar segment. In that case, the stent could be easily removed back by inflating the stent balloon, and a new stent of 4.0-mm size was successfully implanted.

Discussion

In our retrospective study, the use of the GuideLiner catheter represented a considerable success (96.9%) with low rates of complications in patients with complex coronary anatomy, including heavy calcification, severe tortuosity, CTO, and abnormal ostial origin. To our knowledge, this is one of the largest experiences reported with this device.

In complex PCI using high-support guiding catheters, stiffer guidewires, anchoring balloons, and modification with rotational atherectomy are some of the examples of alternative strategies to enhance procedural success (3, 4). In this study, the GuideLiner catheter was used in the first place when standard Judkins guiding catheters failed to provide adequate back-up support instead of using guiding catheters with not only higher back-up support but also with higher risk of coronary dissection. The high procedural success (95.3%) in our registry is consistent with previous studies. Twente GuideLiner registry (18) reported a procedural success rate of 93% in 65 patients, whereas Chan et al. (10) reported a rate of 98% in 55 patients. This may be

explained by increased back-up support with deep intubation of the GuideLiner catheter into the target vessel. Takahashi et al. (19) have previously reported that deep intubation of the target vessel provided a significant increase in the back-up support and that the increase was positively correlated with the depth of intubation. In Twente registry, the mean intubation depth was 33 ± 21 mm, and in our study, it was found to be 30.3 ± 21.6 mm. Intervention of SVG is an example where deep intubation could be beneficial in which the conventional techniques could not provide enough back-up support and the cannulation is difficult as shown in Figure 1. The GuideLiner catheter has been previously reported to be successfully used in complex SVG lesions (6, 20). In our registry, successful stent implantation occurred in three SVG lesions without any complication.

In the case of vessel tortuosity and severe calcification, where the delivery of long stents is very difficult, the GuideLiner was effectively used (Fig. 2, 3). With the advance of hydrophilic and flexible structure, the GuideLiner catheter atraumatically increased the back-up support and provided stent delivery without any damage to the stent.

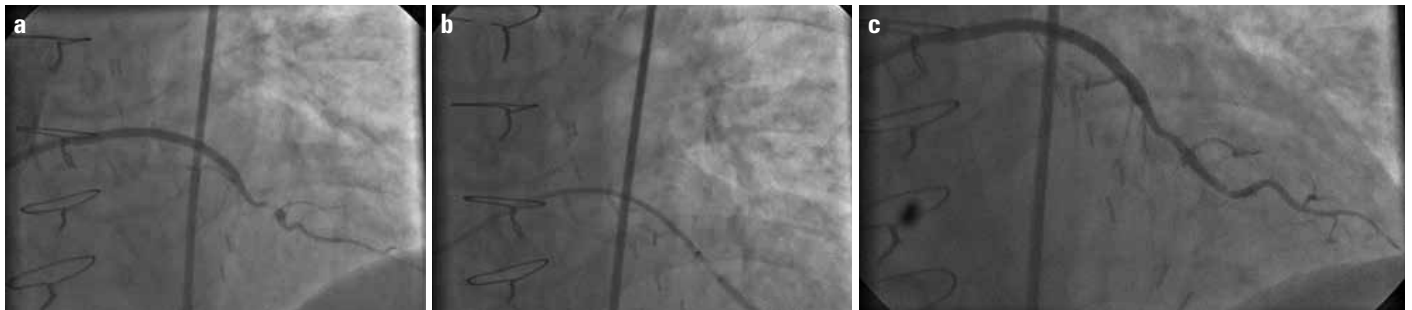

Figure 1. a–c. (a) Coronary angiography showing a patent saphenous vein graft (SVG) to the diagonal artery with a stenosis of 99% distal to anastomosis. (b) Deep intubation of the GuideLiner catheter into SVG and subsequent 2.5×11 mm stent implantation. (c) Final angiographic result without complication

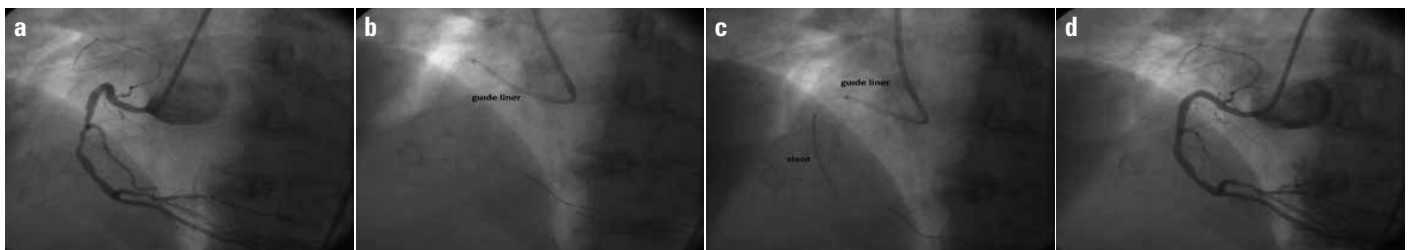


Figure 2. a–d. (a) Coronary angiography showing a tortuous RCA proximally followed by a mid 80% stenosis. (b) Deep intubation of tortuous segment with GuideLiner. (c) The GuideLiner enabled the stent delivery. (d) Final angiographic result

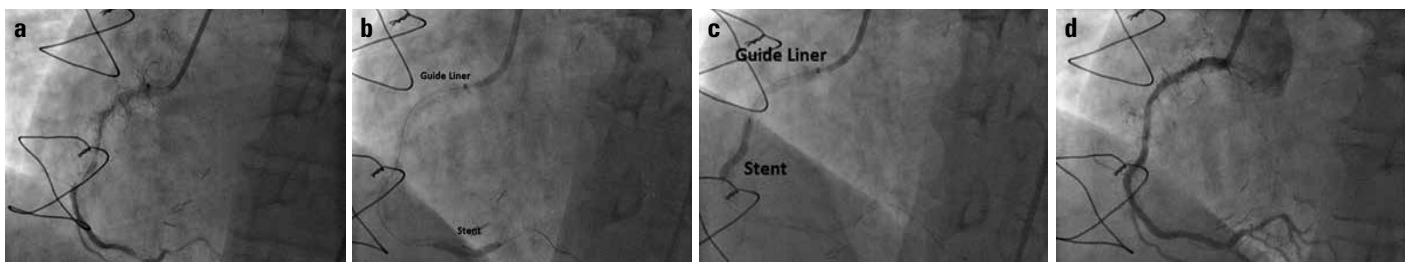


Figure 3. a–d. (a) Coronary angiography showing a severely calcified 80% instant restenosis at proximal RCA followed by another instant 95% restenosis at mid RCA and 99% stenosis proximal to PDA. (b) Deployment of the GuideLiner beyond the guide. (c) Successful stent implantation. (d) Coronary angiography after the procedure

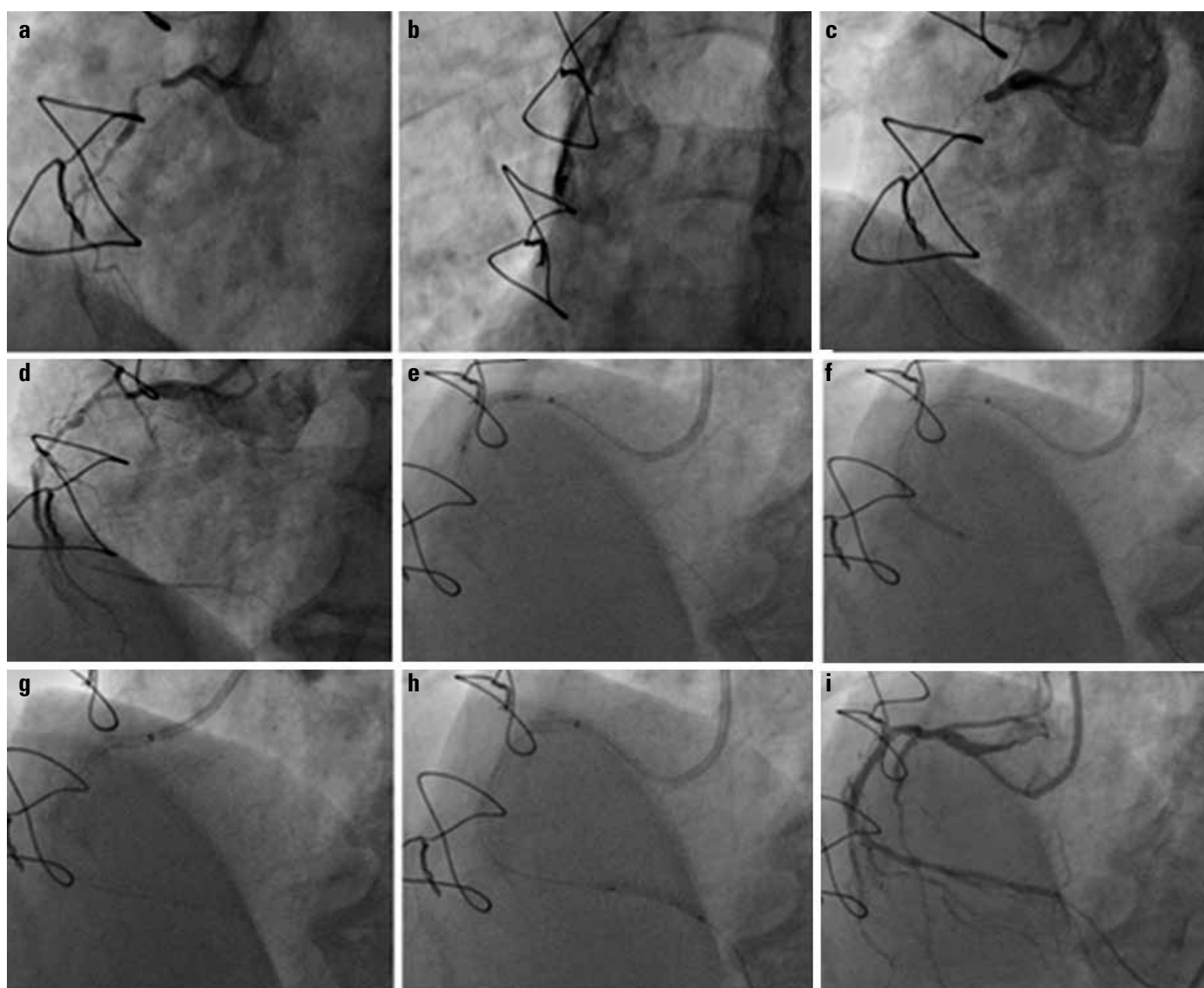


Figure 4. a–i. (a) Coronary angiography showing a RCA with a proximal 98% stenosis followed by CTO at mid portion. (b) Osteal occlusion of SVG anastomosed to RCA. (c, d) Balloon predilatation of the proximal RCA lesion however stent could not be delivered. (e) The GuideLiner deployment at irregular ostium, thus improving the coaxial alignment and the back-up support of the guide. (e, f) Balloon predilatation to proximal and mid lesions G: Stent implantation to proximal lesion. (h) Advancing of the GuideLiner within the proximal stent followed by distal stent implantation (proximal to distal stent implantation). (i) Final angiographic result without complication

The intervention of CTO remains one of the main difficulties in PCI. The GuideLiner catheter has been effectively utilized for antegrade as recently described for retrograde approach in reverse CART technique (21). Chan et al. (10) reported 21 (38%) patients with CTO, and only one of these cases failed. In our study we successfully treated five CTO lesions. In one of these cases, the stent was first implanted in the proximal lesion because it could not be initially delivered to distal lesion. The treatment of the proximal disease allowed deep intubation of the device and stenting of the distal lesion (Fig. 4). Use of the GuideLiner catheter (proximal to distal stent) appears to be of considerable advantage particularly in patients with proximal and distal complex coronary lesions (6). This technique may be used as a first choice in such lesions.

The GuideLiner catheter may allow coaxial guide orientation in the case of irregular RCA ostium. Despite the choice of appropriate guide catheter, the friction between the stent and vessel wall decreased the back-up support and caused difficulty in the stent delivery to distal lesions. Graidis et al. (22) reported a successful stent implantation in an anomalous origin of RCA lesion with the GuideLiner catheter and suggested increased procedural success by providing coaxial guide orientation in such lesions. In our study, the GuideLiner catheter was successfully employed to coaxially engage the irregular ostium of RCA in nine cases; one of them is demonstrated in Figure 5.

One of the main complications of the use of the GuideLiner is coronary dissection due to the deep intubation of the catheter particularly in excessively calcified, tortuous, and CTO lesions.

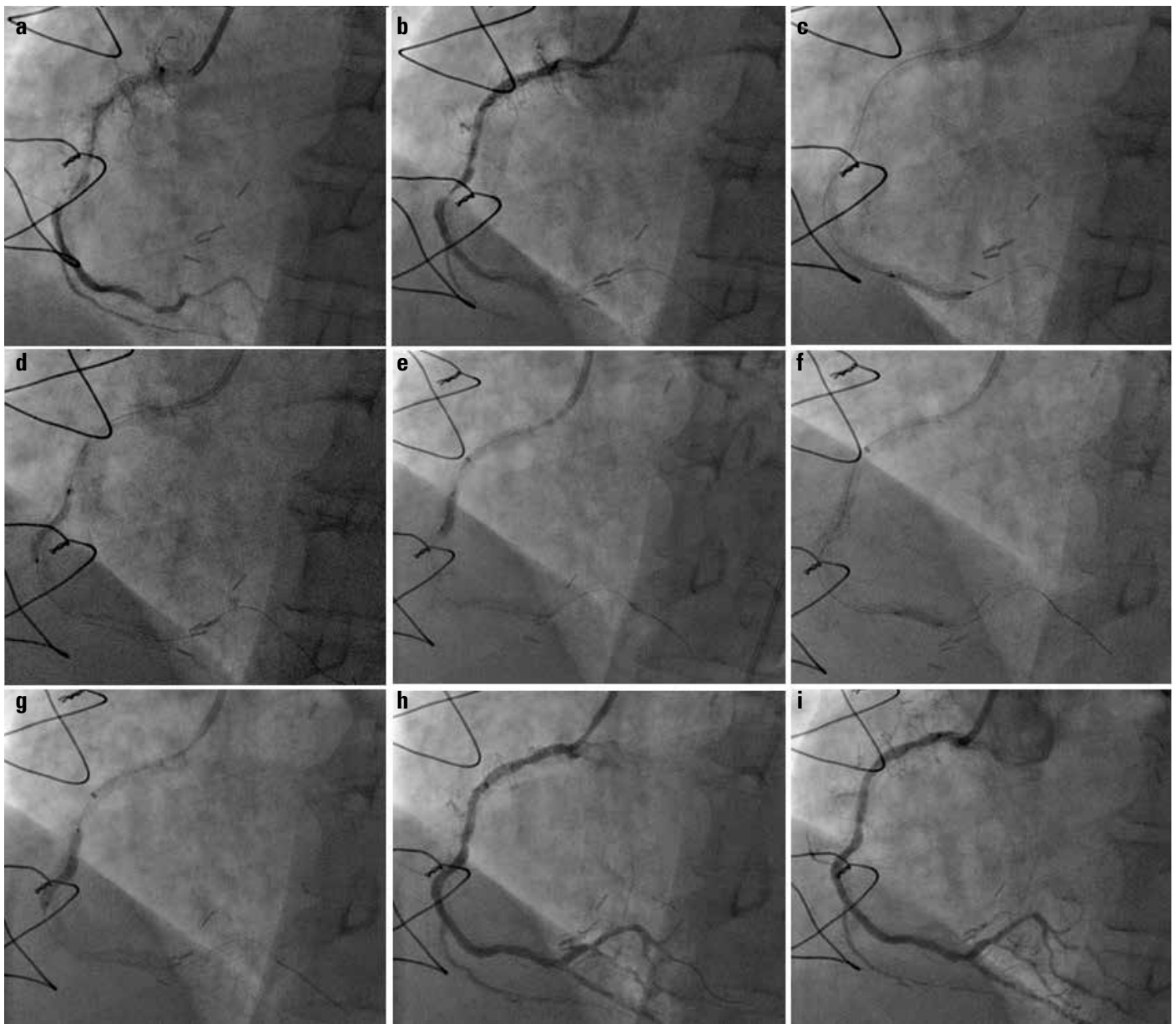


Figure 5. a–i. (a) Coronary angiography showing a RCA with mid and distal 99% of calcified, tortuous stenosis. (b–e) Balloon predilatation to distal and proximal lesions after deployment of the GuideLiner. (f, g) Successful stent implantation of the lesions. (h, i) Final result without any complication

The presence of proximal disease and small vessel diameter also pose a higher risk of dissection and even contraindicate the use of the GuideLiner. Luna et al. (20) used the GuideLiner of 7F in 21 complex coronary lesions with an average intubation depth of 38 ± 25 mm and reported coronary dissection only in one patient. In other registries, Dardas et al. (23) reported coronary dissection in two of the 16 patients (mean intubation depth: 55.9 mm), and Cola et al. (7) reported three of the 10 patients (mean intubation depth: 40.6 ± 25.6 mm). In our registry, the mean intubation depth was 30.3 ± 21.6 mm and possibly due to this relatively smaller intubation depth, none of the patients had coronary dissection. The other complications related with the GuideLiner are local air embolism, perforation of vessel wall, vascular occlu-

sion, and myocardial infarction that did not occur in any of the patients (18, 23, 24).

The GuideLiner catheter was reported to enable the passage of large profile devices. Bioresorbable vascular scaffolds (BVS) of all sizes can be delivered through the 6-in-7 Fr GuideLiner; however, maximum diameter of BVS is 3.0 mm that can be used through the 5-in-6 Fr GuideLiner. For the rotablator burrs, 1.25- to 1.5-mm burrs were reported to be delivered through the 6-in-7 Fr GuideLiner (15, 25). Several registries described damaged large/bulky stents (0.7%–6.3%) at the site of the metallic collar of the GuideLiner catheter, and it was recommended that the use of >4 mm diameter stents be avoided (6, 18, 24). Furthermore, dislodgement of the distal cylinder of the GuideLiner during several

attempts of removing a balloon has been reported (26). In our registry, one (1.6%) case with a 4.5-mm-sized BMS could not pass through the metallic collar part of the GuideLiner catheter; therefore, stent deformity occurred, and the stent was stripped off its delivery balloon. In case of resistance during the passage of balloon at the site of the metallic collar retrieval of the device, placing the collar in a more straight segment of the guide, controlling the metallic collar, and carefully examining the stent struts under fluoroscopy have been recommended (7, 10, 18, 24). In our practice, we routinely examine this region of the GuideLiner catheter under fluoroscopy during the passage of all stents. The risk for device deformation during attempts to advance through the Guideliner cylinder will probably be minimized in the near future since the next generation GuideLiner catheter is now available.

We have three (4.7%) stent implantation failures (two cases with very proximal lesions of RCA and one case with excessive calcification at LCX) all of which cannot be attributed to the GuideLiner catheter. A suitable proximal segment for intubation is recommended in the use of the GuideLiner (18). We predicted failure in ostial/very proximal cases; however, we wanted to increase the back-up support with low risk of dissection. These lesions of RCA in our registry were not aorto-ostial lesions; they were very proximal lesions. Device failure rates of ostial or very proximal lesions have been known to be high; however, there are successful cases reported in literature demonstrating stent implantation without any coronary dissection (24). Our case of LMCA was a protected LMCA lesion because the patient had an intact LIMA graft. It was in the distal LMCA, including the proximal part of CX with a sharp angle. The GuideLiner provided adequate back-up with successful stent delivery.

Study limitations

In this study, only the femoral route for PCI with the 5-in-6 Fr GuideLiner was used; therefore, the described efficacy, safety, and limitations considering the device only involves that route of intervention with that size of device. Using the radial approach and/or the larger sizes may exhibit different results. Furthermore, we have no experience with the next generation GuideLiner catheters in which the metal transition zone has been replaced by lubricious polymer.

This study was designed as a retrospective study, and the cine acquisition method was used for measurements. Thus, the GuideLiner may have deeper engagement during some periods of the intervention, and vessel intubation depth could be slightly more than reported. In conclusion, our study is still a relatively small-sized study with respect to the current daily volume of PCIs. Larger-sized randomized trials need to be designed with regard to this issue.

Conclusion

Our experience with the GuideLiner catheter demonstrated that this device safely and effectively facilitates stent delivery in

complex coronary interventions where conventional techniques have failed. We suggest that all operators need to be familiar to this catheter, and in such challenging cases, the use of the GuideLiner catheter should come to mind. With the advancements in device technology this catheter will probably be used more commonly in clinical practice.

Conflict of interest: None declared.

Peer-review: Externally peer-reviewed.

Authorship contributions: Concept - H.D., A.T., Z.T., E.Ö., D.K.; Design - H.D., A.T., Z.T., E.Ö., D.K.; Supervision - H.D., A.T., Z.T., E.Ö., D.K.; Research - H.D., A.T., Z.T., E.Ö., D.K.; Materials - H.D., A.T., Z.T., E.Ö., D.K.; Data collection &/or processing - H.D., A.T., Z.T., E.Ö., D.K.; Analysis and/or interpretation - H.D., A.T., Z.T., E.Ö., D.K.; Literature search - H.D., A.T., Z.T., E.Ö., D.K.; Writing - H.D., A.T., Z.T., E.Ö., D.K.; Critical review - H.D., A.T., Z.T., E.Ö., D.K.

References

1. Morice MC, Colombo A, Meier B, Serruys P, Tamburino C, Gualquimi G, et al; REALITY Trial Investigators. Sirolimus vs Paclitaxel eluting stents in de novo coronary artery lesions. *JAMA* 2006; 295: 895-904.
2. Nikolsky E, Gruberg L, Pechersky S, Kapeliovich M, Grenadier E, Amikam S, et al. Stent deployment failure: reasons, implications, and short- and long-term outcomes. *Catheter Cardiovasc Interv* 2003; 59: 324-8. [\[Crossref\]](#)
3. Jafari FH. When one won't do it, use two-double "buddy" wiring to facilitate stent advancement across a highly calcified artery. *Catheter Cardiovasc Interv* 2006; 67: 721-3. [\[Crossref\]](#)
4. Mezilis N, Dardas P, Ninios V, Tsikaderis D. Rotablation in the drug eluting era: immediate and long-term results from a single center experience. *J Interv Cardiol* 2010; 23: 249-53. [\[Crossref\]](#)
5. Rao U, Gorog D, Syzguna J, Kumar S, Stone C, Kukreja N. The GuideLiner "child" catheter. *EuroIntervention* 2010; 6: 277-9.
6. Mamas MA, Fath-Ordoubadi F, Fraser DG. Distal stent delivery with GuideLiner catheter: first in man experience. *Catheter Cardiovasc Interv* 2010; 76: 102-11. [\[Crossref\]](#)
7. Cola C, Miranda F, Vaquerizo B, Fantuzzi A, Bruquera J. The GuideLiner™ catheter for stent delivery in difficult cases: tips and tricks. *J Interv Cardiol* 2011; 24: 450-61. [\[Crossref\]](#)
8. García-Blas S, Núñez J, Mainar L, Miñana G, Bonanad C, Racugno P, et al. Usefulness and Safety of a Guide Catheter Extension System for the Percutaneous Treatment of Complex Coronary Lesions by a Transradial Approach. *Med Princ Pract* 2015; 24: 171-7.
9. Eddin MJ, Armstrong EJ, Javed U, Rogers JH. Transradial interventions with the GuideLiner catheter: role of proximal vessel angulation. *Cardiovasc Revasc Med* 2013; 14: 275-9. [\[Crossref\]](#)
10. Chan PH, Alegria-Barrero E, Foin N, Paulo M, Lindsay AC, Viceconte N, et al. Extended use of the GuideLiner in complex coronary interventions. *Eurointervention* (serial online) 2014 June. Available from: http://www.pcronline.com/eurointervention/ahead_of_print/201406-02/
11. Farooq V, Mamas MA, Fath-Ordoubadi F, Fraser DG. The use of a guide catheter extension system as an aid during transradial percutaneous coronary intervention of coronary artery bypass grafts. *Catheter Cardiovasc Interv* 2011; 78: 847-63. [\[Crossref\]](#)

12. Papayannis AC, Michael TT, Brilakis ES. Challenges associated with use of the GuideLiner catheter in percutaneous coronary interventions. *J Invasive Cardiol* 2012; 24: 370-1.
13. Stys AT, Stys TP, Rajpurohit N, Khan MA. A novel application of GuideLiner catheter for thrombectomy in acute myocardial infarction: a case series. *J Invasive Cardiol* 2013; 25: 620-4.
14. Stys TP, Khan MA, Rajpurohit N, Stys AT. A new technique for coronary guide catheter exchange over coronary guidewire using GuideLiner catheter. *J Invasive Cardiol* 2014; 26: E56-8.
15. Vo M, Minhas K, Kass M, Ravandi A. Novel use of the guideliner catheter to deliver rotational atherectomy burrs in tortuous vessels. *Case Rep Cardiol (serial online)* 2014 July. Available from: <http://dx.doi.org/10.1155/2014/594396>.
16. Ryan TJ, Faxon DP, Gunnar RM, Kennedy JW, King SB 3rd, Loop FD, et al. Guidelines for percutaneous transluminal coronary angioplasty. A report of the American College of Cardiology/American Heart Association Task Force on Assessment of Diagnostic and Therapeutic Cardiovascular Procedures (Subcommittee on Percutaneous Transluminal Coronary Angioplasty). *Circulation* 1988; 78: 486-502. **[Crossref]**
17. Zaacks SM, Allen JE, Calvin JE, Schaer GL, Palvas BW, Parrillo JE, et al. Value of the American College of Cardiology/American Heart Association stenosis morphology classification for coronary interventions in the late 1990s. *Am J Cardiol* 1998; 82: 43-9. **[Crossref]**
18. de Man FH, Tandjung K, Hartmann M, Houwelingen GV, Stoel MG, Louwerenburg HW, et al. Usefulness and safety of the GuideLiner catheter to enhance intubation and support of guide catheters: insights from the Twente GuideLiner registry. *EuroIntervention* 2012; 8: 336-44. **[Crossref]**
19. Takahashi S, Saito S, Tanakak S, Miyashita Y, Shiono T, Arai F, et al. New method to increase a backup support of a 6 French guiding coronary catheter. *Catheter Cardiovasc Interv* 2004; 63: 452-6.
20. Luna M, Papayannis A, Holper EM, Banerjee S, Brilakis ES. Transfemoral use of the GuideLiner catheter in complex coronary and bypass graft interventions. *Catheter Cardiovasc Interv* 2012; 80: 437-46. **[Crossref]**
21. Mozid AM, Davies JR, Spratt JC. The utility of a GuideLiner™ catheter in retrograde percutaneous coronary intervention of a chronic total occlusion with reverse cart-the "capture" technique. *Catheter Cardiovasc Interv* 2014; 83: 929-32. **[Crossref]**
22. Graidis C, Dimitriadis D, Karasavvidis V. GuideLiner catheter facilitated percutaneous coronary artery intervention of an anteriorly displaced and heavily calcified right coronary artery. *J Invasive Cardiol* 2012; 24: E222-4.
23. Dardas PS, Mezilis N, Ninios V, Tsikaderis D, Theofilogiannakos EK. The use of the GuideLiner™ catheter as a child-in-mother technique: an initial singer-center experience. *Heart Vessels* 2012; 27: 535-40. **[Crossref]**
24. Murphy JC, Spence MS. GuideLiner catheter-friend or foe? *Catheter Cardiovasc Interv* 2012; 80: 447-50. **[Crossref]**
25. Seth A, Ravisekar V, Kaul U. Use of 'Guideliner' catheter to overcome failure of delivery of Absorb™ Bioresorbable Vascular Scaffold in calcified tortuous coronary lesions: technical considerations in 'Real World Patients'. *Indian Heart J* 2014; 66: 453-8.
26. Bhat T, Baydoun H, Tamburino F. A unique complication with use of the GuideLiner catheter in percutaneous coronary interventions and its successful management. *J Invasive Cardiol* 2014; 26: E42-4.