

A Unique Association: Maffucci Syndrome and Cardiac Pathology

INTRODUCTION

Maffucci syndrome, also known as dyschondrodysplasia with hemangiomas, enchondromatosis with multiple cavernous hemangiomas, or Kast syndrome, is a rare skeletal disorder, characterized by multiple enchondromas and benign vascular overgrowths. Although the natural history, severity, prognosis, and prevalence of malignancies have been the subject of multiple articles, the association with cardiovascular pathology is rather unusual. The purpose of this report is to describe the case of a patient with Maffucci syndrome and associated cardiac pathology and review the current literature.

CASE REPORT

We describe the case of a 22-year-old male, previously diagnosed with Maffucci syndrome, presenting to our clinic with complaints of recurrent syncope, fatigue, and palpitations. Family history includes the father's sudden death at the age of 38 years and the uncle's sudden death at the age of 26 years (Figure 1). The clinical examination revealed growth failure, with a standing height of only 124 cm and weight of 30 kg; severe lower and upper limb length discrepancy with consequent walking difficulties; abnormal skull development; multiple bone and soft tissue deformities; nodules all over the body, soft bright-red to deep-purple nodules and plaques on the right ear lobe, right scapulohumeral joint and right medius; amputation of the 2 terminal phalanges of the right medius due to infected hemangioma; and scar due to surgical repair of the right tibia fracture (Figure 2).

Electrocardiogram (ECG) and 24-hour Holter monitoring revealed sinus rhythm with intermittent 3° atrioventricular (AV) block, with the longest ventricular pause of 11.2 seconds, ventricular extrasystoles (5%), and 1 episode of non-sustained ventricular tachycardia (5 beats at 166 bpm) (Figure 3). Echocardiography showed left ventricular hypertrophy (thickest at 32 mm at the basal portion of the posterolateral and inferior wall); normal left ventricular ejection fraction; diastolic dysfunction and impaired longitudinal function; right ventricular hypertrophy (thickest at 11 mm at a free wall); small pericardial effusion (what was the largest size in mm), hypoplasia of the posterior mitral valve leaflet with secondary mitral regurgitation (Figure 4). X-rays demonstrated multiple enchondromas that are seen as oval-shaped voluminous osteolytic lesions in the metaphysis and the diaphysis of long bones, short tubular and flat bones, with severe generalized irregularities, disruption of the cortex, and extension into the surrounding soft tissues, with calcifications of soft tissue (Figure 5). Enchondromas in the majority of bones lead to the destruction of the normal architecture with irregular mineralization and deformity of the whole skeleton, and consecutive shortening and bowing of bone and short stature. A computed tomography examination confirmed the enchondromas and calcifications scattered through the entire body (Figure 6A).

Serum and urine electrophoresis, immunofixation, and serum-free light chain testing excluded light chain (AL) amyloidosis. Transthyretin amyloidosis (ATTR) was excluded by 99 mTc scintigraphy. Scintigraphy indicates no uptake at the heart level, but exceptionally unusual uptake in bones and soft tissue (Figure 6B, C).

CASE REPORT

Andreea M. Ursaru ¹

Mihail G. Chelu ²

Antoniou O. Petriş ^{1,3}

Cati R. Stolniceanu ⁴

Nicolae D. Tesloianu ¹

¹Department of Cardiology, Clinical Emergency Hospital "Sf. Spiridon", Iaşi, Romania

²Division of Cardiology, Baylor College of Medicine, Houston, Texas, United States

³"Grigore T. Popa" University of Medicine and Pharmacy, Iaşi, Romania

⁴Department of Nuclear Medicine, Clinical Emergency Hospital "Sf. Spiridon", Iaşi, Romania

Corresponding author:

Mihail G. Chelu

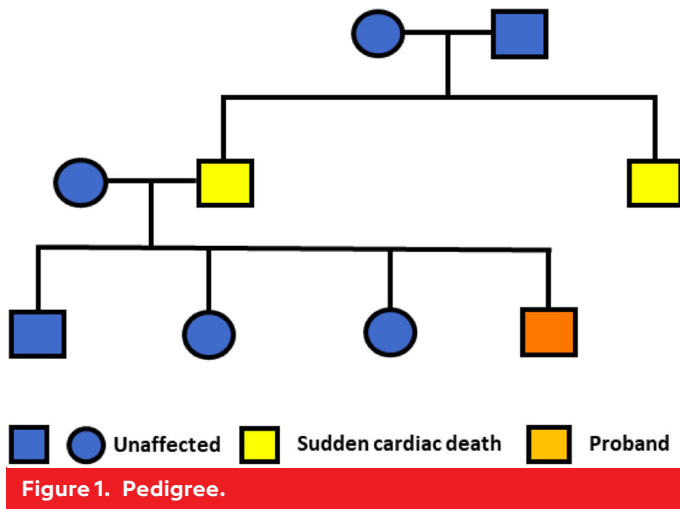
✉ Mihail.Chelu@bcm.edu

Cite this article as: Ursaru AM, Chelu MG, Petriş AO, Stolniceanu CR, Tesloianu ND. A unique association: maffucci syndrome and cardiac pathology. *Anatol J Cardiol* 2022;26(4):331-335.



Copyright@Author(s) - Available online at anatoljcardiol.com.
Content of this journal is licensed under a Creative Commons Attribution-NonCommercial 4.0 International License.

DOI:10.5152/AnatolJCardiol.2021.960



Genetic testing using a multigenic panel did not identify any mutation in the tested genes (Table 1). Normal levels of alfa-galactosidase and alfa-1,4-galactosidase excluded Fabry and Pompe disease, respectively, leading to a diagnosis of idiopathic hypertrophic cardiomyopathy. The risk of sudden cardiac death was calculated to > 6% at 5 years using the HCM Risk-SCD calculator. Therefore, an implantable cardioverter defibrillator (ICD) was implanted, for a class IIa indication. The patient had a favorable short-term evolution on beta-blocker with no symptoms at a 6-week follow-up.

This paper was written in accordance with the Declaration of Helsinki of 1975. The patient gave verbal and written informed consent and fully authorized the authors to use his medical data for research purposes.

DISCUSSION

Characteristics of Maffucci Syndrome

Maffucci syndrome is a non-hereditary, sporadic mesodermal dysplasia first described in 1881,¹ characterized by multiple enchondromas associated with multiple soft tissue hemangiomas or less commonly lymphangiomas, with less than 200 cases reported worldwide.^{2,3}

In 25% of cases, the clinical symptoms of Maffucci's syndrome are present at birth or manifest in the first year of life, and in around 80% the symptoms start before puberty.⁴

The enchondromas are usually asymmetrical and bilateral. Long bones of the arms and legs, metacarpal bones, and phalanges are most frequently affected, ranging from progressive skeletal deformity with shortened and/or unequal length limbs to pathologic fractures, bony distortion, scoliosis, and short stature.⁵ Although not as often, other bones may be affected.⁶ Maffucci syndrome is associated with an increased risk of malignancy due to the transformation of enchondromas to chondrosarcomas. The overall incidence of chondrosarcoma is approximately 30%-40%, with even higher rates of malignancy in patients with enchondromas located in long bones and axial skeleton, especially the pelvis. The mean average age of malignancy diagnosis is 40 years.^{2,7} Data regarding the potential of

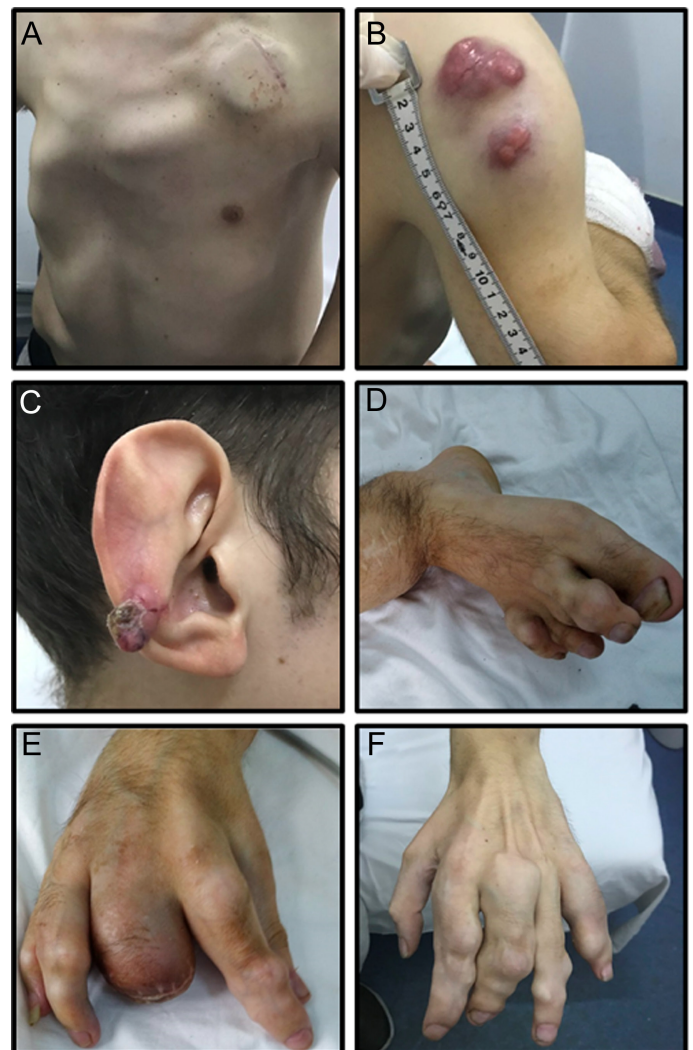

Figure 2. (A) Thorax with deformities; (B) Shortened upper limb, with hemangioma at the level of the right scapulothoracic joint; (C) Hemangioma at the level of the right ear. (D) Shortened right leg with deformity, nodules of the phalanges, and scar after tibial surgery. (E) and (F) Severe bone distortion of the forearm and hand with multiple nodules and hemangioma of the right medius.

malignancy differs between various studies. In a study by Schwartz of 44 patients with either Ollier's or Maffucci's syndrome approximately 25% of Ollier's syndrome while more than 50% of the Maffucci's syndrome patients developed malignancy.⁸ Lewis and Ketcham⁹ reported malignant transformation of enchondromas in 15.2% of 105 cases, Sun et al¹⁰ reported a prevalence of 56% in 9 patients, and Kaplan et al¹¹ found a 30% prevalence of chondrosarcoma in 65 patients. There appears to be no relationship between the number of involved bones and the risk of development of a skeletal malignancy in Maffucci syndrome.⁸

Hemangiomas vary in size from a few millimeters to several centimeters and are commonly seen on the skin as dark blue patches or nodules arising from the subcutaneous tissues, compressible and sometimes tender on pressure; these are

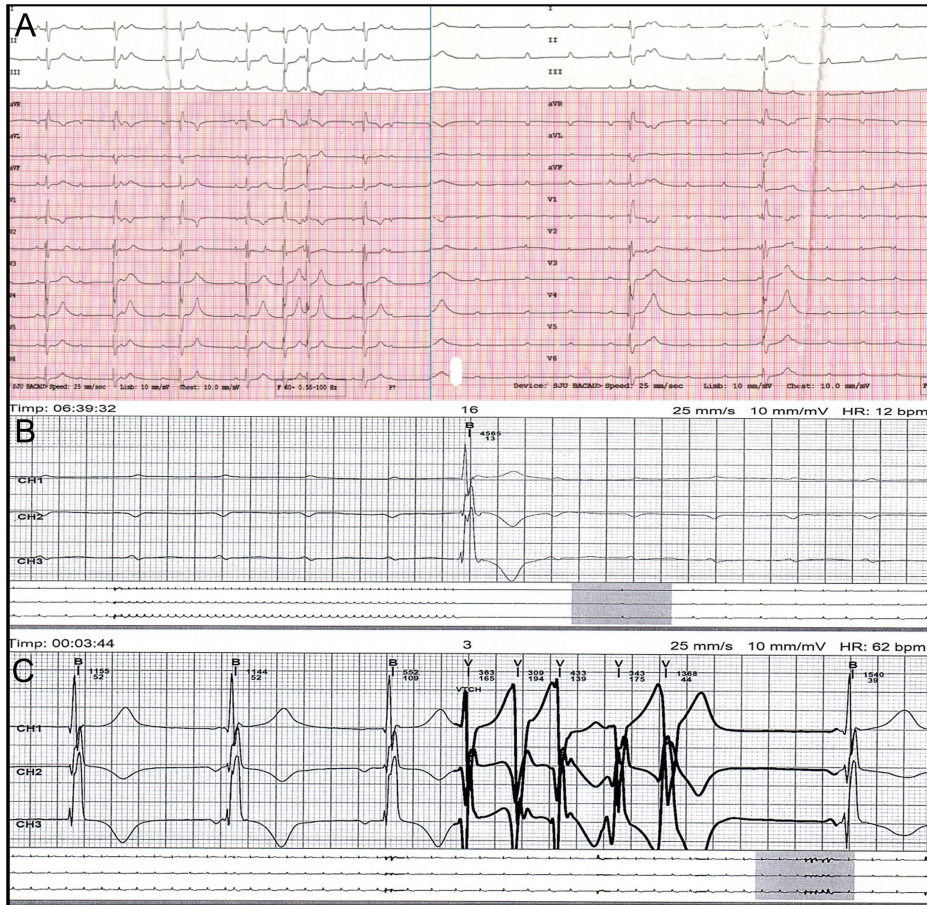


Figure 3. (A) Twelve lead rhythm echocardiography—sinus rhythm, complete atrioventricular block, escape rhythm with right bundle branch block, and left posterior fascicle block. (B) Twenty-four-hour Holter strip—paroxysmal atrioventricular block, with a significant ventricular pause (11.2 seconds) (C).

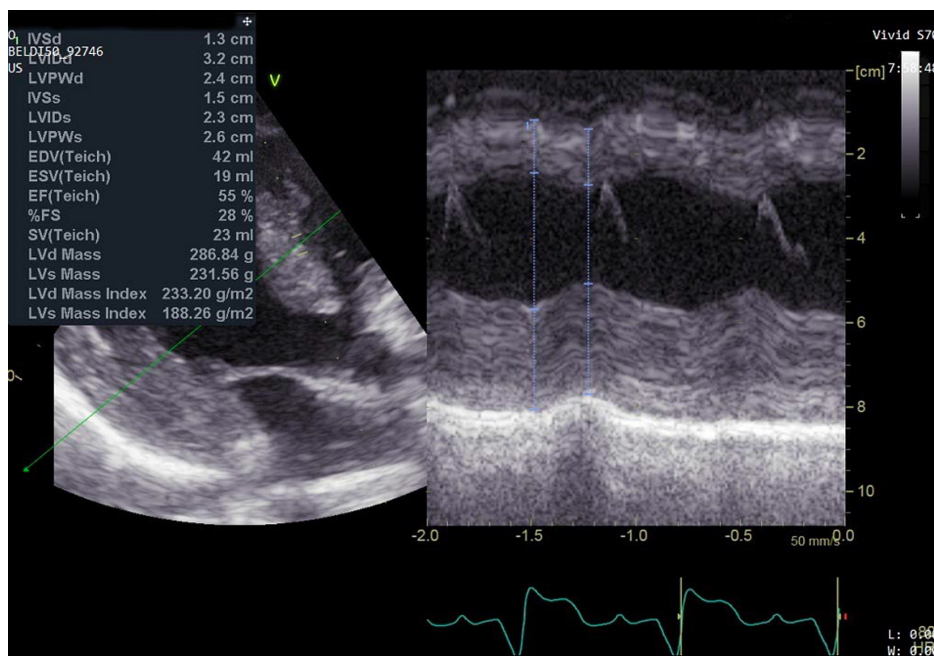


Figure 4. Echocardiography—parasternal long axis, anatomical M-Mode, normal ejection fraction, posterolateral wall thickness of 32 mm.

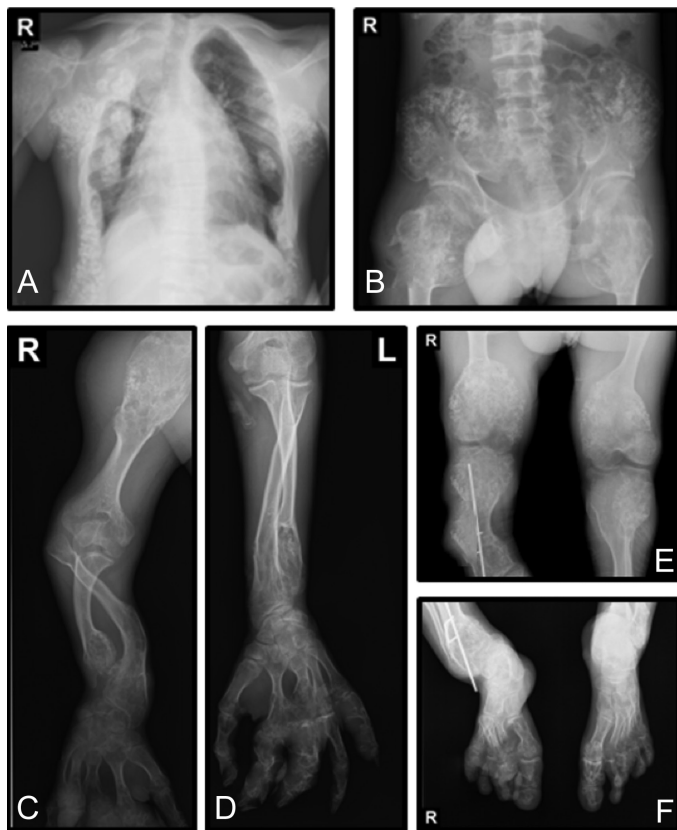

Figure 5. Postero-anterior radiograph of (A) the chest; (B) abdomen; (C) and (D) arms; and (E) and (F) legs showing expansile multiple enchondromas, with severe distortion of bone architecture, soft tissue calcifications, typical of angiomas with calcified phleboliths.

typically not only located in the dermis or subcutaneously on the distal parts of the limbs but may also be found in internal organs and may occasionally have phleboliths, producing a striking radiographic appearance in the soft tissues. Phlebectasia may be confined to a local area in a vein or may affect large groups of veins.¹² While the common vascular lesions to occur in association with Maffucci syndrome are spindle cell hemangiomas, angiosarcomas have also been reported.¹³ Pancreatic and hepatic adenocarcinoma,

Table 1. Multigenic Panel of Tested Genes, with No Identification of a Mutation

MYH7 (myosin, heavy chain 7)
MYBPC3 (myosin-binding protein C)
TNNT2 (troponin T2, cardiac type)
TNNI3 (troponin I3, cardiac type)
TPM1 (alfa-tropomyosin)
ACTC (cardiac actin)
MYL2 (regulatory myosin light chain)
MYL3 (essential myosin light chain)
TNNC1 (C cardiac troponin C),
ACTN2 (actinin alpha 2)
MYOZ2 (myozenin 2)
MYH6 (alpha-myosin heavy chain 6)
TTN (titin)

ovarian tumors, brain gliomas, astrocytomas are other types of malignancy encountered.² Frequently, Maffucci syndrome is associated with malignancy (especially sarcomas) thus, early detection of malignancies is being considered part of the treatment. Verdegaal et al⁷ proposed technetium scans in patients with more than 1 enchondroma to screen for and diagnose chondrosarcomas. At the moment, there is no medical treatment for Maffucci's syndrome. Surgical interventions are indicated to minimize deformities, pathological fractures, and malignant transformation.

Associated Pathologies

Association with cardiac pathology is unusual. Maffucci's syndrome has only been reported to be associated with arterial hypertension due to adrenal masses with autonomous cortisol secretion (adrenocorticotrophic hormone-independent Cushing syndrome).¹⁴ Two other cases of Maffucci's syndrome have been reported to be associated with an adrenal cortex tumor.^{15,16}

The present case is unique in its association with Maffucci's syndrome: hypertrophic cardiomyopathy, conduction disturbances, and ventricular malignant tachycardia in a young adult. Another unique feature is the ubiquitous distribution of enchondromas, affecting basically the entire skeleton.

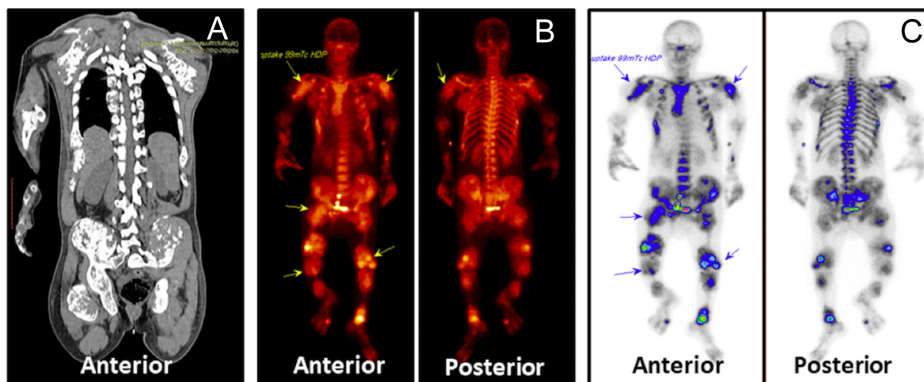


Figure 6. (A) Coronal full-body CT reconstruction showing generalized enchondromatosis; (B) and (C) Technetium-99m Scintigraphy showing marked uptake of tracer in bones and soft tissue (arrows). CT, computed tomography.

The enchondromas were also present in the muscles, by disruption of the cortex while typically cartilaginous tumors develop only near the growth plate cartilage.

Our studies could not firmly establish whether there is a direct link between Maffucci's syndrome and the cardiac phenotype or whether the cardiac disease is inherited as a separate condition, given the history of SCD in the family. Although the risk of death is increased in patients with Maffucci's syndrome due to the high malignancy rate, in our patients the risk of death is increased primarily by the cardiac pathologies. It remains to be determined whether this is only an accidental association, or whether there is a link between cardiac disease and Maffucci's syndrome. Given the low number of cases reported worldwide, it is difficult to establish the probability of an association, but this could be the first described association in a series of cases.

Informed Consent: Written informed consent was obtained from all participants who participated in this study.

REFERENCES

1. A. M. Di un caso encondroma ed angioma multiplo. Movimento medico-chirurgico, Napoli. 1881;3:399-412.
2. Ngai C, Ding DY, Rapp TB. Maffucci syndrome. An interesting case and a review of the literature. *Bull Hosp Jt Dis* (2013). 2015;73(4):282-285.
3. Prokopchuk O, Andres S, Becker K, Holzapfel K, Hartmann D, Friess H. Maffucci syndrome and neoplasms: a case report and review of the literature. *BMC Res Notes*. 2016;9:126. [\[CrossRef\]](#)
4. Mellon CD, Carter JE, Owen DB. Ollier's disease and Maffucci's syndrome: distinct entities or a continuum. Case report: enchondromatosis complicated by an intracranial glioma. *J Neurol*. 1988;235(6):376-378. [\[CrossRef\]](#)
5. Kaplan FS, Tabas JA, Gannon FH, Finkel G, Hahn GV, Zasloff MA. The histopathology of fibrodysplasia ossificans progressiva. An endochondral process. *J Bone Joint Surg Am*. 1993;75(2):220-230. [\[CrossRef\]](#)
6. Jermann M, Eid K, Pfammatter T, Stahel R. Maffucci's syndrome. *Circulation*. 2001;104(14):1693. [\[CrossRef\]](#)
7. Verdegaal SH, Bovée JV, Pansuriya TC, et al. Incidence, predictive factors, and prognosis of chondrosarcoma in patients with Ollier disease and Maffucci syndrome: an international multi-center study of 161 patients. *Oncologist*. 2011;16(12):1771-1779. [\[CrossRef\]](#)
8. Schwartz HS, Zimmerman NB, Simon MA, Wroble RR, Millar EA, Bonfiglio M. The malignant potential of enchondromatosis. *J Bone Joint Surg Am*. 1987;69(2):269-274. [\[CrossRef\]](#)
9. Lewis RJ, Ketcham AS. Maffucci's syndrome: functional and neoplastic significance. Case report and review of the literature. *J Bone Joint Surg Am*. 1973;55(7):1465-1479. [\[CrossRef\]](#)
10. Sun TC, Swee RG, Shives TC, Unni KK. Chondrosarcoma in Maffucci's syndrome. *J Bone Joint Surg Am*. 1985;67(8):1214-1219. [\[CrossRef\]](#)
11. Kaplan RP, Wang JT, Amron DM, Kaplan L. Maffucci's syndrome: two case reports with a literature review. *J Am Acad Dermatol*. 1993;29(5 Pt 2):894-899. [\[CrossRef\]](#)
12. McDermott AL, Dutt SN, Chavda SV, Morgan DW. Maffucci's syndrome: clinical and radiological features of a rare condition. *J Laryngol Otol*. 2001;115(10):845-847. [\[CrossRef\]](#)
13. Fukunaga M, Suzuki K, Saegusa N, Folpe AL. Composite heman-gioendothelioma: report of 5 cases including one with associated Maffucci syndrome. *Am J Surg Pathol*. 2007;31(10):1567-1572. [\[CrossRef\]](#)
14. Tricò D, Battaglia E, Bernini G. Maffucci syndrome associated With adrenocorticotrophic hormone-independent bilateral macronodular adrenal hyperplasia. *J Endocr Soc*. 2017;1(1):51-56. [\[CrossRef\]](#)
15. James KC, McIntyre HD. Maffucci's syndrome in association with adrenal Cushing's syndrome. *Aust NZ J Med*. 1995;25(5):544. [\[CrossRef\]](#)
16. Puech-Bret N, Bret J, Bennet A, et al. Maffucci syndrome and adrenal cortex tumor. *Joint Bone Spine*. 2009;76(5):556-558. [\[CrossRef\]](#)