

Pacing in obstructive hypertrophic cardiomyopathy: a therapeutic option?

Hipertrofik kardiyomiyopatide pacing: Terapötik opsiyon mu?

*Atul Kukar, Mark V. Sherrid, Frederick A. Ehlert**

From the Division of Cardiology, St. Luke's-Roosevelt Hospital Center, Columbia University College of Physicians and Surgeons, New York,

*Current affiliation-New York Presbyterian Hospital, New York, NY, USA

ABSTRACT

Hypertrophic cardiomyopathy (HCM) is a heterogeneous disease of cardiac muscle which can present with myriad functional and clinical manifestations. When symptoms and left ventricular outflow gradients are present, it is primarily treated with pharmacologic agents. For refractory patients, dual chamber pacing has been proposed; by altering timing and site of cardiac electrical activation, obstruction may be improved. Results of non-randomized and randomized trials have shown an average gradient reduction of 50%. However, pressure gradient reduction within the left ventricular outflow tract (LVOT) has not translated into improved objective functional measurements, even though subjective parameters may improve. Dual chamber pacing cannot be recommended as primary treatment for obstruction except in a subset of patients who are elderly or have significant comorbidities that preclude surgery. However, many patients will now receive implantable cardioverter-defibrillators (ICD) which will include both right atrial and right ventricular leads. This will allow DDD pacing which may be utilized for symptom palliation. Future investigations will determine if alternate forms of pacing, including left atrial or left ventricular pacing, may improve objective measures in these patients. (*Anadolu Kardiyol Derg 2006; 6 Suppl 2: 49-54*)

Key words: Hypertrophic cardiomyopathy, dual chamber pacemaker, left ventricular outflow tract obstruction

ÖZET

Hipertrofik kardiyomiyopati (HKM) sayısız fonksiyonel ve klinik belirtiler ile ortaya çıkan kardiyak adale hastalığıdır. Bu hastalık semptomlar ve sol ventrikül çıkış yolu (SVÇY) gradiyentinin varlığında primer olarak farmakolojik ajanlar ile tedavi edilir. Refrakter hastalar için çift-odacıklı pacing önerilmektedir, böylece HKM'ye eşlik eden hemodinamik anormallikler, kardiyak elektriksel aktivasyonunun yeri ve zamanlamasının değişmesi sonucu modifiye edilebilirler. Randomize ve randomize olmayan çalışmalar bu tedavi ile gradiyentin %50'ye kadar azaldığını bildirmişler. Yine de, SVÇY basınç gradiyentinin düşüşü subjektif parametrelerde iyileşmeye neden olsa bile objektif fonksiyonel ölçülerde iyileşmeyi getirmemektedir. Yaşlı ve cerrahi tedaviye engel olabilecek önemli komorbiditeleri olan hastalara obstrüksiyonun primer tedavisi olarak çift-odacıklı pacing tavsiye edilmektedir. Bununla birlikte, günümüzde birçok hastaya hem sağ atriyal, hem sağ ventrikül tellerini içeren kardiyoverter defibrilatör (ICD) takılmaktadır. Bu, semptomların hafifletmesi amacı ile DDD pacing'in kullanılmasını mümkün kılabilir. Bu hastalarda alternatif pacing formları, sol atriyum ve sol ventrikül pacing dahil, objektif ölçülerde ne kadar iyileşme sağlar; bunu gelecekte yapılacak çalışmalar saptayabilirler. (*Anadolu Kardiyol Derg 2006; 6 Özel Sayı 2: 49-54*)

Anahtar kelimeler: Hipertrofik kardiyomiyopati, çift-odacıklı pacemaker, sol ventrikül çıkış yolu obstrüksiyonu

Introduction

Hypertrophic cardiomyopathy (HCM) is a complex and heterogeneous disease of cardiac muscle with a variety of functional, morphologic and clinical manifestations. The principal phenotypic identifier of HCM is abnormal thickening of cardiac muscle that occurs without clinical cause. When this occurs in the interventricular septum and/or anterior wall, left ventricular outflow tract (LVOT) obstruction may result through the mechanism of systolic anterior

motion (SAM) of the mitral valve. Left ventricular outflow tract obstruction may impair myocardial function, cause arrhythmias and diastolic dysfunction; it exacerbates symptoms (1). Pharmacologic agents are the primary therapy for the relief of LVOT obstruction. Beta-adrenergic blockers, calcium channel blockers and disopyramide decrease LVOT gradients and improve symptoms (2,3).

But, a subgroup of patients are refractory to pharmacologic therapy or may not tolerate it. For these patients, few treatment options exist. Surgical septal myectomy has been employed with

Address for Correspondence: Mark V. Sherrid, MD, Professor, Clinical Medicine,
1000 10th Avenue, New York City, NY 10019 USA
E-mail: msherrid@chpnet.org

Presented in part at "Hypertrophic Cardiomyopathy Treatment: Medical, Surgical, Sudden Death Prevention and Newer Modalities" sponsored by St. Luke's/Roosevelt Hospital Center, Columbia University, College of Physicians and Surgeons, New York City, December, 2005

considerable success for over 30 years and is the gold standard to relieve symptoms and obstruction. However, the procedure requires sternotomy and cardio-pulmonary bypass and is associated with morbidity and mortality (4). Percutaneous alcohol septal ablation has also been utilized, although its ultimate utility and safety remain controversial (5). Finally, for a select subset of patients with refractory LVOT obstruction, DDD pacing with a short atrioventricular (AV) delay may be of benefit. This manuscript is a review of the underlying mechanisms and the clinical experience with this therapy.

Mechanism of Left Ventricular Outflow Tract Obstruction

The mechanism of outflow tract obstruction due to SAM of the mitral valve and mitral-septal contact is becoming more apparent. Historically, it was thought that SAM was induced by Venturi forces. In the Venturi theory, the hypertrophied septum is the essential component leading to a narrowed left ventricular outflow tract (LVOT). During contraction, the thickened septum was thought to bulge further into the LVOT. It was thought that high velocity early flow caused a local underpressure in the outflow tract, thereby lifting or elevating the mitral leaflet into the septum. But various observations have raised questions about the validity of this theory (6).

The flow drag theory of SAM offers a more complete explanation of obstruction in HCM and is strongly supported by echocardiographic findings. There is evidence that flow drag, the pushing force of flow, acting on the mitral valve is the dominant hemodynamic force that causes SAM. The mitral leaflets are often large and anteriorly positioned in the left ventricle (LV) (7). The combination of the midseptal bulge and the 'agglutination' of the papillary muscles onto the LV wall serve to malposition the mitral valve anteriorly in the LV (8-10). The midseptal bulge redirects flow so that it comes from a lateral and posterior position and then gets behind and lateral to the anatomically altered mitral valve and pushes it into the septum. This loop is amplified as more of the mitral valve gets exposed to the drag forces,

which then exert even greater force onto the valve. The SAM may be understood as a flow drag triggered, time-dependent, amplifying feedback loop (6, 10, 11) (Fig. 1).

Mechanism of Pacing Benefit: Unknown

Despite 40 years of experience, the mechanisms whereby DDD pacing with short AV delay reduces SAM and subsequent LVOT obstruction are not yet understood. Theories to explain the beneficial effects of pacing are: 1) alteration of the myocardial activation sequence inducing dyssynchronous ventricular activation and paradoxical septal movement, 2) negative inotropic effects, and 3) alteration of mitral valve leaflet excursion.

1. Preexcitation of the right ventricle (RV) alters the dynamics and timing of ventricular contraction, ensuring LV apical activation prior to septal activation (12-15). This has been thought to be helpful by decreasing the excursion of the septal wall into the LVOT. The paradoxical (delayed) activation of the inter-ventricular septum during dual chamber pacing is thought to limit outflow tract narrowing by decreasing the projection of the ventricular septum into the outflow tract and its dynamic obstruction (15). This has been demonstrated using tissue Doppler imaging under direct echocardiographic visualization of the septum with and without pacing (13). However, it is important to note that septal contraction is a late systolic event while SAM and mitral septal contact in severe obstruction occurs early in systole; thus, paradoxical septal motion cannot be the means by which pacing works (10, 13, 16).

2. The negative inotropic effect and dyssynchrony induced by DDD pacing may play a role by decreasing the ejection acceleration and decreasing early forces on the mitral valve (3).

3. The mitral apparatus plays an important role in the dynamic obstruction; its motion may be modified by pacing and reversing the normal base to apex activation. Pacing activation of the right ventricular apex could produce early activation of the papillary muscles and chordae which could limit mitral valve leaflet excursion. Premature apical tensing of the mitral apparatus - thus early tensing of the chordal apparatus of the mitral valve - may possibly reduce SAM by mitigating excess slack.

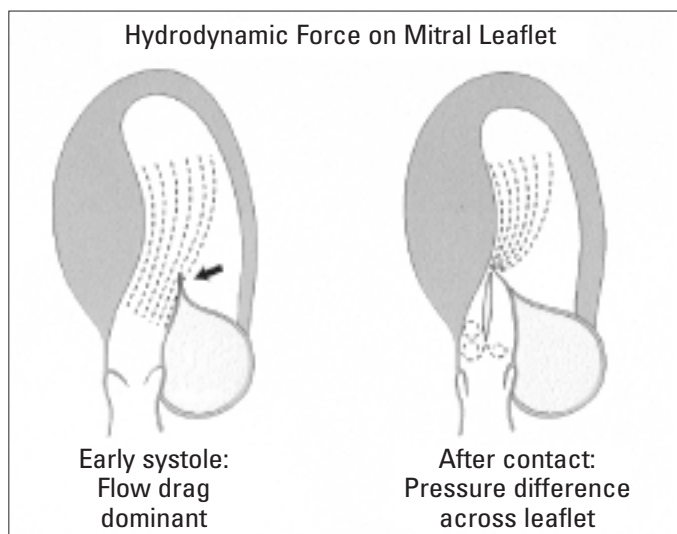


Figure 1. Mechanisms of obstruction in hypertrophic cardiomyopathy

(Modified from reference 10)

Debate Over Efficacy

Initial observations of pacing in obstructive HCM were made by Hassenstein et al. in 1967. When ventricular (VVI) pacing was instituted in a patient with complete heart block, a gradient reduction of 56% was noted (AV delay was 0 ms) (17). In 1984, Duck et al. used both asynchronous ventricular stimulation, triggered by a native atrial complex, and synchronous dual chamber pacing. They showed outflow tract gradient reduction in almost all patients. The optimal AV delay was determined to be between 5 and 20 ms (18). In 1992, two retrospective studies by Fananapazir et al. and Jeanrenaud et al. revealed that AV synchronous pacing with a short AV delay resulted in decreased gradient, symptoms and occasionally increased exercise capacity (19-21) (Fig 2).

Numerous studies of dual chamber pacing have yielded conflicting results. As of now, there is no evidence that pacing reduces the risk of sudden death or substantially alters the clinical

cal course of the disease (22). The main variables studied have been the effect of pacing on gradient, symptom benefit, and quality of life.

The mean level of gradient reduction in pacing studies varies from 25-50%. Results are inconsistent and vary from patient to patient. Some patients have marginal benefit while others obtain complete gradient abolition (23-25). Three randomized, crossover studies (2 of which were double-blinded) were undertaken in HCM patients refractory to medical therapy.

Nishimura et al. reported a randomized, double-blinded, crossover study of 19 subjects and showed a quality of life improvement in 63% of patients in the DDD mode. However, 42% of patients in the control arm (atrial, AAI pacing) also showed improvement. Although the LVOT gradient improved with DDD pacing, there was no difference in any of the measured functional parameters (25). The benefits seen in this study were regarded as largely due to a placebo effect (26).

The Pacing in Cardiomyopathy (PIC) study was published in the same year. In this multicenter European study, Kappenberger et al. showed a significant improvement in the symptoms of angina and dyspnea as well as in LVOT gradients. This trial excluded patients who did not show an initial response to temporary pacing. Slade et al. demonstrated that patients with a response to temporary pacing were more likely to respond (gradient reduction > 30%) to permanent pacing (23). They concluded that early benefit from pacing may determine utility of pacing for symptoms.

In 1999, Maron et al. published a randomized, double-blind, crossover trial named the M-PATHY trial. In this multicenter North American trial of 48 patients with drug refractory obstructive HCM, an average reduction in LVOT gradient of 40 mm Hg was seen, but without effect on quality of life. Also, no change in exercise capacity, peak oxygen consumption or septal wall thickness was noted. A subgroup of patients over the age of 65 showed consistent improvement in functional capacity although they only constituted 12% of the studied population. The authors'

final conclusions were that pacing cannot be regarded as primary therapy for obstruction because of inconsistent results. Also, a large placebo effect is present (24).

However, interest persists, particularly in the elderly. Lever et al showed that elderly HCM patients have an LV cavity with an ovoid shape in comparison to a crescent LV shape in younger HCM patients (27). Dimitrow et al showed that such morphologic alterations in shape may influence response to pacing (28). This difference in LV shape may explain why both the M-PATHY and PIC trials have shown that elderly patients (> 65 years) are most likely to respond.

In reference to mitral regurgitation (MR), which is closely tied to LVOT obstruction and symptoms in HCM, a study of 23 patients revealed that dual chamber pacing significantly reduces LVOT gradient and the regurgitant volume in the absence of organic mitral valve abnormalities (other than leaflet elongation) (29). Septal wall thickness is an essential feature of inducing LVOT obstruction and has generally been shown to not to be altered by chronic pacing therapy (23-25, 30).

These randomized trials only looked at the benefits of pacing in the short term. The largest non-randomized study of 84 patients followed patients for 2.3 ± 0.8 years. This study demonstrated continued reductions in LVOT gradients and symptoms of heart failure. Also, Lellouche et al. showed persistence of gradient reductions and symptoms at follow up of 35.1 ± 20.3 months (31). Reduction in LVOT gradient and a reduction in symptoms can be maintained up to 10 years after initial implant (32).

A comparison of dual chamber pacing and septal myectomy for patients with drug refractory symptoms was undertaken at the Mayo Clinic. This non-randomized concurrent cohort study analyzed LVOT gradients, symptoms, and metabolic treadmill exercise testing in 39 patients who underwent surgery or pacemaker implantation based on physician preference. Although both groups showed improvement in subjective measurements, myectomy patients had a greater reduction in LVOT gradients and larger improvements in functional status (33).

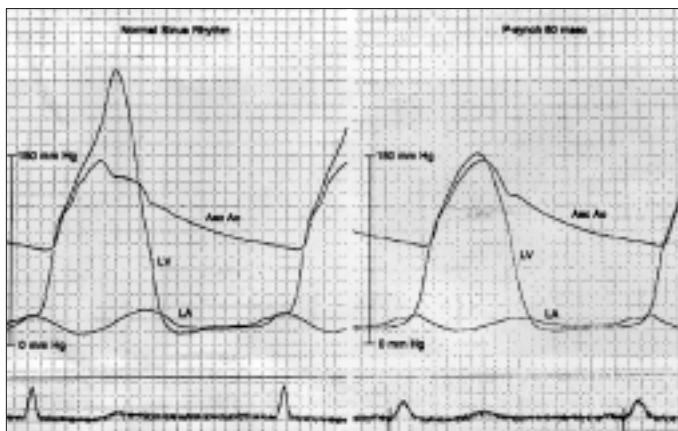


Figure 2. Changes in outflow gradient across LVOT with pacing. Catheterization measurements of pressures in the left ventricle and aorta during sinus rhythm (left) and pacing (right) showing an acute reduction in the outflow tract gradient. Note wider QRS in right pane

LVOT- left ventricular outflow tract

(Reprinted from the Journal of the American College of Cardiology, Vol 27, number 2, Nishimura RA, Hayes DL, Ilstrup DM, Holmes DR, Jr., Tajik AJ. Effect of dual-chamber pacing on systolic and diastolic function in patients with hypertrophic cardiomyopathy, Pages No. 421-30, Copyright (1996), with permission from the American College of Cardiology Foundation).

Practical Aspects of AV Pacing in Obstructive HCM

Pacing works by pre-exciting the apical and septal regions of the left ventricle. This is determined by the native AV conduction time and the sensed AV delay. Shorter delays allow for more complete apical preexcitation, by not allowing activation through the His-Purkinje system. However, delays that are too short are detrimental to diastolic filling, elevate mean left atrial pressure and can worsen symptoms. In their original articles, Fananapazir et al. and Jeanrenaud et al. determined that an AV delay of shorter than 100 ms is necessary to ensure full apical preexcitation (20). This was further validated in other studies showing optimal gradient reduction at AV delays ranging from 80-100 ms (34). Other studies demonstrate the relationship between AV delay and gradient (Fig. 3).

This issue is complicated by the need to maintain this delay at higher heart rates, i.e during exercise. A pacemaker that will dynamically shorten its AV delay as heart rate increases is useful. Also useful would be a set AV delay which is short enough to maintain ventricular pre-excitation during exercise. However, this is

not always possible, and rapid AV conduction can cause failure to pre-excite the apex. In these patients, ablation of the AV node has been advocated to alleviate this problem, but creates pacemaker dependence which is irreversible and must never be undertaken lightly in the young (35). One small study suggests using isoproterenol to mimic different physiologic conditions to calculate the optimal AV delay (36). The presence of atrial fibrillation with rapid ventricular response can also hamper the benefit of pacemaker implantation.

In reference to specific alterations of pacemaker functioning in patients with HCM, one must remember that because of the significant LV mass, there is a tendency to have increased far-field R wave sensing which may lead to pacemaker mediated tachycardia. Longer refractory periods in the atrial channels, reducing atrial sensitivity and using bipolar atrial electrodes minimize this risk (20).

There are several specific avenues towards optimizing pacing in obstructive HCM pertinent to these trials. For example, the site of right atrial (RA) and RV pacing, optimal AV delay and means by which to obtain it, minimizing side effects of pacing in patients with HCM, and effect of long term pacing. Gadler et al. demonstrated that temporary pacing from the apex reduced the LVOT gradient in all patients and septal pacing resulted in little or no change. This clearly demonstrates that positioning the RV pacing lead at the apex is essential to success of therapy (37).

Another area of controversy regarding pacing in HCM arises from 2 studies which have demonstrated a detrimental effect on diastolic dysfunction and filling pressures. Betocchi et al. and Nishimura et al. have both shown that although AV pacing can reduce the LVOT gradients, there may be worsening of the already impaired diastolic function caused by premature truncation of atrial filling, physiologically shorter AV delays that impair atrial emptying and RV filling, and LV asynchrony may impair diastolic function (12, 14).

Refinements & Future Directions

With shortened AV delays, some patients with delayed interatrial conduction time may suffer from a phenomenon in which the left atrial contraction occurs after mitral valve closure. Left

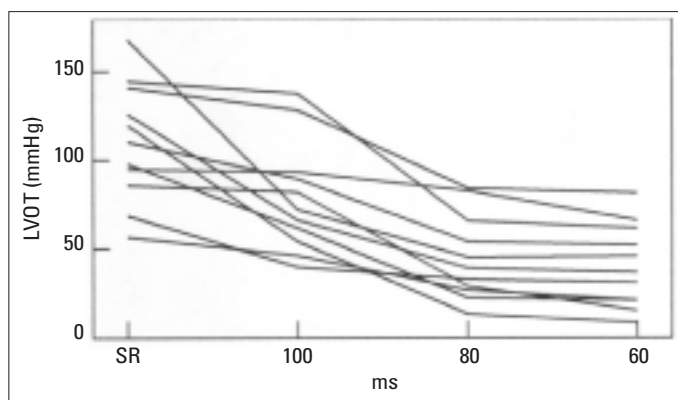


Figure 3. AV delay and LVOT obstruction. Left ventricular outflow tract obstruction during sinus rhythm and pacing with different atrioventricular delays

AV- atrioventricular, LVOT- left ventricular outflow tract
(Reprinted with permission of Oxford University Press from Gadler F. Pacing in obstructive hypertrophic cardiomyopathy. Eur Heart J Supplements 2001; 3 Suppl L: L32-7).

atrial pacing (via the coronary sinus) allows short AV delays, without hampering the left atrial kick which is essential to diastolic filling in HCM patients (38).

Future avenues of research include LV pacing via the coronary sinus or epicardial lead placement. A few cases have been published showing significant benefit. Options for this strategy include RA-LV or RA-RV-LV pacing as well as altering RA pacing locations to maximize LA activation to allow short AV delays (39-41).

Apical and Mid HCM

Apical HCM, is more commonly found in Japan and among Asian patients with HCM, though roughly 8% of North American HCM patients have this variant. Obstruction may occur when mid-hypertrophy occurs as well. Here, AV sequential pacing may be useful when symptoms are severe and refractory.

VDD pacing with a short PR interval (allowing for greater RV preexcitation) may result in a decrease in contractility and a shift of the pressure volume relationship in the LV to the right, thereby increasing end systolic volume, decreasing dP/dt, reducing apical cavity work compression and reducing cardiac work (15). This rightward shift of the end-systolic pressure volume would effectively increase LV end-systolic volumes, particularly regional (apical segment) volumes.

Conclusion

Despite the observation that some patients derive benefit, DDD pacing cannot be regarded as a primary treatment modality for LVOT obstruction. Three randomized controlled trials, with roughly 140 patients, have shown that pacing can reduce the LVOT gradient by about 50%, lead to a modest reduction in symptoms, but no improvement in exercise capacity (23-25, 42). Also, there is no clear relationship between degree of gradient reduction and the magnitude of symptom benefit. It has been shown that there is a significant placebo effect of implanted devices which may explain improvement in subjective parameters. In addition, in young patients, its use is of more concern, as it is highly unpredictable and because myectomy is more effective.

Nonetheless, there may be a benefit in selected subgroups, such as those greater than 65 years old (24). Also, pacing may have the advantage of allowing more aggressive drug therapy with beta blockers, verapamil or disopyramide, which otherwise can produce severe bradycardia. Pacing in obstructive HCM patients should be performed in specialized centers, because reduction in gradient requires AV interval optimization, best done with echocardiographic guidance.

It is for these reasons that the ACC/AHA/NASPE guidelines in 2002 gave pacing in patients with HCM whom are refractory to pharmacologic therapy a Class IIB indication (however, it is clearly indicated in patients with sinus node dysfunction or high grade AV block) (43).

Since implanted defibrillators are being used to prevent sudden death in HCM patients, the opportunity to pace obstructed, moderately symptomatic patients is now a possibility. Understanding how pacing improves obstruction is needed to optimize benefit and to determine which subgroup of patients benefit. Only then can this modality be used appropriately.

References

1. Wigle ED, Rakowski H, Kimball BP, Williams WG. Hypertrophic cardiomyopathy. Clinical spectrum and treatment. *Circulation* 1995;92:1680-92.
2. Sherrid MV, Barac I, McKenna WJ, Elliott PM, Dickie S, Chojnowska L, et al. Multicenter study of the efficacy and safety of disopyramide in obstructive hypertrophic cardiomyopathy. *J Am Coll Cardiol* 2005;45:1251-8.
3. Sherrid MV, Pearle G, Gunsburg DZ. Mechanism of benefit of negative inotropes in obstructive hypertrophic cardiomyopathy. *Circulation* 1998;97:41-7.
4. Heric B, Lytle BW, Miller DP, Rosenkranz ER, Lever HM, Cosgrove DM. Surgical management of hypertrophic obstructive cardiomyopathy. Early and late results. *J Thorac Cardiovasc Surg* 1995;110:195-206.
5. Fananapazir L, McAreavey D. Therapeutic options in patients with obstructive hypertrophic cardiomyopathy and severe drug-refractory symptoms. *J Am Coll Cardiol* 1998;31:259-64.
6. Sherrid MV, Chu CK, Delia E, Mogtader A, Dwyer EM, Jr. An echocardiographic study of the fluid mechanics of obstruction in hypertrophic cardiomyopathy. *J Am Coll Cardiol* 1993;22:816-25.
7. Maron BJ, Gardin JM, Flack JM, Gidding SS, Kurosaki TT, Bild DE. Prevalence of hypertrophic cardiomyopathy in a general population of young adults. Echocardiographic analysis of 4111 subjects in the CARDIA Study. Coronary Artery Risk Development in (Young) Adults. *Circulation* 1995;92:785-9.
8. Messmer BJ. Extended myectomy for hypertrophic obstructive cardiomyopathy. *Ann Thorac Surg* 1994;58:575-7.
9. Sherrid MV, Chaudhry FA, Swistel DG. Obstructive hypertrophic cardiomyopathy: echocardiography, pathophysiology, and the continuing evolution of surgery for obstruction. *Ann Thorac Surg* 2003;75:620-32.
10. Sherrid MV, Gunsburg DZ, Moldenhauer S, Pearle G. Systolic anterior motion begins at low left ventricular outflow tract velocity in obstructive hypertrophic cardiomyopathy. *J Am Coll Cardiol* 2000;36:1344-54.
11. Sherrid MV. Dynamic Left ventricular outflow obstruction in hypertrophic cardiomyopathy revisited: significance, pathogenesis, and treatment. *Cardiol Rev* 1998;6:135-45.
12. Betocchi S, Elliott PM, Briguori C, Virdee M, Losi MA, Matsumura Y, et al. Dual chamber pacing in hypertrophic cardiomyopathy: long-term effects on diastolic function. *Pacing Clin Electrophysiol* 2002;25:1433-40.
13. Ito T, Suwa M, Sakai Y, Hozumi T, Kitaura Y. Usefulness of tissue Doppler imaging for demonstrating altered septal contraction sequence during dual-chamber pacing in obstructive hypertrophic cardiomyopathy. *Am J Cardiol* 2005;96:1558-62.
14. Nishimura RA, Hayes DL, Ilstrup DM, Holmes DR, Jr., Tajik AJ. Effect of dual-chamber pacing on systolic and diastolic function in patients with hypertrophic cardiomyopathy. Acute Doppler echocardiographic and catheterization hemodynamic study. *J Am Coll Cardiol* 1996;27:421-30.
15. Pak PH, Maughan WL, Baughman KL, Kieval RS, Kass DA. Mechanism of acute mechanical benefit from VDD pacing in hypertrophied heart: similarity of responses in hypertrophic cardiomyopathy and hypertensive heart disease. *Circulation* 1998;98:242-8.
16. Betocchi S, Losi MA, Piscione F, Boccalatte M, Pace L, Golino P, et al. Effects of dual-chamber pacing in hypertrophic cardiomyopathy on left ventricular outflow tract obstruction and on diastolic function. *Am J Cardiol* 1996;77:498-502.
17. Hassenstein P, Wolter HH. [Therapeutic control of a threatening stage of idiopathic hypertrophic subaortic stenosis]. *Verh Dtsch Ges Kreislaufforsch* 1967;33:242-6.
18. O'Rourke RA. Cardiac pacing. An alternative treatment for selected patients with hypertrophic cardiomyopathy and adjunctive therapy for certain patients with dilated cardiomyopathy. *Circulation* 1999;100:786-8.
19. Fananapazir L, Cannon RO, 3rd, Tripodi D, Panza JA. Impact of dual-chamber permanent pacing in patients with obstructive hypertrophic cardiomyopathy with symptoms refractory to verapamil and beta-adrenergic blocker therapy. *Circulation* 1992;85:2149-61.
20. Gadler F. Pacing in obstructive hypertrophic cardiomyopathy. *Eur Heart J Suppl* 2001;3:L32-7.
21. Jeanrenaud X, Goy JJ, Kappenberger L. Effects of dual-chamber pacing in hypertrophic obstructive cardiomyopathy. *Lancet* 1992;339:1318-23.
22. Spirito P, Seidman CE, McKenna WJ, Maron BJ. The management of hypertrophic cardiomyopathy. *N Engl J Med* 1997;336:775-85.
23. Kappenberger L, Linde C, Daubert C, McKenna W, Meisel E, Sadoul N, et al. Pacing in hypertrophic obstructive cardiomyopathy. A randomized crossover study. PIC Study Group. *Eur Heart J* 1997;18:1249-56.
24. Maron BJ, Nishimura RA, McKenna WJ, Rakowski H, Josephson ME, Kieval RS, et al. Assessment of permanent dual-chamber pacing as a treatment for drug-refractory symptomatic patients with obstructive hypertrophic cardiomyopathy. A randomized, double-blind, crossover study (M-PATHY). *Circulation* 1999;99:2927-33.
25. Nishimura RA, Trusty JM, Hayes DL, Ilstrup DM, Larson DR, Hayes SN, et al. Dual-chamber pacing for hypertrophic cardiomyopathy: a randomized, double-blind, crossover trial. *J Am Coll Cardiol* 1997;29:435-41.
26. Maron BJ, McKenna WJ, Danielson GK, Kappenberger LJ, Kuhn HJ, Seidman CE, et al. American College of Cardiology/European Society of Cardiology Clinical Expert Consensus Document on Hypertrophic Cardiomyopathy. A report of the American College of Cardiology Foundation Task Force on Clinical Expert Consensus Documents and the European Society of Cardiology Committee for Practice Guidelines. *Eur Heart J* 2003;24:1965-91.
27. Lever HM, Karam RF, Currie PJ, Healy BP. Hypertrophic cardiomyopathy in the elderly. Distinctions from the young based on cardiac shape. *Circulation* 1989;79:580-9.
28. Dimitrow PP, Grodecki J, Bacior B, Dudek D, Legutko J, Jaszcz KK, et al. The importance of ventricular septal morphology in the effectiveness of dual chamber pacing in hypertrophic obstructive cardiomyopathy. *Pacing Clin Electrophysiol* 2000;23:1324-9.
29. Pavin D, de Place C, Le Breton H, Leclercq C, Gras D, Victor F, et al. Effects of permanent dual-chamber pacing on mitral regurgitation in hypertrophic obstructive cardiomyopathy. *Eur Heart J* 1999;20:203-10.
30. Fananapazir L, Epstein ND, Curiel RV, Panza JA, Tripodi D, McAreavey D. Long-term results of dual-chamber (DDD) pacing in obstructive hypertrophic cardiomyopathy. Evidence for progressive symptomatic and hemodynamic improvement and reduction of left ventricular hypertrophy. *Circulation* 1994;90:2731-42.
31. Lellouche D, Nourredine M, Duval AM, Pujadas P, Gartenlaub O, Castaigne A, et al. [Hypertrophic obstructive cardiomyopathy and double-chamber pacing. Long-term results in a consecutive series of 22 patients]. *Arch Mal Coeur Vaiss* 1999;92:1737-44.
32. Megevand A, Ingles J, Richmond DR, Semsarian C. Long-term follow-up of patients with obstructive hypertrophic cardiomyopathy treated with dual-chamber pacing. *Am J Cardiol* 2005;95:991-3.
33. Ommen SR, Nishimura RA, Squires RW, Schaff HV, Danielson GK, Tajik AJ. Comparison of dual-chamber pacing versus septal myectomy for the treatment of patients with hypertrophic obstructive cardiomyopathy: a comparison of objective hemodynamic and exercise end points. *J Am Coll Cardiol* 1999;34:191-6.
34. Losi MA, Betocchi S, Briguori C, Piscione F, Manganelli F, Ciampi O, et al. Dual chamber pacing in hypertrophic cardiomyopathy: influence of atrioventricular delay on left ventricular outflow tract obstruction. *Cardiology* 1998;89:8-13.

35. Jeanrenaud X, Schlapfer J, Fromer M, Aebischer N, Kappenberger L. Dual chamber pacing in hypertrophic obstructive cardiomyopathy: beneficial effect of atrioventricular junction ablation for optimal left ventricular capture and filling. *Pacing Clin Electrophysiol* 1997;20:293-300.
36. Merce J, Galve E, Cucurull E, Garcia del Castillo H, Moya A, Bosch R, et al. [Treatment of hypertrophic obstructive cardiomyopathy with dual chamber pacing. Use of isoproterenol in determining the optimal AV interval]. *Rev Esp Cardiol* 1994;47:562-4.
37. Gadler F, Linde C, Juhlin-Dannfeldt A, Ribeiro A, Ryden L. Influence of right ventricular pacing site on left ventricular outflow tract obstruction in patients with hypertrophic obstructive cardiomyopathy. *J Am Coll Cardiol* 1996;27:1219-24.
38. Daubert C GD, Pavin D. Batrial synchronous pacing to optimize hemodynamic benefit of DDD pacing in hypertrophic obstructive cardiomyopathy [abstract]. *Circulation* 1995;92 (Suppl 1):775-80.
39. Honda T, Shono H, Koyama J, Tsuchiya T, Hayashi M, Hirayama T, et al. Impact of right atrial-left ventricular dual-chamber permanent pacing in patients with severely symptomatic hypertrophic obstructive cardiomyopathy. *Circ J* 2005;69:536-42.
40. Komsuoglu B, Vural A, Agacdiken A, Ural D. Effect of biventricular pacing on left ventricular outflow tract pressure gradient in a patient with hypertrophic cardiomyopathy and normal interventricular conduction. *J Cardiovasc Electrophysiol* 2006;17:207-9.
41. Yufu K, Takahashi N, Ooie T, Shigematsu S, Hara M, Sako H, et al. Improved hypertrophic obstructive cardiomyopathy by left ventricular apex epicardial pacing. *Intern Med* 2004;43:295-9.
42. Gilligan DM. Dual-chamber pacing in hypertrophic cardiomyopathy. *Curr Cardiol Rep* 2000;2:154-9.
43. Gregoratos G, Abrams J, Epstein AE, Freedman RA, Hayes DL, Hlatky MA, et al. ACC/AHA/NASPE 2002 Guideline Update for Implantation of Cardiac Pacemakers and Antiarrhythmia Devices--summary article: a report of the American College of Cardiology/American Heart Association Task Force on Practice Guidelines (ACC/AHA/NASPE Committee to Update the 1998 Pacemaker Guidelines). *J Am Coll Cardiol* 2002;40:1703-19.