

Apical systolic flow within the left ventricle: A novel and simple Doppler parameter in prediction of mitral regurgitation severity

Hacer Ceren Tokgöz¹, Cihangir Kaymaz, Selçuk Öztürk, Alper Özkan, Özgür Yaşar Akbal, Fatih Yılmaz, İbrahim Halil Tanboğa², Nihal Özdemir, Mehmet Mustafa Can³

Clinic of Cardiology, Kartal Koşuyolu Yüksek İhtisas Education and Research Hospital; İstanbul-Turkey

¹Clinic of Cardiology, Haydarpaşa Numune Education and Research Hospital; İstanbul-Turkey

²Clinic of Cardiology, Atatürk University Hospital; Erzurum-Turkey

³Clinic of Cardiology, Bağcılar Education and Research Hospital; İstanbul-Turkey

Effects of the mitral regurgitation (MR) on flow dynamics within the left ventricle (LV) have not been considered in MR grading. We hypothesized that a significant MR may be associated with increased flow velocities within apical part of LV because of a sudden volume shift away from the apex to the left atrium along the backward flow axis. In this study, we proposed a novel and simple Doppler parameter, apical systolic flow (ASF), for MR grading and to evaluate the correlation and reliability of ASF.

The study group comprised 301 patients (F-152, M-149, age: 59±16 years) in whom MR quantitation was performed by transthoracic Doppler echocardiography. Concomitant valve diseases, hypertrophic obstructive cardiomyopathy, congenital heart disease, acute myocardial infarction, and acute MR were exclusion criteria for the study.

Organic MR diagnosis was based on the presence of intrinsic mitral valve lesions with restricted motion (rheumatic or sclerotic) or floppy appearance with redundancy that was revealed by two-dimensional echocardiography and was easily differentiated from functional MR, which was secondary to mobility restriction in structurally normal mitral leaflets because of LV remodeling and/or wall-motion abnormalities.

MR severity was assessed by ratio of MR jet area (JA) to the left atrial area (LAA), vena contract width (VCW), effective regurgitant orifice (ERO) area, and regurgitant volume (RV) derived from proximal isovelocity surface area (PISA) using the previously defined criteria (1-5). For semi quantitative grading, JA/LAA>40% was classified as severe, 20%-30% as moderate, and <20% as MR (3). Nyquist limit settings for PISA and VC measurements were 35-45 cm/sec and 40-60 cm/sec, respectively. RV was calculated from ERO multiplied by time-velocity integral of regurgitant jet. ERO<0.20 cm² and/or RV<30 mL indicated mild,

whereas ERO>0.40 cm² and/or RV>60 mL indicated severe for organic MR (4, 5). The values between these cut-off limits were accepted as moderate MR. ERO>0.20 cm² and RV>30 mL indicated severe for functional MR (6). Because MR diffusely emerged across the line of mitral coaptation, VCW was measured in its minor diameter rather than along the coaptation line. VCW was described as well-defined as light blue or light yellow high-velocity core on the red-blue color Doppler scale by multiple planes. VCW<0.3 cm indicated mild MR, whereas VCW>0.7 cm was consistent with severe regurgitation (2). Left ventricular dP/dt was calculated from the initial slope of MR jet envelope with previously defined method (7). The left ventricle cavity was scanned by pulsed-wave Doppler (PWD) for ASF on the apical four-chamber view and presence of a systolic flow at the distal third of the LV cavity near the apex was defined as ASF (Fig. 1). Sample volume of PWD was 3 mm.

Continuous variables were defined as mean±standard deviation. The Kolmogorov-Smirnov test was used to test the normality of continuous variables. Categorical variables were defined as percent. To compare normally distributed continuous variables, Student's t-test and analysis of variance were used; to compare abnormally distributed continuous variables; Mann-Whitney U and Kruskal-Wallis tests were used; and to compare categorical variables chi-square test were used. To determine the sensitivity; specificity; negative and positive predictive value (NPV and PPV, respectively); and diagnostic accuracy (DA), severe MR absence/presence and ASF absence/presence were tabulated in 2 × 2 Table. The sensitivity, specificity, NPV, PPV and DA were calculated as follow:

$$\text{true_positive (TP)/[TP+false_negative(FN)]},$$

$$\text{true_negative (TN)/[TN+false_positive(FP)]}, \text{ TN/(TN+FN)}, \text{ TP/(TP+FP)}, \text{ (TP+TN)/(TP+TN+FP+FN)}.$$

Address for Correspondence: Dr. Cihangir Kaymaz, Kartal Koşuyolu Yüksek İhtisas Eğitim ve Araştırma Hastanesi, Kardiyoloji Kliniği, 34656, Kartal, İstanbul-Türkiye
Phone: +90 216 500 15 00 Fax: +90 216 459 63 21 E-mail: cihangirkaymaz2002@yahoo.com

Accepted Date: 18.02.2015

©Copyright 2015 by Turkish Society of Cardiology - Available online at www.anatoljcardiol.com
DOI:10.5152/akd.2015.5904



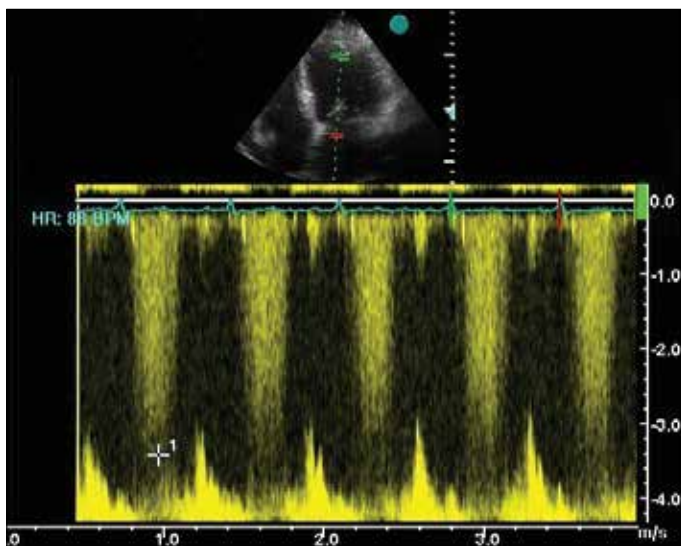


Figure 1. Pulsed-wave Doppler revealed the presence of ASF in a patient with severe MR. There is a holosystolic flow at the distal third of LV near the apex

Table 1. The comparison of subsets with and without apical systolic flow

	ASF absent [n=197 (65%)]	ASF present [n=104 (35%)]	*P value
JA, cm ²	5.43±3.56	12.77±6.84	<0.001
VC, cm	0.5±0.1	0.64±0.2	<0.001
ERO, cm ²	0.11±0.09	0.43±0.15	<0.001
RV, mL	24±14	61±15	<0.001
JA/LAA, %	24.10±13.49	45.17±17.07	<0.001

*Mann-Whitney U Test. ASF- apical systolic flow; ERO- mitral effective regurgitant orifice area; JA and LAA- jet area and left atrial area, respectively; RV- regurgitant volume; VC- vena contracta width

Agreement between the two test or observer was assessed by Kappa statistics. A p value <0.05 was considered as statistically significant. Statistical analyses were performed using SPSS12 (SPSS Inc., Chicago, IL, USA).

ASF was detected in 89% of patients with severe MR, in 38% of patients with moderate MR, and none for mild MR (p<0.05).

The subgroup with ASF had a larger JA (12.77±6.84 vs. 5.43±3.56 cm², p=0.0001), ERO (0.43±0.15 vs. 0.11±0.09 cm², p=0.0001), RV (61±15 vs. 24±14 mL, p=0.0001), higher VC (0.64±0.2 vs. 0.5±0.1 cm, p=0.0001), and JA to LAA ratio (45.17±17.07% vs. 24.10±13.49%, p=0.0001) as compared with those without ASF (Table 1). Therefore, LVdP/dt was comparable between patients with and without ASF (1014±380 vs. 1127±647, p=NS). For severe MR, overall sensitivity, specificity, PPV, and NPV of the presence of any ASF were 89%, 80%, 58%, and 96%, respectively, and DA was 82%. However, overall agreement between presence/absence of ASF and severe/not severe MR was low (Kappa value: -0.168). In central and eccentric MR subsets, ASF's sensitivity for severe MR were 93%, 82%, specificity were 86%, 48.5%, PPV were 58%, 50%, NPV were 98%, 81%, DA were 87%, 61%,

respectively. In organic and ischemic MR subsets, ASF's sensitivity for severe MR were 94%, 82%, specificity were 79%, 84%, PPV were 67%, 54%, NPV were 97%, 95%, and DA were 83%, 84%, respectively. There were substantial agreement between the observer (HCT/IHT) (Kappa value: 0.934) and within observer (HCT) (Kappa value: 0.978).

Discussion

In this study, we proposed ASF as a novel and simple approach for MR grading. This perspective considers the potential effect of backward volume shift from LV to the left atrium on the systolic flow velocities within the apical third of the LV cavity. Finding ASF was closely associated with the severity criteria of MR. ASF revealed a high NPV (96%) for severe MR. However, NPV of ASF was lower in the eccentric MR jets as compared with that in the central jets (81% vs. 98%). It would appear that ASF is effective in determining MR severity independently from LV systolic function due to LVdP/dt and was comparable between patients with and without ASF.

Information concerning MR quantity can be obtained from Doppler echocardiography. This requires both careful quantitation and multifactorial analysis. All methods have some pitfalls for eccentricity of MR jets, changes in loading conditions, color Doppler gain, frame rate, depth and Nyquist limit settings. Therefore, novel technics, such as field optimization method (FOM) automatically calculates the location of orifice area on research for eliminating these pitfalls (8). Recent studies have demonstrated that 3-D PISA method is superior to 2-D PISA method (9, 10). This study is the first to consider apical flow dynamics in LV as a perspective to assess MR severity.

Conflict of interest: None declared.

Peer-review: Externally peer-reviewed.

Authorship contributions: Concept - C.K.; Design - C.K., H.C.T.; Supervision - N.Ö., C.K.; Resource - N.Ö., C.K.; Materials - H.C.T., S.Ö., İ.H.T., M.M.C., A.Ö., Ö.Y.A., F.Y.; Data collection &/or processing - H.C.T., S.Ö., İ.H.T., M.M.C., A.Ö., Ö.Y.A., F.Y.; Analysis&/or Interpretation - H.C.T., S.Ö., İ.H.T., M.M.C., A.Ö., Ö.Y.A., F.Y.; Literature search - H.C.T., C.K.; Writing - H.C.T., C.K.; Critical review - N.Ö., C.K., H.C.T.

References

- Lesniak-Sobelga A, Kostkiewicz M, Olszowska M, Pieniazek P, Tracz W. Chronic mitral regurgitation-significance of echocardiographic determinants in predicting severity. *Acta Cardiol* 2009; 64: 187-93. [\[CrossRef\]](#)
- Lesniak-Sobelga A, Olszowska M, Pieniazek P, Podolec P, Tracz W. Vena contracta width as a simple method of assessing mitral valve regurgitation. Comparison with Doppler quantitative methods. *J Heart Valve Dis* 2004; 13: 608-14.
- Chen C, Thomas JD, Anconina J, Harrigan P, Mueller L, Picard MH, et al. Impact of impinging wall jet on color Doppler quantification of mitral regurgitation. *Circulation* 1991; 84: 712-20. [\[CrossRef\]](#)

4. Khanna D, Miller AP, Nanda NC, Ahmed S, Lloyd SG. Transthoracic and Transesophageal echocardiographic assessment of mitral regurgitation severity: Usefulness of qualitative and semiquantitative techniques. *Echocardiograph* 2005; 22: 748-69. [\[CrossRef\]](#)
5. Enriquez-Sarano M, Miller FA, Hayes SN, Bailey KR, Tajik AJ, Seward JB. Effective mitral regurgitant orifice area: clinical use and pitfalls of the proximal isovelocity surface area method. *J Am Coll Cardiol* 1995; 25: 703-9. [\[CrossRef\]](#)
6. Grigioni F, Enriquez-Sarano M, Zehr KJ, Bailey KR, Tajik AJ. Ischemic mitral regurgitation: long-term outcome and prognostic implications with quantitative Doppler assessment. *Circulation* 2001; 103: 1759-64. [\[CrossRef\]](#)
7. Lesniak-Sobelga A, Olszowska M, Podolec P, Hlawaty M, Tracz W. Assessment of Doppler-derived dP/dt in patients with chronic mitral regurgitation. *Acta Cardiol* 2004; 59: 210-1.
8. Yap CH, Thiele K, Wei Q, Santhanakrishnan A, Khiabani R, Cardinale M, et al. Novel method of measuring valvular regurgitation using three dimensional nonlinear curve fitting of Doppler signals within the flow convergence zone. *IEEE Trans Ultrason Ferroelectr Freq Control* 2013; 60: 1295-311. [\[CrossRef\]](#)
9. Thavendiranathan P, Liu S, Datta S, Rajagopalan S, Ryan T, Igo SR, et al. Quantification of chronic functional mitral regurgitation by automated 3-D peak and integrated proximal isovelocity surface area and stroke volume techniques using real-time 3-D volume color Doppler echocardiography. In vitro and clinical validation. *Circ Cardiovasc Imag* 2013; 6: 125-33. [\[CrossRef\]](#)
10. Maréchaux S, Le Goffic C, Ennezat PV, Semichon M, Castel AL, Delelis F, et al. Quantitative assessment of primary mitral regurgitation using left ventricular volumes: a three-dimensional transthoracic echocardiographic pilot study. *Eur Heart J Cardiovasc Imag* 2014; 15: 1133-9. [\[CrossRef\]](#)