

# Cardiac implantable electronic device lead extraction using the lead-locking device system: keeping it simple, safe, and inexpensive with mechanical tools and local anesthesia

Antonis S. Manolis, Georgios Georgiopoulos, Sofia Metaxa, Spyridon Koulouris, Dimitris Tsiachris

Third Department of Cardiology, Athens University School of Medicine; Athens-Greece

## ABSTRACT

**Objective:** We have previously reported our successful approach for percutaneous cardiac implantable electronic device (CIED) lead extraction using inexpensive tools, which we have continued over the years. Herein we report the results of the systematic use of a unique stylet, the lead-locking device (LLD), which securely locks the entire lead lumen, aided with non-powered telescoping sheaths in 54 patients to extract 98 CIED leads.

**Methods:** This prospective observational clinical study included 38 men and 16 women aged  $68.9 \pm 13.1$  years undergoing lead extraction for device infection ( $n=46$ ), lead malfunction ( $n=5$ ), or prior to defibrillator implant ( $n=3$ ). Leads were in place for  $6.7 \pm 4.3$  years. Infections were more commonly due to *Staphylococcus* species ( $n=40$ ). There were 78 pacing (31 ventricular, 37 atrial, 4 VDD, and 6 coronary sinus leads) and 20 defibrillating leads.

**Results:** Using simple traction (6 leads) and the LLD stylets (92 leads) aided with telescoping sheaths (15 patients), 96 (98%) leads in 52 (96.3%) patients were successfully removed, with all but one leads removed using a subclavian approach; in 1 patient, the right femoral approach was also required. In 2 patients, distal fragments from one ventricular pacing and one defibrillating lead could not be removed. Finally, lead removal was completely (52/54) (96.3%) or partially (2/54) (3.7%) successful in 54 patients for 96 of 98 leads (98%) without major complications.

**Conclusion:** Percutaneous lead extraction can be successful with mechanical tools using the LLD locking stylet aided with non-powered telescoping sheaths through a simplified, safe, and inexpensive procedure using local anesthesia alone. (*Anatol J Cardiol* 2017; 18: 289-95)

**Keywords:** cardiac implantable electronic devices, pacing lead, defibrillating lead, lead extraction, pacemaker infection, lead malfunction

## Introduction

The need for lead extraction of cardiac implantable electronic devices (CIEDs), including pacemakers, defibrillators (ICD), and cardiac resynchronization therapy (CRT) devices, is increasing (1) because the number of device implantations and their attendant complications along with the infection burden associated with the implantation are increasing over time (2, 3) and because malfunctioning and recalled leads continue to emerge (4).

Percutaneous extraction of infected or dysfunctional CIED leads has supplanted surgical techniques with great success (5-7). Current methods employ mechanical and/or laser equipment with variable success rates. The locking stylet has remained the principal tool in these techniques, whereas the telescoping (powered or non-powered) mechanical or laser sheaths serve as the most important ancillary tool. Various locking mechanisms have been used, but most of them in addition to requiring tedious and exact sizing of the stylet to match

the lead lumen, lock at the tip of the lead, which may not always be readily accessible. Newer types of locking stylets have simplified the sizing process and facilitated and strengthened the locking mechanism. Cognizant of the expense entailed with powered mechanical means, particularly that of the prohibitive cost for our practice of the laser technique, our standard approach over the years has included only mechanical means using a locking stylet, non-powered sheaths, and other ancillary tools, with all procedures performed under local anesthesia. We have previously reported our experience with various types of locking stylets with exclusive distal tip locking (8, 9), and we are herein extending it with use of another type of stylet, the lead-locking device (LLD) (Spectranetics, Colorado Springs, CO, USA), which when locked, occupies the lumen of the lead over its entire length, in a group of 54 consecutive patients who also required some additional tools (mostly non-powered sheaths) for lead extraction, attempting to extract 98 pacemaker, ICD, and CRT leads.

**Address for correspondence:** Antonis S. Manolis, MD, Ippokratio Hospital, Vas. Sofias 114, Athens-Greece  
Phone: +30-213-2088470 Fax: +30-213-2088676 E-mail: asm@otenet.gr

**Accepted Date:** 23.06.2017 **Available Online Date:** 11.08.2017

©Copyright 2017 by Turkish Society of Cardiology - Available online at [www.anatoljcardiol.com](http://www.anatoljcardiol.com)  
DOI:10.14744/AnatolJCardiol.2017.7821



## Methods

### Study design

This was a prospective observational clinical study.

### Patients

Over a period of 10 years, pacing, ICD, or CRT lead extraction using the LLD system was attempted in 54 consecutive patients who were referred to our institutions for percutaneous lead removal; we excluded patients (n=5) for whom different extraction means were employed. Prospective data were recorded for all patients and procedures. The indication for lead removal was device infection (46 patients), pacing (2 patients), or ICD (3 patients) lead dysfunction or the removal was performed prior to an ICD implantation (3 patients) (Table 1). Infections involved both pocket and lead(s) and were mainly due to *S. epidermidis* (n=34). Skin erosion was present in 16 patients. Positive blood cultures were detected in 9 (19.6%) of 46 patients with infection. Echocardiography revealed small-/moderate-sized vegetations on the right ventricular pacing leads in 4 patients. No patient had evidence of pulmonary embolism. The indication for permanent pacemaker implantation (n=34) was sinus node dysfunction in 9 patients, neurally mediated syndromes in 2 patients, and atrio-ventricular block in 23 patients. Sustained ventricular tachycardia was the indication for ICD implantation in 14 patients, whereas 6 patients with refractory heart failure had a CRT system implanted.

### Type of extracted leads

The specific types of extracted leads can be seen in Table 1. Pacing leads (37 atrial, 35 ventricular, and 6 coronary sinus) had been implanted in 78 patients. Defibrillating leads had been implanted in 20 patients. Leads had been in place for a mean of 6.7±4.3 years (range 0.3–19 years). The fixation mechanism of implanted leads was passive in 92 leads and active (screw-in) in 6 leads. Of the 78 pacing leads, 4 were unipolar ventricular, 21 bipolar ventricular, 6 bipolar CS, 1 unipolar atrial, 36 bipolar atrial, 4 unipolar single-pass VDD, all tined, and 6 bipolar screw-in atrial (n=2) or ventricular (n=4) leads. The ICD defibrillation leads were tined or active fixation double-coil (n=18) or single-coil (n=2) leads.

### Locking stylet and telescoping sheaths

The LLD locking stylet comprises an expandable wire mesh woven around a stylet, which when inserted and locked in place, occupies the whole lumen of the lead over the entire length of the stylet body, allowing for traction along the whole lead and not just at its tip (Fig. 1). It was available to us in 2 sizes (LLD#1 and LLD#2). It can accommodate a wide range of leads with inner lumen diameters ranging from 0.017" (0.43 mm) to 0.026" (0.66 mm) for LLD#2. By locking along the entire lead lumen, it provides a stable traction platform. The plastic telescoping sheaths used in this series for the dissection of lead adhesions and to provide

**Table 1. Clinical characteristics of 54 patients undergoing percutaneous lead extraction with the LLD system**


Men/women	38/16
Age, years, range	68.9±13.1 (37–87)
Indication for extraction	
Device infection	46 (85.2%)
<i>Staphylococci</i>	40
<i>Staphylococci</i> + other	4
Other bacteria	2
Lead dysfunction	5 (9.3%)
Pacing lead	2
ICD lead	3
Prior to ICD implant	3 (5.6%)
Skin erosion	16 (29.6%)
Time since initial implantation (years)	6.7±4.3 (0.3–19)
Number of leads	98
Devices, Pacemakers	34
ICDs	14
CRT	6
Type of leads	
Pacing	78 (78.6%)
Ventricular	35 (35.7%)
Bipolar	27
Active fixation	2
Single-pass unipolar VDD	4 (4.1%)
CS	6 (6.1%)
Atrial	37 (37.8%)
Bipolar	36
Active fixation	2
Defibrillating	20 (20.4%)
2 coil	18

Data are presented as mean±standard deviation (range) or number and percentages. CRT - cardiac resynchronization therapy; CS - coronary sinus; ICD - implantable cardioverter defibrillator; LLD - lead-locking device

counter traction were the ones used in our prior series, the mechanical, non-powered, S and L short Extor sheaths (VascoMed GmbH, Binzen, Germany) with inner diameters of 8.5F and 12.5F, respectively.

### Procedure of lead extraction

All procedures were performed after an informed written consent was obtained from each patient. Each case was also discussed with our cardiothoracic surgeon who covered the procedure. For the pacemaker-dependent patients, a temporary pacing wire was inserted usually from the internal jugular vein or occasionally from the contralateral subclavian vein. Then, with use of sterile and aseptic technique and local anesthesia,



**Figure 1.** The LLD locking stylet is depicted in this figure in its unlocked, locked state when deployed (locked) inside the lead lumen. Of note is the apparent expanded mesh appearance of the locking mechanism, allowing for a more uniform traction along several points along the lead body

the CIED pocket was opened and the pulse generator was removed after disconnecting the lead(s). Each lead was freed from adhesions and the anchoring sleeve in the pocket all the way to the vascular entrance. The lead connector was then severed at the proximal end. A test stylet was inserted into the lead lumen and advanced under fluoroscopy guidance to the tip of the lead to remove any material from the lumen and facilitate the passage of the locking stylet via the inner coil. Then the locking stylet was inserted, advanced to the tip of the lead, and fixed by the locking mechanism described above. Finally, lead removal was attempted by slowly pulling on the traction cord of the extractor under fluoroscopy.

When it was obvious that there were binding sites limiting the free movement of the lead, telescoping sheaths were employed to free the lead from local adhesions along the intravascular and intracardiac route. With traction maintained on the locking stylet, the beveled distal end of the sheath was advanced over the lead body under fluoroscopy by alternate clockwise and counter-clockwise manual rotation following the lead course, avoiding any angulation and trying to reach the tip of the lead. Particular attention and caution with gentle maneuvering was applied at the region of the neck vessels to avoid local injury of the superior vena cava or the brachiocephalic vein that could be devastating. Once the lead tip was reached, counter-traction maneuvering was applied to free the anchored tip of the lead, wherein the lead and sheath were removed en bloc through the insertion vein. Active fixation leads were unscrewed before applying counter traction.

For leads that could not be extracted using the above approach (subclavian route), the transfemoral approach was utilized. After lead extraction, the wound in the infraclavicular area was debrided if infected, the pacemaker pocket was plicated, and wound closure was effected in layers using absorbable sutures, allowing healing by primary intention. After the procedure, the patients were monitored overnight in the cardiac care unit. For patients with an infected system, intravenous antibiotic therapy was continued for 4–6 weeks as appropriate; a new device

system was implanted, usually on the contralateral side, after 10–14 days had elapsed and when the device pocket was clean of any signs of infection and laboratory testing indicated that inflammatory or infection indices had returned to normal. For patients with non-infected systems, a new system was implanted either during the same session or the next day. After hospital discharge, all patients were followed up at the pacemaker clinic and by their own referring physicians.

### Statistics

The data are expressed as mean±standard deviation (range) and/or percentages. Comparisons were made using the Student's unpaired t-test for quantitative data and chi-square analysis and z-statistic for qualitative and proportional data. Correlation between variables was calculated using the Pearson correlation coefficient. Data were analyzed with SPSS 23 (Armonk, NY). A p value of <0.05 was considered significant.

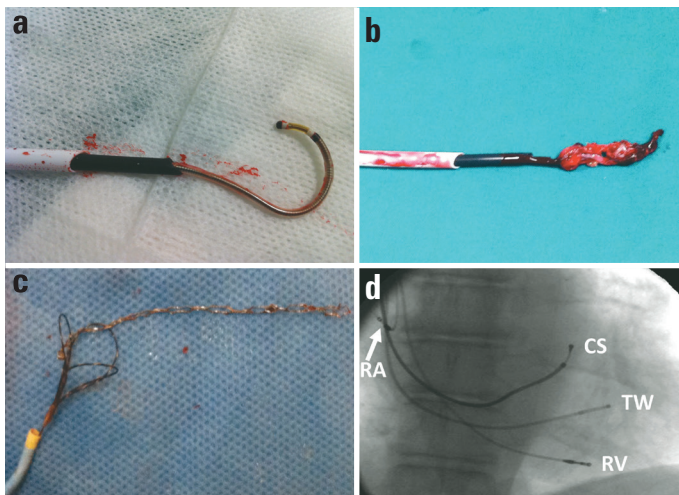
### Results

#### Procedural outcome

In preparation for the extraction procedure, a temporary pacemaker electrode catheter was inserted in 8 (14.8%) patients who were pacemaker dependent. Lead extraction was attempted in 54 patients for a total of 98 leads (78 pacing and 20 ICD defibrillating leads). Complete removal of all leads was successful in 52 (96.3%) patients for 96 (98%) leads; partial lead removal with retention of a lead fragment was obtained in 2 patients. Both patients with retained ventricular lead fragments were patients with device infections: 1 with a single-chamber ventricular pacemaker and a lead dwell time of 15 years and the other with an atrioventricular ICD device implanted 13.4 years earlier. The former patient did well conservatively, responding to antibiotic therapy, whereas the other patient preferred elective surgery over a transfemoral approach for the removal of the retained ICD lead fragment. The LLD#1 stylet was used in 2 patients and the LLD #2 stylet in 52 patients. Successful removal was attained using a right (n=28) or left (n=24) or right plus left (n=1) subclavian or right subclavian plus femoral (n=1) approach. Lead extraction was accomplished by simple traction for 4 atrial, 1 ventricular, and 1 coronary sinus lead (only test stylet inserted), sole use of the locking stylet for 60 (47.4%) leads in 39 (58%) patients, locking stylet aided by non-powered sheaths for 27 leads, and a femoral approach for 1 ventricular lead. The procedures lasted for 1.2±0.9 h (range 20 min to 5 h), with a fluoroscopy time of 9.0±6.7 min.

#### Use of a non-powered telescopic sheath

In addition to the locking stylet, telescoping sheaths to aid lead extraction were required for 27 (27.6%) leads in 15 patients (27.8%) (Fig. 2a, b; Table 2). The transfemoral approach was needed in 1 patient. In 1 patient with a dual chamber pacemaker and 2 bipolar leads, the stylet was used successfully to remove the



**Figure 2.** Telescoping sheaths are an invaluable tool to dissect through the adhesions formed in various contact points along the endovenous and endocardial course of the lead and to facilitate its extraction (a) as well as to apply counter traction at the lodging point of a ventricular lead anchored at the endocardium, aiding in disengaging the lead often with a thick fibrous tissue attached to it (b), hopefully, without the feared complication of cardiac perforation and tamponade. When the above approach (subclavian access) fails, a transfemoral approach using a snare can successfully remove even grossly uncoiled and deformed leads and their fragments (c). The LLD plus telescoping sheath method is equally effective in removing multiple leads, including those in the coronary sinus (d)

CS - (lead already pulled in the) coronary sinus (from a vein tributary); RA - right atrial (lead); RV - right ventricular (lead); TW - temporary wire

atrial lead using a right subclavian approach, and a biopptome and a snare were used to capture and remove the ventricular lead via a transfemoral approach after attempts from above had failed (Fig. 2c). Coronary sinus leads were successfully removed in 6 (6.1%) patients (Fig. 2d); telescoping sheaths were used in 2 patients.

### Transfemoral approach

As already indicated, in 1 patient with a dual-chamber pacemaker, a right subclavian approach was successful in removing the atrial lead with use of the LLD stilet aided by a sheath, but the ventricular lead could not be extracted using the approach from above and thus a transfemoral approach was used for this purpose. The lead was severed proximally, a biopptome was used to capture and release the proximal end of the lead, and then a snare (Noose catheter, VascoMed GmbH, Binzen, Germany) was used to successfully extract this lead (Fig. 2c).

### Complications

No major complications occurred in this series of patients during the procedures of percutaneous lead extraction. A moderate-sized hematoma developed in the pocket of 2 patients who had extensive local debridement. Vagotonia occurred in 2 patients; in one of them, ventricular ectopy with frequent extrasystoles and runs of non-sustained ventricular tachycardia were also observed during lead traction. The latter patient was the one who was submitted to a femoral approach to remove the

**Table 2. Procedural characteristics of 54 patients submitted to percutaneous extraction of 98 leads**

	Patients	Leads
Need for temporary pacemaker	8	–
Approach		
Infraclavicular	54	97
+ Transfemoral	1	1
Simple traction	6	6
Locking stilet (LLD)	48	90
Telescoping sheaths	15	27
Non-powered	15	27
Powered	0	0
Other ancillary tools		
Snare + biopptome	1	1
Success		
Complete removal	52 (96.3%)	96 (98%)
Partial removal	2 (3.7%)	2 (2%)
Complications		
Death	0	
Tamponade	0	
Local hematoma	2	
Vagotonia	1	
Vagotonia/NSVT/Femoral vein trauma	1	
Data are presented as number and/or percentages. NSVT - non-sustained ventricular tachycardia		

ventricular lead and this was complicated by femoral vein trauma, which was repaired with suturing.

### Correlations

The duration ( $r=48$ ,  $p=0.0002$ ) and fluoroscopy time ( $r=0.54$ ,  $p=0.0001$ ) of the procedure correlated with the lead dwell time; both parameters were longer in males than in females ( $p<0.05$ ). Also, patients requiring a telescoping sheath had longer lead dwell time ( $105.3\pm 46.2$  months vs.  $72.3\pm 51.4$  months;  $p=0.035$ ). Finally, the use of a mechanical sheath incurred longer procedure ( $1.7\pm 1.2$  h vs.  $0.9\pm 0.6$  h;  $p=0.004$ ) and fluoroscopy times ( $13.1\pm 8.8$  min vs.  $7.6\pm 5.1$  min;  $p=0.006$ ).

### Discussion

The results of the present study indicate that percutaneous lead extraction can be successful with mechanical tools using the LLD stilet owing to its unique locking mechanism aided by non-powered telescoping sheaths through a simplified, safe, and inexpensive procedure using local anesthesia alone. Thus, we were able to completely extract 96 of 98 (98%) CIED leads, with a mean implant time of 6.7 years. To the best of our knowledge, this is the second series of patients reported in the



literature with the systematic use of the LLD system. In a prior report of the initial multicenter series of 57 patients using the LLD device for extraction of 99 leads combined with a variety of sheaths, 97/99 (98%) leads were successfully removed with no major complications (10).

Implantation of CIEDs has markedly increased over the past several years due to expanded indications (2, 11-13). Device systems include pacemakers, ICDs, and CRT systems (13-15). Unfortunately, complications associated with CIEDs have also been increasing (3, 4, 16). Particularly, device infections appear to be rising out of proportion to increasing implant rates (17). Furthermore, device recipients who develop device infection have increased device-dependent, long-term mortality even after successful treatment of infection (18). The only way to deal with this grisly reality is to take extra measures to prevent or minimize CIED infections by performing a *lege artis* procedure (19). Thus, in parallel to the increasing complications, there is a growing need for lead extraction to manage such complications (1). Device infection was the main indication for lead extraction in 47 of 54 (87%) patients in this series referred to our centers for the extraction procedure, wherein 9 (19%) of these had developed lead endocarditis.

Extraction of pacemaker and ICD leads has been performed via percutaneous techniques, which have virtually supplanted the surgical approach (1). Lead extraction is quite challenging, particularly for leads implanted for longer periods of time (5, 6). This is because endocardial leads develop encapsulation by fibrous tissue not only at the distal tip, which is in contact with the endomyocardium, but also along the endovenous or endocardial course of the lead(s), where fibrous adhesions impede the extraction (20). Hence, special tools are required to pave the way and facilitate lead extraction. When dealing with infection, the presence and size of vegetation may pose further risk to percutaneous methods (21).

Among the techniques employed, the most widely used lead extraction system is the Cook retrieval system (Cook Vascular, Inc., Vandergrift, PA) in addition to a variety of other tools and systems (5). Success is higher for physicians with greater experience, shorter implant duration, active fixation, and atrial leads. A femoral approach is required in a small percentage of patients. Major complication rates of 0.7%–3.5% have been reported (1, 5-7, 22), including hemopericardium and tamponade, hemothorax, pulmonary embolism, migrating lead fragment, bacteremia, stroke, and ventricular tachycardia. Procedure-related deaths have been reported at a rate of 0.3%–0.8% along with in-hospital mortality of approximately 2%. However, certain risk factors highly increase the in-hospital mortality to 4.3% for endocarditis, 7.9% for endocarditis and diabetes, and 12.4% for endocarditis and renal insufficiency (23).

The advent of the laser sheath (22, 23) and lately of powered mechanical sheaths (24-30) has been heralded as a major advance in the field of percutaneous lead extraction, albeit at a much greater or prohibitive financial cost at least for the laser

sheath. Moreover, their advantages over other tools may be further downgraded by significant risks for life-threatening complications associated with their use. Indeed, in a meta-analysis of 62 studies spanning a 15-year period and comprising 13,000 patients with 20,000 leads undergoing extraction (25), with an overall success rate of 94% and major complications in 1.7% with 0.3% mortality, among other factors, the use of a laser sheath was associated with an increased risk of major complications or death ( $p=0.029$ ) despite being associated with higher technical success of extraction ( $p=0.003$ ). Use of powered sheaths may entail major complication rates varying from 0% to 4.8%, with procedure-related mortality of up to 2.4% (24, 25). However, experience with a new version of the powered mechanical sheath is very encouraging (26-29). A recent report of a large patient series indicates that modern mechanical methods may improve success rate and also lower complication rate, although a greater need for a femoral approach may emerge (30).

To avoid the expense and effort of sizing in stylet selection and lead matching entailed using the old Cook retrieval system, in the past, we had used the universally applied types and versions of locking stylets (8, 9). These systems also came with non-powered mechanical plastic telescoping sheaths to be used via a transclavian approach as well as with a transfemoral kit that included a noose catheter (snare) for lead extraction from the femoral vein, which we are still using. However, there were problems with the availability of these old stylets; thus, we subsequently resorted to the LLD type, which admittedly has an easier and more effective locking mechanism that involves the entire lead body and length (Fig. 1). Furthermore, we adopted a more frequent use of beveled sheaths to facilitate the extraction process, particularly for leads of a longer implant duration. These measures appeared to obviate the need to resort to a transfemoral approach, which was needed in only 1 patient in the current series, and also avoided the need to use an array of ancillary tools required in 27% in our previous experience (9). Most importantly, the use of the LLD system was safe with no major complications observed during the procedures. Based on our prior experience, persistence of using only traction via the other types of locking stylets was probably responsible for the occurrence of cardiac tamponade in a paraplegic patient with severe left ventricular dysfunction and infective endocarditis (not included in this series), who subsequently required cardiac surgery but finally succumbed to a low cardiac output state.

With regard to coronary sinus leads, no difficulties were encountered in 6 patients undergoing lead removal in our series. Other series have also confirmed the feasibility of extracting such leads without any additional problems that were initially anticipated, except for a certain type of active fixation leads (31).

## Study limitations

This study was not a randomized controlled trial. It was rather our experience in our lead extraction program based on a relatively small series of patients. However, the data were pro-

spectively collected for all patients. The study included all consecutive patients in whom the LLD system was utilized but not all consecutive patients undergoing lead extraction because there were few other patients during the study period depending on tool availability, in whom other extraction means were employed. A potential drawback of our extraction approach may be associated with the unavailability of a powered mechanical sheath system, which most likely led to a relatively long procedural time (4–5 h) in 3 patients in the current series. Finally, although we found the LLD stylet easier to use and rather more effective than its predecessors, we cannot comment on the relative merits of the other commonly used locking stylet (Liberator by Cook Medical) because we have only recently started using it.

## Conclusion

The LLD lead extraction system with a uniform whole lumen/entire lead length applicable locking stylet aided by mechanical sheaths appears to be simple to operate, safe, and quite successful in chronically implanted lead extraction and can be applied without the need of general anesthesia through a low-cost approach. Further studies in larger patient populations are needed to confirm these results and randomized comparative, and cost-effectiveness studies are necessary for the currently available lead removal systems.

**Acknowledgment:** We express our deep appreciation to the Staff of our Electrophysiology laboratories for their most valuable assistance in these procedures.

**Conflict of interest:** None declared.

**Peer-review:** Externally peer-reviewed.

**Authorship contributions:** Concept – A.S.M.; Design – A.S.M.; Supervision – A.S.M.; Data collection &/or processing – A.S.M., S.M., S.K.; Analysis &/or interpretation – A.S.M., G.G., S.M., S.K., D.T.; Literature search – A.S.M., S.M.; Writing – A.S.M.; Critical review – A.S.M., G.G., S.M., S.K., D.T.

## References

1. Deharo JC, Bongiorno MG, Rozkovec A, Bracke F, Defaye P, Fernandez-Lozano I, et al. Pathways for training and accreditation for transvenous lead extraction: a European Heart Rhythm Association position paper. *Europace* 2012; 14: 124-34.
2. Mond HG, Proclemer A. The 11<sup>th</sup> world survey of cardiac pacing and implantable cardioverter-defibrillators: calendar year 2009--a World Society of Arrhythmia's project. *Pacing Clin Electrophysiol* 2011; 34: 1013-27.
3. Greenspon AJ, Patel JD, Lau E, Ochoa JA, Frisch DR, Ho RT, et al. 16-year trends in the infection burden for pacemakers and implantable cardioverter-defibrillators in the United States 1993 to 2008. *J Am Coll Cardiol* 2011; 58: 1001-6.
4. Grazia Bongiorno M, Dagues N, Estner H, Pison L, Todd D, Blomstrom-Lundqvist C, et al. Management of malfunctioning and re-called pacemaker and defibrillator leads: results of the European Heart Rhythm Association survey. *Europace* 2014; 16: 1674-8.
5. Smith HJ, Fearnot NE, Byrd CL, Wilkoff BL, Love CJ, Sellers TD. Five-years experience with intravascular lead extraction. *U.S. Lead Extraction Database. Pacing Clin Electrophysiol* 1994; 17: 2016-20.
6. Bongiorno MG, Soldati E, Zucchelli G, Di Cori A, Segreti L, De Lucia R, et al. Transvenous removal of pacing and implantable cardiac defibrillating leads using single sheath mechanical dilatation and multiple venous approaches: high success rate and safety in more than 2000 leads. *Eur Heart J* 2008; 29: 2886-93.
7. Kennergren C, Bjurman C, Wiklund R, Gabel J. A single-centre experience of over one thousand lead extractions. *Europace* 2009; 11: 612-7.
8. Manolis AS, Maounis TN, Chiladakis J, Vassilikos V, Melita-Manolis H, Cokkinos DV. Successful percutaneous extraction of pacemaker leads with a novel (VascoExtor) pacing lead removal system. *Am J Cardiol* 1998; 81: 935-8.
9. Manolis AS, Maounis TN, Vassilikos V, Chiladakis J, Melita-Manolis H, Cokkinos DV. Ancillary tools in pacemaker and defibrillator lead extraction using a novel lead removal system. *Pacing Clin Electrophysiol* 2001; 24: 282-7.
10. Kennergren C, Schaerf RH, Sellers TD, Wilkoff BL, Byrd CL, Tyres GF, et al. Cardiac lead extraction with a novel locking stylet. *J Interv Card Electrophysiol* 2000; 4: 591-3.
11. Manolis AS. Cardiac resynchronization therapy in congestive heart failure: Ready for prime time? *Heart Rhythm* 2004; 1: 355-63.
12. Manolis AS. Need for a permanent pacemaker after transcatheter aortic valve implantation (TAVI). *Rhythm* 2016; 11: 87-9.
13. Mond HG, Crozier I. The Australian and New Zealand cardiac pacemaker and implantable cardioverter-defibrillator survey: calendar year 2013. *Heart Lung Circ* 2015; 24: 291-7.
14. Manolis AS, Maounis T, Vassilikos V, Chiladakis J, Cokkinos DV. Electrophysiologist-implanted transvenous cardioverter defibrillators using local versus general anesthesia. *Pacing Clin Electrophysiol* 2000; 23: 96-105.
15. Manolis AS, Maounis T, Koulouris S, Vassilikos V. "Real life" longevity of implantable cardioverter-defibrillator devices. *Clin Cardiol* 2017 May 22. Epub ahead of print.
16. Kirkfeldt RE, Johansen JB, Nohr EA, Jorgensen OD, Nielsen JC. Complications after cardiac implantable electronic device implantations: an analysis of a complete, nationwide cohort in Denmark. *Eur Heart J* 2014; 35: 1186-94.
17. Manolis AS, Melita H. Managing infected cardiovascular implantable electronic devices. *Contin Cardiol Educ* 2016; 2: 182-91.
18. Rizwan Sohail M, Henrikson CA, Jo Braid-Forbes M, Forbes KF, Lerner DJ. Increased long-term mortality in patients with cardiovascular implantable electronic device infections. *Pacing Clin Electrophysiol* 2015; 38: 231-9.
19. Manolis AS, Melita H. Prevention of Cardiac Implantable Electronic Device Infections: Single Operator Technique with Use of Povidone-Iodine, Double Gloving, Meticulous Aseptic/Antiseptic Measures and Antibiotic Prophylaxis. *Pacing Clin Electrophysiol* 2017; 40: 26-34.
20. Candinas R, Duru F, Schneider J, Luscher TF, Stokes K. Postmortem analysis of encapsulation around long-term ventricular endocardial pacing leads. *Mayo Clin Proc* 1999; 74: 120-5.
21. Baddour LM, Epstein AE, Erickson CC, Knight BP, Levison ME, Lockhart PB, et al. Update on cardiovascular implantable electronic device infections and their management: a scientific statement from the American Heart Association. *Circulation* 2010; 121: 458-77.

22. Wilkoff BL, Byrd CL, Love CJ, Hayes DL, Sellers TD, Schaerf R, et al. Pacemaker lead extraction with the laser sheath: results of the pacing lead extraction with the excimer sheath (PLEXES) trial. *J Am Coll Cardiol* 1999; 33: 1671-6.
23. Wazni O, Epstein LM, Carrillo RG, Love C, Adler SW, Riggio DW, et al. Lead extraction in the contemporary setting: the LEXIcon study: an observational retrospective study of consecutive laser lead extractions. *J Am Coll Cardiol* 2010; 55: 579-86.
24. Mazzone P, Tsiachris D, Marzi A, Cicone G, Paglino G, Sora N, et al. Advanced techniques for chronic lead extraction: heading from the laser towards the evolution system. *Europace* 2013; 15: 1771-6.
25. Diemberger I, Mazzotti A, Giulia MB, Cristian M, Matteo M, Letizia ZM, et al. From lead management to implanted patient management: systematic review and meta-analysis of the last 15 years of experience in lead extraction. *Expert Rev Med Devices* 2013; 10: 551-73.
26. Starck CT, Steffel J, Calışkan E, Holubec T, Schoenrath F, Maisano F, et al. Clinical performance of a new bidirectional rotational mechanical lead extraction sheath. *Europace* 2016; 18: 253-6.
27. Delnoy PP, Witte OA, Adiyaman A, Ghani A, Smit JJ, Ramdat Misier AR, et al. Lead extractions: the Zwolle experience with the Evolution mechanical sheath. *Europace* 2016; 18: 762-6.
28. Witte OA, Adiyaman A, Smit JJ, Ramdat Misier AR, Elvan A, Ghani A, et al. Success and complication rates of lead extraction with the first- vs. the second-generation Evolution mechanical sheath. *Europace* 2016 Oct 6. Epub ahead of print.
29. Mazzone P, Migliore F, Bertaglia E, Facchin D, Daleffe E, Calzolari V, et al. Safety and efficacy of the new bidirectional rotational Evolution(R) mechanical lead extraction sheath: results from a multicentre Italian registry. *Europace* 2017 Feb 23. Epub ahead of print.
30. Domenichini G, Gonna H, Sharma R, Conti S, Fiorista L, Jones S, et al. Non-laser percutaneous extraction of pacemaker and defibrillation leads: a decade of progress. *Europace* 2017 Mar 17. Epub ahead of print.
31. Crossley GH, Sorrentino RA, Exner DV, Merliss AD, Tobias SM, Martin DO, et al. Extraction of chronically implanted coronary sinus leads active fixation vs passive fixation leads. *Heart Rhythm* 2016; 13: 1253-9.



Biochemist, MD. Meral Eguz's collections