

Type IV dual left anterior descending artery misdiagnosed as chronic total occlusion 🎥

👤 Ismail Gürbak, 👤 Cafer Paç

Department of Cardiology, İstanbul Medical Sciences University, Mehmet Akif Ersoy Thoracic and Cardiovascular Surgery Training and Research Hospital; İstanbul-Turkey

Introduction

Coronary artery anomalies are rare and generally benign clinical situations seen in 1.3% of the total population (1). Dual left anterior descending artery (LAD) has a variant course and is formed from two branches of LAD defined as short and long LAD. Several types of LAD have been described in the literature (2-4). Type IV dual LAD is a very rare form. The short LAD originates from left main coronary artery (LMCA) and terminates proximally in anterior interventricular sulcus (AIVS) giving off diagonal and septal branches. The long LAD originates from right sinus Valsalva passing through the anterior of infundibulum of the right ventricle and terminates in distal AIVS. In this case report, we present a patient with type IV dual LAD misdiagnosed as chronic total occlusion of LAD.

Case Report

A 53-year-old female patient with a history of hypertension and coronary artery bypass grafting (CABG) was admitted to our outpatient clinic. She presented with typical chest pain with increased intensity recently. Her CABG was performed 6 months ago, and her anginal symptoms were continuing since that time. A single left internal mammary artery (LIMA) graft to LAD was harvested because of totally occluded LAD in CABG according to the surgical report. Physical examination and electrocardiogram results and cardiac enzymes were normal. Echocardiography showed hypokinesia of basal inferior septum with normal left ventricle functions and valves. The patient underwent coronary angiography with the diagnosis of unstable angina pectoris. Angiography revealed that the LAD was thin and terminating proximally after giving off a large diagonal branch (Fig. 1, 2, Video 1, 2). A LIMA graft was harvested to the diagonal artery instead of the LAD, and the LIMA graft was being maintained by retrograde flow from the diagonal artery (Fig. 2, Video 3, 4). When RCA was visualized, a vessel was observed from the right coronary sinus traveling toward AIVS (Video 5). When this vessel was selective-

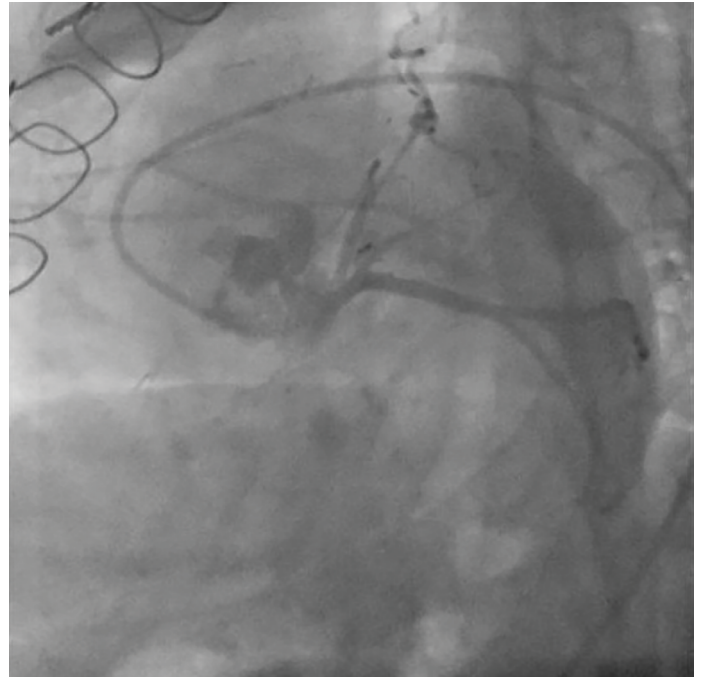


Figure 1. Left anterior oblique and caudal views showing short left anterior descending artery

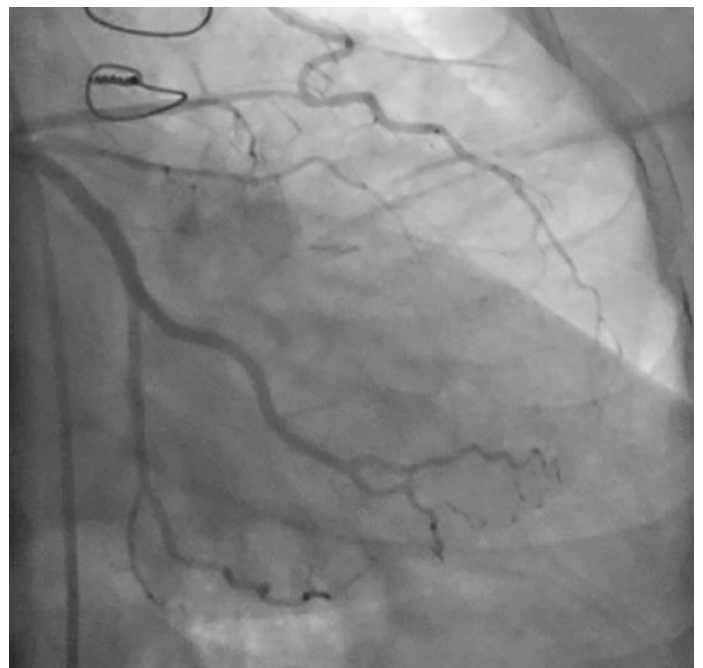


Figure 2. Right anterior oblique and caudal view of short left anterior descending artery and left internal mammary artery anastomosis

ly cannulated, we noticed that the vessel was misdiagnosed as a retrograde collateral flow toward LAD which was supposed to be occluded and the patient had a type IV dual LAD anomaly (Fig. 3, 4, Video 3, 4). We performed 3D imaging with CT angiography to confirm our diagnosis (Fig. 5, 6, 7). We presume that early termi-

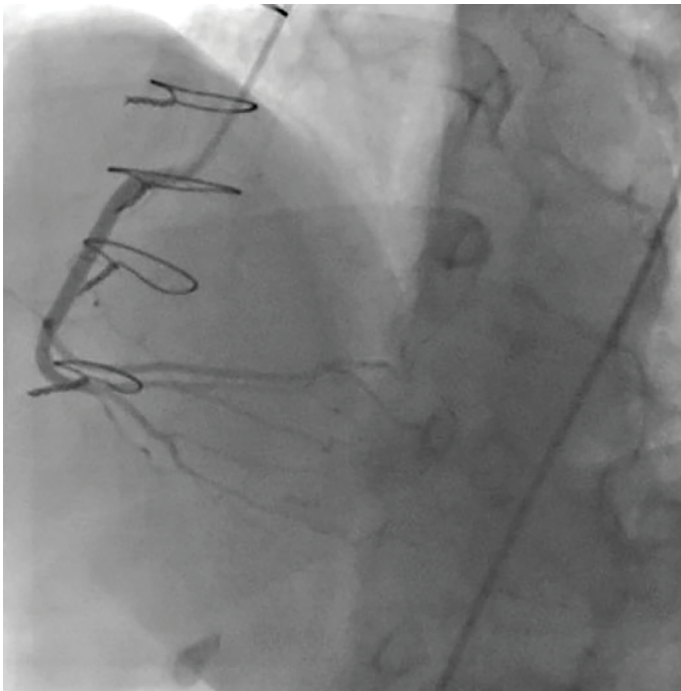


Figure 3. Left anterior oblique view of right coronary artery and deep engagement of the catheter

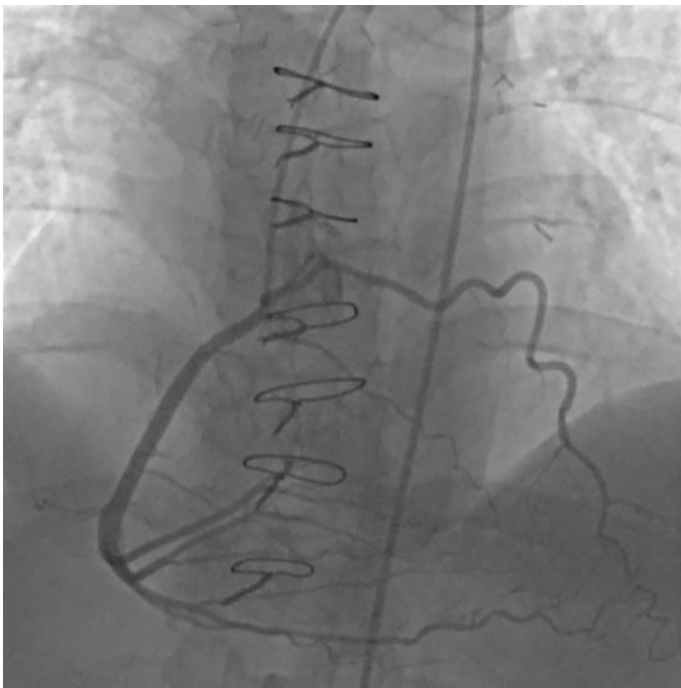


Figure 4. Left anterior oblique view of right coronary artery and long left anterior descending artery originated from right coronary sinus

nation of short LAD in AIVS was considered as total occlusion by the surgical team, and probably due to the deep engagement of the catheter to RCA, the vessel from the right coronary sinus was overlooked (Fig. 3, 4, 7, Video 3). We planned medical treatment for the patient and assumed that the symptoms were related to competing arteries.

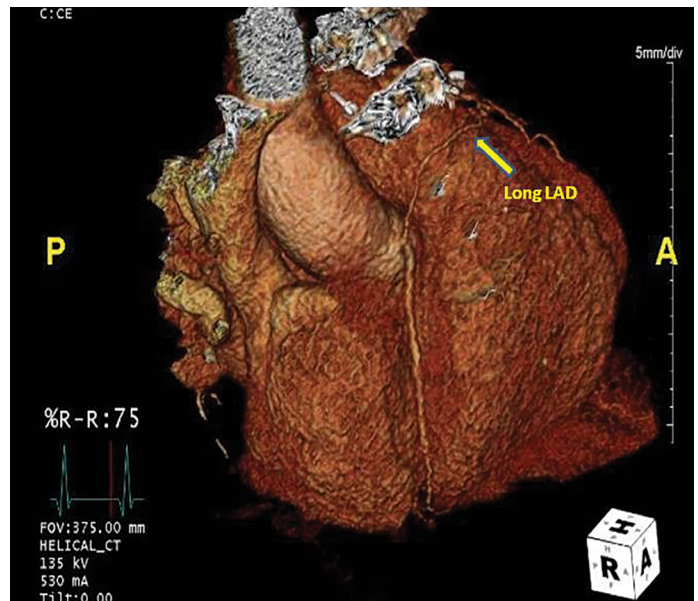


Figure 5. Three-dimensional volume-rendered computed tomography angiography image shows right coronary artery and long left anterior descending artery originated from right coronary sinus

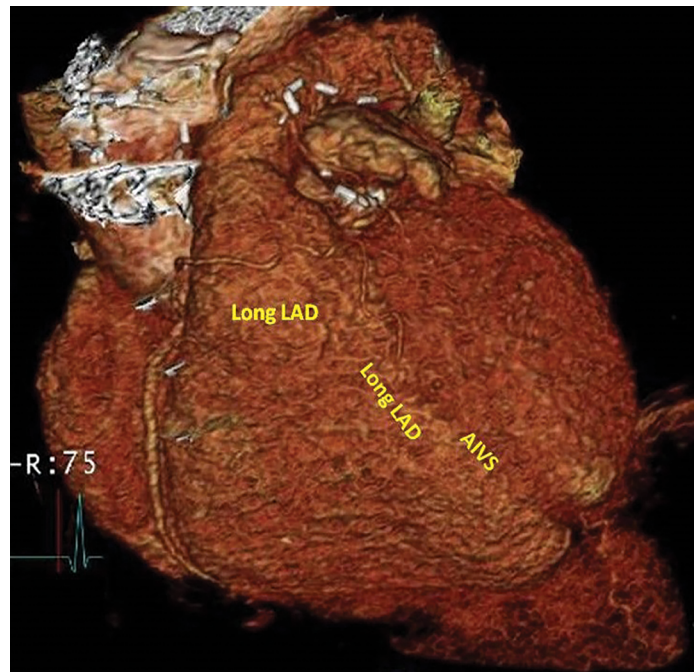


Figure 6. Three-dimensional volume-rendered computed tomography angiography image of long left anterior descending artery that has a prepulmonic course anterior to right ventricle outflow tract and enters distal anterior interventricular sulcus

Discussion

Coronary artery anomalies are rare findings found in 0.6%–1.3% of patients undergoing coronary angiography (1, 5). Most of these anomalies are benign situations and do not cause any significant clinical symptoms. However, understanding the

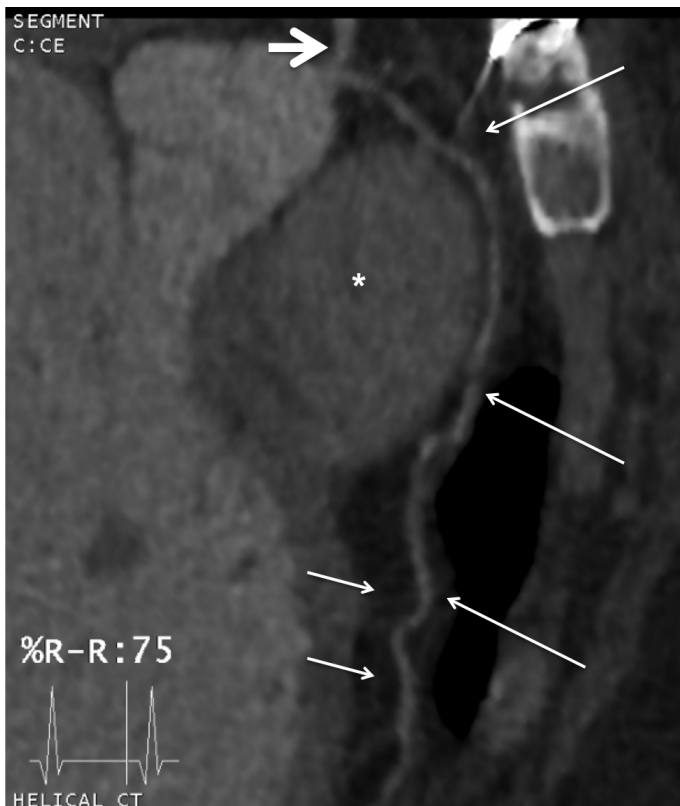


Figure 7. Curved planar reformat image of the patient depicts anomalous origin of long left anterior descending artery (arrow) arising from the right coronary sinus. Left anterior descending artery passes anterior to the pulmonary artery (asterisks) before entering distal anterior interventricular sulcus (short arrow)

anatomy is very important because the clinical outcome and approach to the patient may change completely.

Dual LAD is described as an early bifurcation of proximal LAD consisting of short and long LAD. Spindola-Franco et al. (2) reported the incidence of this anomaly was only 1%. They described four distinct types of dual LAD according to the origin and course of short and long branches (2). Type IV dual LAD is a very rare coronary anomaly reported in 0.04%–0.15% of patients undergoing coronary or CT angiography (6, 7). In type IV LAD, the short LAD originates from LMCA and terminates proximally in AIVS giving off diagonal and septal branches, and the long LAD originates from right sinus Valsalva passing through the anterior of infundibulum of the right ventricle and terminates in distal AIVS (2). Early termination of the short LAD in AIVS and a different ostial or a very close to RCA ostial origination of the long LAD may result in a total occlusion impression and lead to misdiagnosis and treatment, as in our case.

Conclusion

We reported a completely misdiagnosed case because of a rare coronary anomaly. To avoid such misdiagnosis and treatment, we should focus on coronary anatomy and avascular ar-

teries, be careful with the anomalies, and confirm diagnosis with 3D imaging, if necessary.

Informed consent: An informed consent was obtained from the patient.

Conflict of interest: We wish to confirm that there are no known conflicts of interest associated with this publication and there has been no significant financial support for this work that could have influenced its outcome.

Video 1. Left anterior oblique and caudal views showing short left anterior descending artery.

Video 2. Right anterior oblique and caudal view of short left anterior descending artery and left internal mammary artery anastomosis.

Video 3. Left anterior oblique view of right coronary artery with deep engagement of the catheter.

Video 4. Left internal mammary artery graft to left anterior descending artery is harvested.

Video 5. Left anterior oblique view of right coronary artery and long left anterior descending artery originated from right coronary sinus.

References

1. Yamanaka O, Hobbs RE. Coronary artery anomalies in 126,595 patients undergoing coronary arteriography. *Cathet Cardiovasc Diagn* 1990; 21: 28-40. [CrossRef]
2. Spindola-Franco H, Grose R, Solomon N. Dual left anterior descending coronary artery: angiographic description of important variants and surgical implications. *Am Heart J* 1983; 105: 445-55. [CrossRef]
3. Deora S, Kumar T, Shah SC, Patel T. Reporting a novel variant of type VI dual left anterior descending artery: a rare coronary anomaly. *BMJ Case Rep* 2015; 2015. pii: bcr2015211128.
4. Nawale J, Chavan R, Shah M, Nalawade D, Borikar N, Chaurasia A. Percutaneous coronary intervention in a rare case of Type V dual LAD. *J Cardiol Cases* 2018; 18: 153-5. [CrossRef]
5. Kimbiris D, Iskandrian AS, Segal BL, Bemis CE. Anomalous aortic origin of coronary arteries. *Circulation* 1978; 58: 606-15. [CrossRef]
6. Aydinlar A, Çiçek D, Sentürk T, Gemici K, Serdar OA, Kazazoglu AR, et al. Primary congenital anomalies of the coronary arteries: a coronary arteriographic study in Western Turkey. *Int Heart J* 2005; 46: 97-103. [CrossRef]
7. Agarwal PP, Kazerooni EA. Dual left anterior descending coronary artery: CT findings. *AJR Am J Roentgenol* 2008; 191: 1698-701.

Address for Correspondence: Dr. İsmail Gürbak,
İstanbul Mehmet Akif Ersoy Göğüs,
Kalp ve Damar Cerrahi Eğitim ve Araştırma Hastanesi,
Kardiyoloji Kliniği,
Başakşehir Mah. Anafartalar Cad.
1K No:24 Başakşehir, 34306
İstanbul-Türkiye

Phone: +90 533 438 87 27

E-mail: ismailgurbak@gmail.com

©Copyright 2019 by Turkish Society of Cardiology - Available online at www.anatoljcardiol.com

DOI:10.14744/AnatolJCardiol.2019.72772

