

Lightning-induced lethal myocardial infarction and ventricular tachycardia in a boy

Bir erkek çocukta yıldırımla ilişkili ölümcül miyokart infarktüsü ve ventriküler taşikardi

Mücahit Emet, Enbiya Aksakal, Şahin Aslan, Mehmet Karacan**, Gökhan Ersunan*

From Departments of Emergency Medicine, *Cardiology and **Pediatric Cardiology, Faculty of Medicine, Atatürk University, Erzurum, Turkey

Introduction

Lightning injury is one of the most frequent injuries by natural phenomenon. It may involve all organ systems; short-term mortality generally depends on its cardiac affects. We present an 8-year-old boy with myocardial infarction (MI) and late ventricular tachycardia secondary to indirect lightning strike.

Case Report

An 8-year-old boy was injured by side splash of a lightning that struck a tree. He was found unconscious, but his pulse-beat and respiration were obvious. Neither cardiopulmonary resuscitation, nor defibrillation was needed during transportation from a nearby emergency room where he was intubated. When he admitted to our ED, his Glasgow Coma Scale was 3; and initial vital signs were in the reference range. Second-degree burns found scattered on his chest and over left inguinal area. Deep tendon reflexes were absent and plantar responses were silent. Physical examination revealed normal cardiac and abdominal examination and there were no other signs of trauma.

An electrocardiogram (ECG) showed sinus tachycardia and ST elevation in leads DII, DIII, aVF, V₃ and V₄, and negative T wave in leads DII, DIII and aVF (Fig. 1a). Initial laboratory findings demonstrated a considerable elevation in cardiac enzymes, especially in troponin-I: 9.14 ng/mL (reference range, 0.1-0.8). The echocardiography was normal except mild tricuspid insufficiency. Serum lactate dehydrogenase, amylase and standard liver panel tests were also mildly elevated. Hemogram revealed leucocytosis (27670/μL). Serum electrolytes and arterial blood gas values were normal. Computed tomographic images of the head revealed brain edema.

The patient was transferred to the intensive care unit of anesthesia and "synchronized intermittent mandatory ventilation with pressure support" was given. In the 4th hour of his arrival, ECG showed sustained ventricular tachycardia with pulse that responded to medical therapy (Fig. 1b). As amiodarone is hepatotoxic and propafenone was unavailable, lidocain was administered. Other therapies included IV hydration, low

molecular weight heparin, mannitol, and sedation with sodium thiopental. On the second day of hospitalization, bradycardia occurred leading to hemodynamic instability and he died at the 24th hour of admission.

Discussion

Worldwide mortality of lightning is estimated to be 0.2-1.7 deaths/million people (1). The primary cause of death is asystole or ventricular fibrillation, which occurs as a result of depolarized entire myocardium due to massive direct current shock (1, 2). For cases in which cardiac automaticity restore organized cardiac activity and spontaneous circulation return, respiratory arrest due to paralysis of respiratory center play a critical factor in mortality (3). In our case when medical team had arrived, the patient was found with both spontaneous circulation and respiration. Thus, we do not think that the reason of myocardial injury was related to dysfunction of these systems, but the current possibly caused these injuries.

The exact mechanism of the cardiac damage seen in lightning strike is still unknown. Suggested hypothesis include direct thermal injury, the induction of coronary artery spasm, catecholamine discharge or autonomic stimulation through an unknown mechanism, arterial thrombosis and circulatory disturbance in cardiac microvessels (1, 2). We do not know the exact location and reason of the damage, as autopsy was not performed in our case.

Lightning victims may present with sinus tachycardia, transient ST-segment elevation or depression, QT prolongation, premature ventricular contractions, atrial fibrillation, or bundle-branch block (1, 3, 4). Our patient's initial ECG showed sinus tachycardia with ST-segment elevation in leads DII, DIII, aVF, V₃ and V₄ (Fig. 1). Previous studies also demonstrated that ST-segment and T-wave changes generally occur on the inferior and anterior aspect of the heart (Table 1). The reason of this is not clear yet. We think that these aspects of the heart are more prone to the affects of current of lightning. Previous reports also suggest that lightning strike do not give harm to coronary arteries, but may injure directly myocardial cells (1, 5). In our case, we observed a late and benign ventricular dysrhythmia, which possibly was not mentioned in similar reports before.

Address for Correspondence/Yazışma Adresi: Dr. Mücahit Emet, Acil Tıp Anabilim Dalı, Atatürk Üniversitesi Tıp Fakültesi, Erzurum, Türkiye
Phone: +90 442 316 63 33-1037 Fax: +90 442 316 63 40 E-mail: mucahitemet@gmail.com

© Telif Hakkı 2010 AVES Yayıncılık Ltd. Şti. - Makale metnine www.anakarder.com web sayfasından ulaşılabilir.

© Copyright 2010 by AVES Yayıncılık Ltd. - Available on-line at www.anakarder.com

doi:10.5152/akd.2010.122

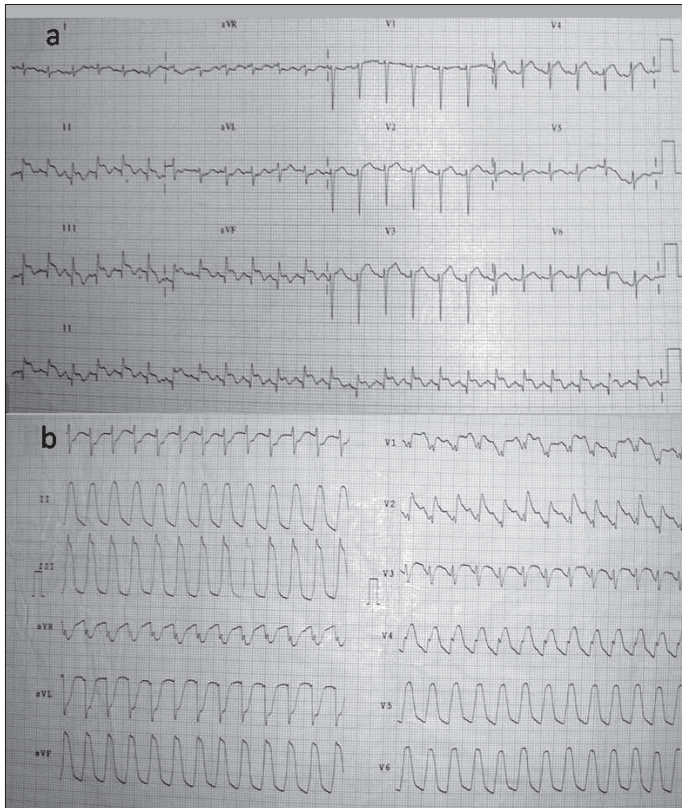


Figure 1. a) Sinus tachycardia and ST elevation in leads DII, DIII, aVF, V3, V4 and negative T wave in leads DII, DIII, aVF; b) Ventricular tachycardia that occurred four hours after arrival

It is more reasonable to ascribe this arrhythmia to myocardial injury and infarction rather than aforementioned mechanisms.

Conclusion

Lightning strike may lead to MI especially in the inferior and/or anterior aspects of the heart although the patient is in childhood and has been thought to have relatively normal vessels compared to adults. Later-onset arrhythmias like ventricular tachycardia may occur.

References

1. Sağlam H, Yavuz Y, Yürümez Y, Özkeçeci G, Kilit C. A case of acute myocardial infarction due to indirect lightning strike. *J Electrocardiol* 2007; 40: 527-30.
2. Ritenour AE, Morton MJ, McManus JG, Barillo DJ, Cancio LC. Lightning injury: a review. *Burns* 2008; 34: 585-94.
3. Alyan O, Özdemir O, Tüfekçioğlu O, Geyik B, Aras D, Demirkan D. Myocardial injury due to lightning strike-a case report. *Angiology* 2006; 57: 219-23.
4. O'Keefe Gatewood M, Zane RD. Lightning injuries. *Emerg Med Clin North Am* 2004; 22: 369-403.
5. Zack F, Hammer U, Klett I, Wegener R. Myocardial injury due to lightning. *Int J Legal Med* 1997; 110: 326-8.
6. Rivera J, Romero KA, González-Chon O, Uruchurtu E, Márquez MF, Guevara M. Severe stunned myocardium after lightning strike. *Crit Care Med* 2007; 35: 280-5.
7. Eber B, Himmel G, Schubert B, Zeuschner J, Dusleag J, Seerainer C, et al. Myocardial damage following lightning injury. *Z Kardiol* 1989; 78: 402-4.
8. Sinha AK. Lightning-induced myocardial injury. A case report with management. *Angiology* 1985; 36: 327-31.
9. Jackson SH, Parry DJ. Lightning and the heart. *Br Heart J* 1980; 43: 454-7.

Table 1. Case reports of lightning strike induced cardiac damage

Reference	Case	Initial ECG	Imaging studies
Sağlam et al. ¹ , 2007	13, M	ST elevation in leads DII, DIII, aVF and V5-V6 and ST depression in leads aVL and V1-V4	No abnormality in the coronary vessels in coronary angiography
Rivera et al. ⁶ , 2007	42, F	ST elevation in V2-V6 and II, III and aVF	Global left ventricle (LV) dysfunction and severe diastolic dysfunction in transthoracic echocardiography
Alyan et al. ³ , 2006	38, M	T-wave inversions in leads D II, III, aVF and V4-6	Wall motion abnormality in the left ventricle in transthoracic echocardiography
Zack et al. ⁵ , 1997	27, M	Transitory right bundle-branch block, T wave insertion, discrete ST segment elevation	Macroscopically examination of the heart showed disseminated focal thermally damaged regions besides hemorrhagic areas in the myocardium of both atria and both ventricles. The coronary arteries appeared normal and exhibited no signs of thrombosis. Histological examination revealed a mixture of necroses and contraction bands.
Eber et al. ⁷ , 1989	27, M	ST elevation in leads DII, DIII, aVF and V5-V6	Transient pericardial effusion was observed by echocardiography. Myocardial scintigraphy showed perfusion defects.
Sinha et al. ⁸ , 1985	20, M	T wave inversion in leads II, III, aVF, V3, V4. ST-segment elevation in V3-V4.	----
Jackson et al. ⁹ , 1980	41, M	ST elevation in leads DII, DIII, aVF and V4-V6	Normal perfusion in myocardial scintigraphy

ECG – electrocardiogram, F – female, M – male