

Cardiac resynchronization therapy: implantation tips and tricks

Can Hasdemir

Department of Cardiology, Medical Faculty, Ege University, Izmir, Turkey

ABSTRACT

Cardiac resynchronization therapy has been shown to improve quality of life and mortality in selected, subgroup of systolic heart failure patients with left ventricular (LV) dyssynchrony. However, LV lead implantation can be difficult or ultimately unsuccessful in 10 to 15% of patients. The reasons for difficult LV lead implantations are coronary venous system related issues (failure to access coronary venous system and anatomic variations in the coronary veins), extensive scar tissue in the target region for LV pacing, phrenic nerve stimulation, and LV lead instability. The aim of this review is to address the potential causes of difficult LV lead implantations and summarize the solutions for these challenging implantations with the advent of new technologies, better tools, and improved techniques. (*Anadolu Kardiyol Derg 2007; 7 Suppl 1; 53-6*)

Key words: heart failure, cardiac resynchronization therapy, pacemakers

Introduction

Cardiac resynchronization therapy (CRT) has been shown to improve morbidity and mortality in selected, subgroup of heart failure patients with left ventricular (LV) dyssynchrony (1-4). A successful implant typically involves placement of the LV lead in a posterolateral or anterolateral coronary vein with good lead stability, adequate thresholds without phrenic nerve stimulation. However, many LV lead implants remain difficult and technically challenging despite the newer lead and lead delivery systems. Up to 10-15% of attempts to place LV leads are ultimately unsuccessful (5-7).

The aim of this review is to address the potential causes of difficult LV lead implantations and summarize the solutions for these challenging implantations with the advent of new technologies, better tools, and improved techniques.

Potential causes of difficult LV lead implantations and solutions

Causes of difficult LV lead implantations are summarized in Table 1.

Failure to access coronary venous system

Inability to obtain coronary venous system access is one of the most common causes of implant failure (up to 4%) (5-8). Implant failures are more often due to markedly enlarged right atrium along with severe tricuspid regurgitation and the accompanying distortion of the coronary sinus (CS) ostium leading to inability to cannulate the ostium or insufficient support by the guiding catheter. Cannulation of the CS has become easier with improved technology. Sheaths have been developed to take advantage of the existing anatomy (7, 9). Outer sheaths with a large primary curve and a smaller secondary curve allow support from the lateral atrial wall and superior vena cava. The primary

curve allows the guide to extend over the Eustachian ridge and the secondary curve allows the guide to engage the ostium of CS above the Thebesian valve. The preferred technique of CS cannulation is to advance the sheath into the right ventricle and withdraw it with counterclockwise rotation. A standard 0.035-mm diameter wire, inner catheter, and contrast dye may be used to assist in this process. Contrast dye injections improve the visualization of the anatomy in difficult cases. It may reveal unusually high ostia, an overriding Thebesian valve, an early bifurcation, or separate ostium of the middle cardiac vein. A deflectable mapping catheter can be used inside the guiding catheter to facilitate CS cannulation. Fluoroscopy alone may be helpful. The "fat stripe" (fatty tissue around the CS ostium) serves as a marker for the location of the CS ostium. Like peripheral veins, the coronary venous system may contain valves (Fig. 1). The Thebesian valve and Vieussens valve (particularly triple leaflet, concave type) have been reported to cover more than 75% of the CS ostium in 12% and more than 75% of the proximal end of the CS in 2% of cases, respectively (10-12).

Anatomic variations in the coronary venous system

Once the CS has been cannulated, balloon occlusive venography is performed to identify the existing anatomy and possible target vessels. The venogram should be performed in left anterior oblique (LAO) and right anterior oblique (RAO) projections in order to obtain better visualization of the coronary venous system. Coronary venous system has been traditionally visualized by balloon occlusive CS venography. In case of failure of this method, other imaging modalities can be used such as venous-phase coronary angiography, multislice computed tomography (CT)-guided imaging, fiberoptic endoscopy, and intracardiac echocardiography (13-16). The data, regarding the exact role of these imaging modalities before and during CRT implantations is lacking.

If the index vessel is at least of moderate size and does not appear to have a difficult anatomy, the operator may elect to proceed with the lead and an inner 0.015-mm diameter guidewire. The wire is advanced into the vessel, and the lead is advanced over the wire. If the initial segment of the target vessel appears challenging (sharply-angulated/tortuous), then an appropriately shaped inner sheath may be used to deliver the wire or the wire and the lead. Very difficult branches may require inner catheters that are capable of lead delivery. These catheters are shaped so that they are supported from the opposite wall of the CS body, which allows appropriate forward pressure to be applied to the lead. These catheters are available in various shapes that conform to differing anatomies (7, 9). These sheaths may also straighten out tortuous segments for delivery. Care must be taken to choose the correct angled inner guiding catheter. Of note, too much pressure applied to the inner sheaths while placing it to the ostium of the index vessel can result in coronary venous dissection. When inner catheters that can subselect a sharply-angulated vein and allow direct insertion of an LV lead are developed, they can be used for support. This is not yet commercially available from any manufacturer (7).

Table 1. Reasons for difficult CRT implantation

Coronary Venous System Related Problems:

- 1-Failure to access coronary venous system:
 - Markedly enlarged right atrium and severe TR
 - Tortuous, angulated, vertically positioned CS os
 - Prominent Thebesian valve
 - Prominent Vieussens valve
 - Small-sized CS
- 2-Anatomic variations in the coronary venous system:
 - Lack of suitable venous branch:
 - Early takeoff of left ventricular branches
 - Too large or too small veins
 - Sharply-angulated/tortuous venous branches
 - Venous branches with narrowing
 - Venous branches with valves

Scar burden

Phrenic nerve stimulation

Lack of adequate capture threshold

Left ventricular lead instability

CRT- cardiac resynchronization therapy, CS- coronary sinus, TR- tricuspid regurgitation

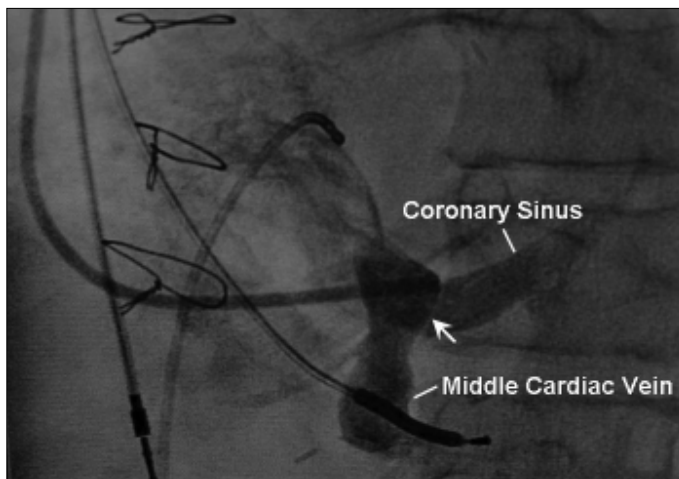


Figure 1. Unsuccessful left ventricular lead implantation via the coronary venous system secondary to dynamic obstruction to coronary sinus access due to a prominent Thebesian valve (arrow)

After the lead is advanced, the site is tested for capture thresholds and presence or absence of phrenic nerve stimulation. The choice of lead depends on the anatomy of the branch. If the branch is large, a larger diameter lead is chosen. If the branch is very large and possible dislodgement is a concern, a lead with a curled or sigmoid shape may be chosen. If the site is acceptable, then the sheath is removed, usually by mechanical splitting. Sheaths may have an inner wire braiding. This type of construction requires that a razor-bladed splitting device be used to cut the braids. This process may dislodge the lead. Splitting of the sheath should be performed under fluoroscopic guidance to ensure that the lead is not rotated or retracted during the process.

There are several other techniques for placement of the LV lead inside the sharply-angulated/tortuous coronary veins. First is to advance the guidewire as far out inside the vein as possible, sometimes even coming back into the CS via anastomoses. This allows extra support when pushing the lead through the acute angle. One technique that gives even more support is to pull the guidewire back as you advance the lead. Second, is to use the other veins, which have extensive collaterals with the initial vein and terminating in the target area (posterolateral region of the LV) (Fig. 2). Third, is to use pulmonary artery balloon catheter in the CS just distal to the sharply-angulated vein. This provides support to advance the 0.014-mm diameter guidewire inside the vein without the wire prolapsing back into the CS (17). Fourth, is to use double-wire technique in which two wires (one softer and one stiffer) are placed in the sharply-angulated vein that opens the vein, reducing tortuosity and providing better support. The second-support wire is a stiffer and heavier wire (0.018-mm diameter or larger). This allows tracking of the lead over the first wire (18).

Occasionally, techniques such as venoplasty (angioplasty and/or stenting) are required for significant narrowing of the target branch or for stabilization of the LV lead (19-21). Retained guidewire technique has also been used for anchoring leads after experiencing multiple dislodgements (22). A major concern with these last two techniques is that the LV lead will not be accessible if lead extraction is necessary in the future (6, 23).

A novel magnetic navigation system has been used for LV lead implants. This technology is useful in traversing a wire across very tortuous segments. This procedure is limited to the technology of the current sheaths, leads, and wires. Magnet-tipped sheaths and delivery systems are being developed for future use (24).

Scar burden

Lack of adequate capture threshold and failure of response to CRT (in the presence of LV dyssynchrony) may be related to the presence of extensive scar tissue in the target region for LV pacing. Therefore, in patients with ischemic cardiomyopathy and history of previous infarction, assessment of scar tissue should be considered before CRT implantation (25).

Phrenic nerve stimulation

The left phrenic nerve, which is responsible for diaphragmatic stimulation, runs along the posterior and lateral border of the heart. Pacing near this nerve may result in diaphragmatic stimulation at the programmed pacing rate, which is very uncomfortable for the patient and not tolerated for long periods of time. Testing with highest voltage and pulse width for capture threshold and use of bipolar leads and leads with programmable pacing configurations may diminish this possible complication (Fig. 3) (7, 9).

Determination of optimal position of left ventricular lead

Current practice involves placement of the LV lead in the most posterior and lateral position as possible on the basis of LAO and RAO projections. Besides anatomic landmarks, several other methods have been recommended for optimal lead positioning such as the timing of the LV electrogram in relation to the QRS complex, and determination of the latest activation site by using

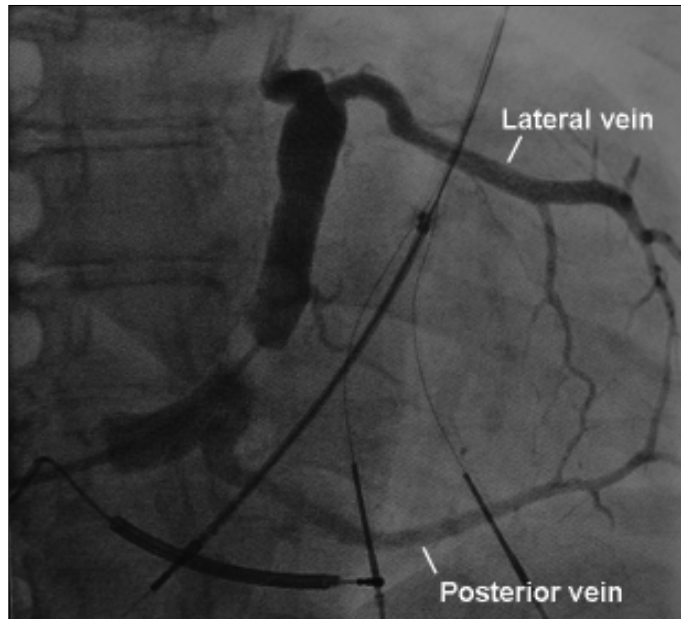


Figure 2. Balloon occlusive venography demonstrates a large-sized posterior vein and a lateral vein. The posterior vein can be used for the left ventricular lead implantation in case of unsuccessful left ventricular lead implantation through the lateral vein or vice versa

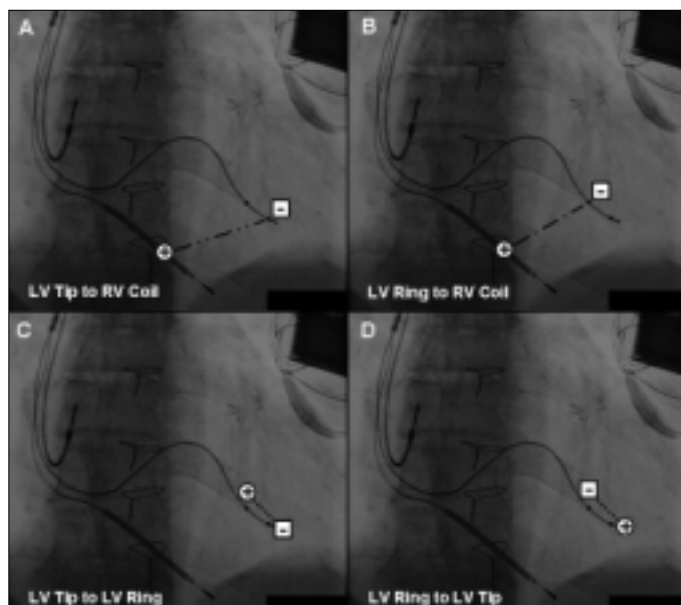


Figure 3. High capture thresholds and phrenic nerve stimulations can be avoided by using bipolar leads and leads with programmable pacing configurations (A-D). Pacing configurations can be either extended bipolar pacing vector (A and B) or dedicated bipolar pacing vector (C and D).

LV- left ventricle, RV- right ventricle

conventional electroanatomic mapping systems and CT imaging (26-28). Other technologies to help refine optimal lead positioning, include vector velocity imaging in conjunction with intracardiac echocardiography (29).

Alternative routes to left ventricular pacing

In some cases, alternative routes of LV pacing are needed due to constraints of coronary venous anatomy, diaphragmatic stimulation, and late LV lead dislodgements. These include minimally invasive surgical alternatives (minithoracotomy, video-assisted thoracoscopic surgery, and robotically assisted placement of LV leads), minimally invasive subxiphoid epicardial approach, transeptal endocardial left ventricular lead implantation, and bifocal right ventricular pacing (9, 30-35). Bifocal right ventricular pacing consists of implantation of two right ventricular leads: one placed septally at the apex, and the other in the high septal outflow tract.

Right ventricular apical versus septal pacing

To date, a paucity of data exists about the role of right ventricular outflow tract pacing as opposed to apical pacing during CRT. Further studies are required to compare the acute and chronic effects of apical versus septal pacing during CRT and to evaluate the hemodynamic effects of both pacing sites by the current imaging modalities.

References

1. Cazeau S, Leclercq C, Lavergne T, Walker S, Varma C, Linde C, et al. Multisite Stimulation in Cardiomyopathies (MUSTIC) Study Investigators. Effects of multisite biventricular pacing in patients with heart failure and intraventricular conduction delay. *N Engl J Med* 2001; 344: 873-80.
2. Abraham WT, Fisher WG, Smith AL, Delurgio DB, Leon AR, Loh E, et al. MIRACLE Study Group. Multicenter InSync Randomized Clinical Evaluation. Cardiac resynchronization in chronic heart failure. *N Engl J Med* 2002; 346: 1845-53.
3. Bristow MR, Saxon LA, Boehmer J, Krueger S, Kass DA, De Marco T, et al. Comparison of Medical Therapy, Pacing, and Defibrillation in Heart Failure (COMPANION) Investigators. Cardiac-resynchronization therapy with or without an implantable defibrillator in advanced chronic heart failure. *N Engl J Med* 2004; 350: 2140-50.
4. Cleland JG, Daubert JC, Erdmann E, Freemantle N, Gras D, Kappenberger L, et al. Cardiac Resynchronization-Heart Failure (CARE-HF) Study Investigators. The effect of cardiac resynchronization on morbidity and mortality in heart failure. *N Engl J Med* 2005; 352: 1539-49.
5. Bax JJ, Abraham T, Barold SS, Breithardt OA, Fung JW, Garrigue S, et al. Cardiac resynchronization therapy: Part 2-issues during and after device implantation and unresolved questions. *J Am Coll Cardiol* 2005; 46: 2168-82.
6. Shepard RK, Ellenbogen KA. Challenges and solutions for difficult implantations of CRT devices: the role of new technology and techniques. *J Cardiovasc Electrophysiol* 2007; 18: 21-5.
7. Burkhardt JD, Wilkoff BL. Interventional electrophysiology and cardiac resynchronization therapy: delivering electrical therapies for heart failure. *Circulation* 2007; 115: 2208-20.
8. Meisel E, Pfeiffer D, Engelmann L, Tebbenjohanns J, Schubert B, Hahn S, et al. Investigation of coronary venous anatomy by retrograde venography in patients with malignant ventricular tachycardia. *Circulation* 2001; 104: 442-7.
9. Leon AR. New tools for the effective delivery of cardiac resynchronization therapy. *J Cardiovasc Electrophysiol* 2005; 16: 42-7.

10. Gerber TC, Sheedy PF, Bell MR, Hayes DL, Rumberger JA, Behrenbeck T, et al. Evaluation of the coronary venous system using electron beam computed tomography. *Int J Cardiovasc Imaging* 2001; 17: 65-75.
11. Zawadzki M, Pietrasik A, Pietrasik K, Marchel M, Ciszek B. Endoscopic study of the morphology of Vieussens valve. *Clin Anat* 2004; 17: 318-21.
12. Shinbane JS, Girskey MJ, Mao S, Budoff MJ. Thebesian valve imaging with electron beam CT angiography: implications for resynchronization therapy. *Pacing Clin Electrophysiol* 2004; 27: 1566-7.
13. Vaseghi M, Cesario DA, Ji S, Shannon KM, Wiener I, Boyle NG, et al. Beyond coronary sinus angiography: the value of coronary arteriography and identification of the pericardiophrenic vein during left ventricular lead placement. *Pacing Clin Electrophysiol* 2005; 28: 185-90.
14. Jongbloed MR, Lamb HJ, Bax JJ, Schuijf JD, de Roos A, van der Wall EE, et al. Noninvasive visualization of the cardiac venous system using multislice computed tomography. *J Am Coll Cardiol* 2005; 45: 749-53.
15. Anh DJ, Chen HA, Eversull CS, Mourlas NJ, Mead RH, Liem LB, et al. Early human experience with use of a deflectable fiberoptic endocardial visualization catheter to facilitate coronary sinus cannulation. *Heart Rhythm* 2006; 3: 875-8.
16. Shalaby AA. Utilization of intracardiac echocardiography to access the coronary sinus for left ventricular lead placement. *Pacing Clin Electrophysiol* 2005; 28: 493-7.
17. Meade TH, Lopez JA. Balloon occlusion technique to cannulate angulated and tortuous coronary sinus branches in cardiac resynchronization therapy. *Pacing Clin Electrophysiol* 2005; 28: 1243-4.
18. Chierchia GB, Geelen P, Rivero-Ayerza M, Brugada P. Double wire technique to catheterize sharply angulated coronary sinus branches in cardiac resynchronization therapy. *Pacing Clin Electrophysiol* 2005; 28: 168-70.
19. Hansky B, Lamp B, Minami K, Heintze J, Krater L, Horstkotte D, et al. Coronary vein balloon angioplasty for left ventricular pacemaker lead implantation. *J Am Coll Cardiol* 2002; 40: 2144-9.
20. Cesario DA, Shenoda M, Brar R, Shivkumar K. Left ventricular lead stabilization utilizing a coronary stent. *Pacing Clin Electrophysiol* 2006; 29: 427-8.
21. Szilagyi S, Merkely B, Roka A, Zima E, Fulop G, Kutyifa V, et al. Stabilization of the coronary sinus electrode position with coronary stent implantation to prevent and treat dislocation. *J Cardiovasc Electrophysiol* 2007; 18: 303-7.
22. De Cock CC, Jessurun ER, Allaart CA, Visser CA. Repetitive intraoperative dislocation during transvenous left ventricular lead implantation: usefulness of the retained guidewire technique. *Pacing Clin Electrophysiol* 2004; 27: 1589-93.
23. Ermis C, Benditt DG. Stent-stabilization of left ventricular pacing leads for cardiac resynchronization therapy: a promising concept? *J Cardiovasc Electrophysiol* 2007; 18: 308-9.
24. Rivero-Ayerza M, Thornton AS, Theuns DA, Scholten MF, Mekel JM, Res J, et al. Left ventricular lead placement within a coronary sinus side branch using remote magnetic navigation of a guidewire: a feasibility study. *J Cardiovasc Electrophysiol* 2006; 17: 128-33.
25. Bleeker GB, Schaliij MJ, Van Der Wall EE, Bax JJ. Postero-lateral scar tissue resulting in non-response to cardiac resynchronization therapy. *J Cardiovasc Electrophysiol* 2006; 17: 899-901.
26. Singh JP, Fan D, Heist EK, Alabiad CR, Taub C, Reddy V, et al. Left ventricular lead electrical delay predicts response to cardiac resynchronization therapy. *Heart Rhythm* 2006; 3: 1285-92.
27. Auricchio A, Fantoni C, Regoli F, Carbucicchio C, Goette A, Geller C, et al. Characterization of left ventricular activation in patients with heart failure and left bundle-branch block. *Circulation* 2004; 109: 1133-9.
28. Murphy RT, Sigurdsson G, Mulamalla S, Agler D, Popovic ZB, Starling RC, et al. Tissue synchronization imaging and optimal left ventricular pacing site in cardiac resynchronization therapy. *Am J Cardiol* 2006; 97: 1615-21.
29. Vannan MA, Pedrizzetti G, Li P, Gurudevan S, Houle H, Main J, et al. Effect of cardiac resynchronization therapy on longitudinal and circumferential left ventricular mechanics by velocity vector imaging: description and initial clinical application of a novel method using high-frame rate B-mode echocardiographic images. *Echocardiography* 2005; 22: 826-30.
30. Navia JL, Atik FA, Grimm RA, Garcia M, Vega PR, Myhre U, et al. Minimally invasive left ventricular epicardial lead placement: surgical techniques for heart failure resynchronization therapy. *Ann Thorac Surg* 2005; 79: 1536-44.
31. Zenati MA, Bonanomi G, Chin AK, Schwartzman D. Left heart pacing lead implantation using subxiphoid videopericardioscopy. *J Cardiovasc Electrophysiol* 2003; 14: 949-53.
32. Ji S, Cesario DA, Swerdlow CD, Shivkumar K. Left ventricular endocardial lead placement using a modified transseptal approach. *J Cardiovasc Electrophysiol* 2004; 15: 234-6.
33. van Gelder BM, Scheffer MG, Meijer A, Bracke FA. Transseptal endocardial left ventricular pacing: an alternative technique for coronary sinus lead placement in cardiac resynchronization therapy. *Heart Rhythm* 2007; 4: 454-60.
34. O'Donnell D, Nadurata V, Hamer A, Kertes P, Mohammed W. Bifocal right ventricular cardiac resynchronization therapies in patients with unsuccessful percutaneous lateral left ventricular venous access. *Pacing Clin Electrophysiol* 2005; 28: 27-30.
35. Vlay SC, Kort S. Biventricular pacing using dual-site right ventricular stimulation: is it placebo effect? *Pacing Clin Electrophysiol* 2006; 29: 779-83.