

Supraventricular tachycardia induced by treadmill test

Koşu bandı testine bağlı supraventriküler taşikardi

A 29-year-old male presented with longstanding exercise related palpitations. Transthoracic echocardiogram was normal. An event recorder showed no symptom-rhythm correlation. During the treadmill test (stage 4 Bruce protocol) the patient had developed sinus tachycardia at 185 bpm (Fig. 1a) followed by a single premature atrial contraction with long PR interval (white arrow, Fig. 1b) initiating a supraventricular tachycardia at 250 bpm lasting 3 minutes (Fig. 1c). This tachycardia terminated abruptly (black arrow, Fig. 1d). The tachycardia was characterized by a retrograde and negative P-wave in the inferior leads. An RP < PR relationship is observed. The RP is < than 80 ms. All these features are suggestive of an atrioventricular nodal reentrant tachycardia. Treadmill testing is a useful tool for induction and diagnosis of supraventricular tachycardias facilitating medical decision-making. Nowadays, the development of invasive testing has replaced some of the non-invasive tools that we used in the past for the diagnosis of supraventricular arrhythmias; however, its value should be recognized and highlighted. This patient underwent successful radiofrequency ablation of the slow pathway.

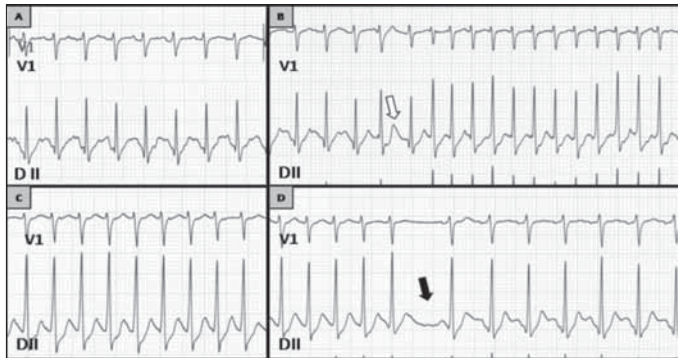


Figure 1. a) Stage 3 of the Bruce protocol. Sinus tachycardia at 185 bpm. b) Stage 4 of the Bruce protocol. Sinus tachycardia followed by a single premature atrial beat (white arrow) which conducts with a long PR interval signifying antegrade conduction over a slow pathway, initiating a sustained supraventricular tachycardia. c) Narrow complex tachycardia at 250 bpm. Note RP < PR with an RP < 80 ms. Highly likely a typical atrioventricular nodal reentry tachycardia (AVNRT). d) Sudden termination of AVNRT (black arrow) followed by a pause and restoration of sinus tachycardia

Rodrigo Miranda, Juan Cruz Lopez Diez, Kevin Michael, Adrian Baranchuk
 Department of Cardiology, Kingston General Hospital, Queen's University, Kingston, Canada

Address for Correspondence/Yazışma Adresi: Dr. Adrian Baranchuk, Physiology Cardiac Electrophysiology and Pacing Kingston General Hospital K7L 2V7 Queen's University, Kingston, Canada
 Phone: +1 613 549 66 66 Fax: +1 613 548 13 87 E-mail: barancha@kgh.kari.net
Available Online Date / Çevrimiçi Yayın Tarihi: 11.01.2011

©Telif Hakkı 2011 AVES Yayıncılık Ltd. Şti. - Makale metnine www.anakarder.com web sayfasından ulaşılabilir.
 ©Copyright 2011 by AVES Yayıncılık Ltd. - Available on-line at www.anakarder.com
 doi:10.5152/akd.2011.019

Massive bilateral atriomegaly filling thoracic cavity

Torasik kaviteyi dolduran masif bilateral atriomegali

A 60-year-old woman was admitted to our hospital with symptoms including shortness of breath and leg swelling. She had a history of rheumatic heart disease and had undergone valve replacement for severe mitral stenosis in 1977. She had a re-operation in 1999 with insertion of a mechanical prosthesis. On her physical examination, heart sounds were accentuated due to mechanical valve. Systolic murmur was present on 4th intercostal space at the left sternal border. Ascitis and leg edema were present. Atrial fibrillation was noted on electrocardiogram. A normal functioning mechanical prosthetic valve on mitral position was noted on echocardiography. Right ventricle and both atrias were enlarged. Severe tricuspid regurgitation was present. Mal-coaptation of the tricuspid valve leaflets was noted. Postero-anterior chest radiography revealed gross cardiomegaly and compressive atelectasis in the right lung (Fig. 1). Right heart border was obscured. Striking left and right atrial enlargement were seen on computed tomography images (Fig. 2). Right ventricular dilatation and mitral valve prosthesis were also present. Thoracic cavity was filled with huge biatrial and right ventricular enlargement (Fig. 3). Atrial thrombi and pulmonary thromboemboli were not observed.

Mitral valve disease is a frequent complication of rheumatic heart disease. Myocardial damage develops in left atrium after rheumatic disease. Mitral stenosis and myocardial tonus impairment lead to increased intraatrial pressure. Left atrial volume overload and dysfunction rarely can cause huge atrial dilatation. Massive atrial dilatation may cause dyspnea as a result of compression on trachea and bronchi. Cardiac complications, such as atrial fibrillation, are frequent.

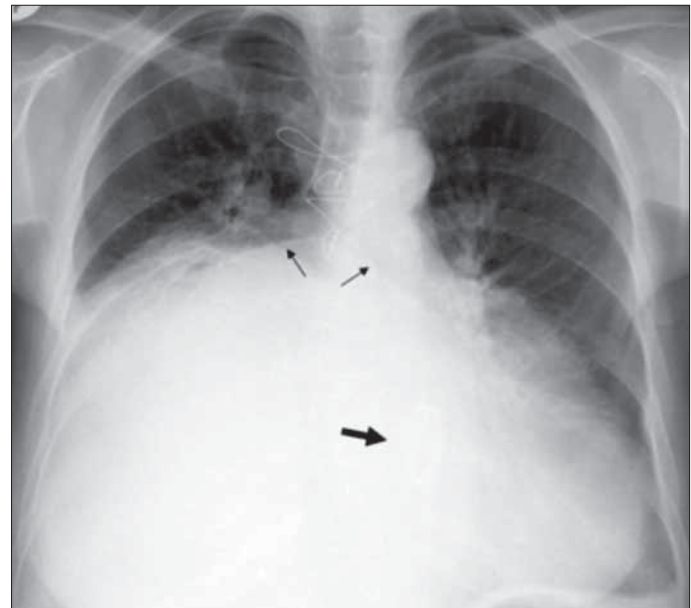


Figure 1. Postero-anterior chest radiography demonstrates gross cardiomegaly with right middle and lower lobe atelectasis. Subcarinal angle widened due to huge left atrial enlargement (small arrows). Mitral prosthesis valve (thick arrow) and postoperative changes are also seen