

Anatomic characteristics of left atrium and openings of pulmonary veins

Z. Aslı Aktan İkiz, Hülya Üçerler, Tomris Özgür

Department of Anatomy, Faculty of Medicine, Ege University, İzmir-Turkey

ABSTRACT

Objective: Left atrium (LA) and left atrial pulmonary venous anatomy have clinical importance for atrial fibrillation (AF) and cardiac tumor surgery. A detailed anatomic knowledge of these structures may facilitate clinical evaluations. The aim of this study was to assess LA size and to demonstrate other anatomic features of LA with pulmonary vein openings in normal population.

Methods: This descriptive laboratory study was performed in 56 hearts of adult formalin fixed cadavers. The number of pulmonary vein openings into LA was recorded. Different patterns of pulmonary vein openings were described such as common ostium and additional vein.

Results: The roof of LA was determined as flat (75%), convex (14.3%) or concave (10.7%) in specimens. A roof pouch was present in 8.9% of specimens. The diameter of LA roof, the anteroposterior LA diameter and the LA diameter between septum and lateral wall were recorded. Thin areas on the atrial wall were observed in front of a light source around left atrial appendage orifice. Septal band was found in 7.1% of specimens. Five different patterns of pulmonary vein openings were recorded: The common arrangement, the unilateral common ostium, the unilateral additional vein, the additional vein on both side and the complex type were observed respectively in 41 specimens (73.2%), 10 specimens (17.9%), three specimens (5.4%), one specimen (1.8%) and one specimen (1.8%).

Conclusion: It is expected that the data from present study will be a guide to the clinicians during the surgical approaches or radiologic examinations of LA and pulmonary vein openings into LA. (*Anadolu Kardiyol Derg 2014; 14: 674-8*)

Key words: anatomy, left atrium, pulmonary veins, septal band, oval fossa

Introduction

Atrial fibrillation (AF) is the most common of cardiac arrhythmias in clinical practice and has clinical importance for cardiovascular risk. Hemodynamic compromise and formation of thromboemboli are its two main complications. It has been reported that ectopic foci responsible for the initiation of AF were in the walls of the superior vena cava, both atria, the crista terminalis, ostium of the coronary sinus, interatrial septum and the muscular sleeves of the distal pulmonary veins. Therefore, the pulmonary veins and posterior atrial wall have become important targets of interventional therapies (1-3). Beside this, left atrium (LA) roof and septum are also important regions to improve the success rate of treating AF patients with catheter ablation (4, 5). An overview of LA and proximal parts of pulmonary veins anatomy can provide useful information for surgical approaches, catheter ablation and radiologic examina-

tions (1, 4-7). The purpose of this paper was also to provide an anatomical review about LA and proximal parts of pulmonary veins.

Methods

Study design

This descriptive laboratory study was performed in 56 hearts of adult formalin fixed cadavers.

Material

Fifty six heart specimens obtained from 10% formalin fixed adult cadavers were examined grossly (mean age 59±11 years). The dissection was approved by a suitably constituted Ethics Committee of the institution within which the work was undertaken and the study conforms to the provisions of the Helsinki Declaration of 1964 and all subsequent revisions.

This study was presented at 'Joint Meeting of Anatomical Societies' in Bursa-Turkey, on 19-22nd May 2011.

Address for Correspondence: Dr. Z. Aslı Aktan İkiz, Ege Üniversitesi Tıp Fakültesi, Anatomi Anabilim Dalı, 35100 Bornova, İzmir-Türkiye Phone: +90 232 390 39 97 Fax: +90 232 390 39 98 E-mail: z.asli.ikiz@gmail.com

Accepted Date: 01.10.2013 **Available Online Date:** 10.02.2014

©Copyright 2014 by Turkish Society of Cardiology - Available online at www.anakarder.com
DOI:10.5152/akd.2014.4968



Anatomic measurements

The LA transverse diameter was obtained by measuring the maximal transverse diameter of LA as described in the study of Su et al. (8). The shape and distance of the roof and the pouch presence was observed as described in the study of Wongcharoen et al. (4). The number of pulmonary vein openings into LA was recorded. Different patterns of pulmonary vein openings were described such as common ostium and additional vein. All measurements were taken with machinists calipers to the nearest 0.1 mm and expressed in millimeters and centimeters.

Statistical analysis

All analyses were performed using the SPSS 15.0 (SPSS Inc., Chicago, Illinois, USA) software package. Results were presented as mean±standard deviation. The morphological appearances of LA roof, the patterns of pulmonary vein openings were presented as the percentage.

The average weight of 56 hearts was 291.2±33.5 g.

Results

The anatomic features of LA roof

The roof of LA was determined as flat in 42 (75%), convex in 8 (14.3%) and concave in 6 (10.7%) of specimens (Fig. 1-3). When we plotted out a line between the opening of right superior pulmonary vein (RSPV) and left superior pulmonary vein (LSPV) and we joined this line to the center of convex roof, the distance of this vertical line was 3.3±1.2 mm in specimens with convex roof. The distance of the roof (the straight line between the openings of RSPV and LSPV from inside of the hearts) was 33.3±5.3 mm. The mean diameter between septum and lateral wall of LA was 35.4±5.7 mm. The anteroposterior LA diameter was 33.2±5.1 mm.

A roof pouch was present in five specimens (8.9%). The mean diameter of this pouch was 5.6±2.4 mm. Three of specimens were from flat roof and two of them were from convex roofs.

Septal band

Septal band was found internally in four specimens (7.1%) (Fig. 4). Septal band was on the interatrial septum as muscular ridge. The oval fossa is probe-patent in 12 specimens (21.4%).

Thin areas

Thin areas on the atrial wall were observed in front of a light source around left atrial appendage orifice. They were around the left atrial appendage orifice. The minimum thickness of these thin areas was 1.2±0.5 mm. The mean distance between the sulci on these thin areas and the orifice of left atrial appendage was 2.4±1.0 mm.

The atrial wall between the upper pulmonary veins was thicker than that between the lower ones.

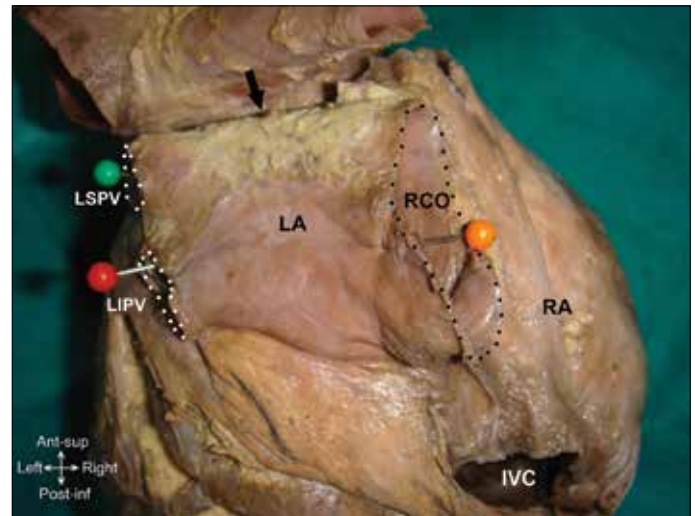


Figure 1. External view of the left atrium with flat roof and unilateral common ostium on the right side. Left superior pulmonary vein (LSPV), left inferior pulmonary vein (LIPV) and right common ostium (RCO) were indicated by the dotted line

arrow: flat roof, IVC - inferior vena cava; LA- left atrium; LIPV - left inferior pulmonary vein; LSPV - left superior pulmonary vein; RA - right atrium; RCO - right common ostium

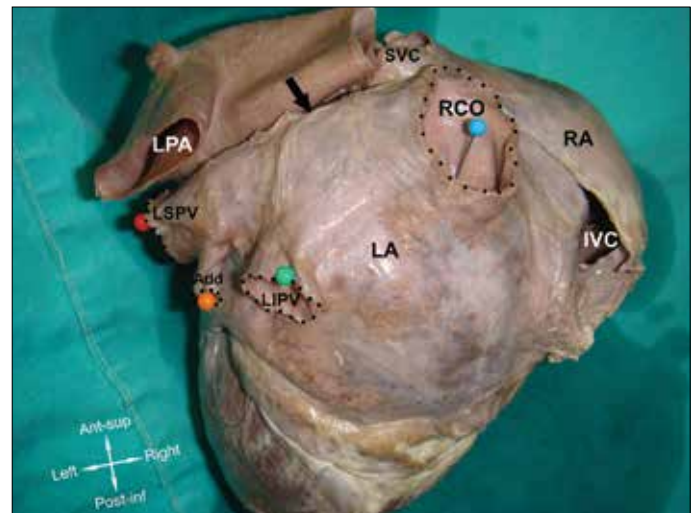


Figure 2. External view of the left atrium with convex roof and complex type (additional vein opening on the left side and common ostium on the right side). Left superior pulmonary vein (LSPV), left inferior pulmonary vein (LIPV), additional vein (Add) and right common ostium (RCO) were indicated by the dotted line

arrow: convex roof, Add - additional vein; IVC - inferior vena cava; LA - left atrium; LPA - left pulmonary artery; LIPV - left inferior pulmonary vein; LSPV - left superior pulmonary vein; RA - right atrium; RCO - right common ostium; SVC - superior vena cava

The anatomic features of pulmonary vein openings

The number of pulmonary vein openings into LA was observed and recorded. The openings were smooth and oval. Five different patterns of pulmonary vein openings were described:

Type 1 (common arrangement): The common arrangement was seen in 41 specimens (73.2%). The four pulmonary veins opened into the upper posterolateral surfaces of the LA, two on each side in this form.

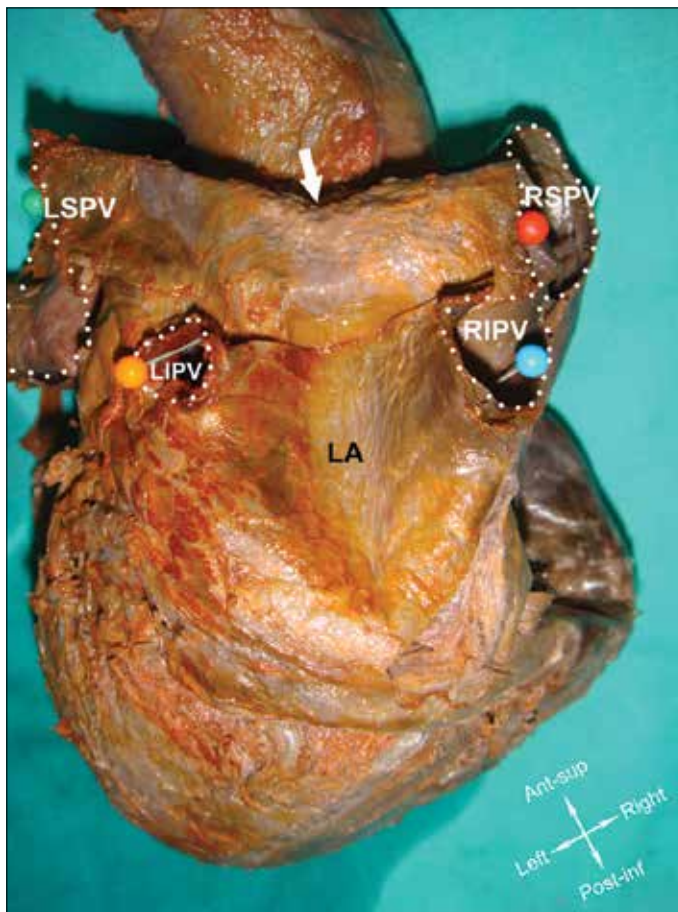


Figure 3. External view of the left atrium with concave roof. Left superior pulmonary vein (LSPV), left inferior pulmonary vein (LIPV), right superior pulmonary vein (RSPV) and right inferior pulmonary vein (RIPV) were indicated by the dotted line

arrow: concave roof, LA - left atrium; LIPV - left inferior pulmonary vein; LSPV - left superior pulmonary vein; RIPV - right inferior pulmonary vein; RSPV - right superior pulmonary vein

Type 2 (unilateral common ostium): The unilateral common ostium was observed on the left side in eight specimens (14.3%) and on the right side in two specimens (3.6%) (Fig. 1).

Type 3 (unilateral additional vein): The unilateral additional vein with an independent atriopulmonary venous junction was recorded on the right side in two specimens (3.6%) and on the left side in one specimen (1.8%) (Fig. 5).

Type 4 (bilateral additional vein): The additional vein on both side was determined in one specimen (1.8%) (Fig. 6).

Type 5 (complex type): The additional vein opening on the left side and a common ostium on the right side were together in one specimen (1.8%) (Fig. 2).

The additional veins had narrower atriopulmonary venous junction than the superior and inferior pulmonary veins.

Discussion

The clinical importance of LA size assessment has been discounted for some time although knowledge of LA and pulmonary vein anatomy is mandatory both before and during the best catheter ablation procedure in restoration of sinus rhythm (6, 9).

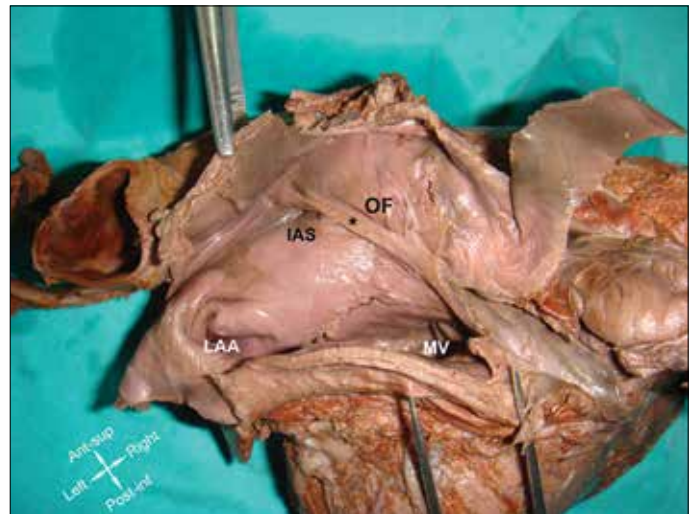


Figure 4. Internal aspect of the left atrium with septal band on the interatrial septum

LAA - left atrial appendage; IAS - interatrial septum; MV - mitral valve; OF - oval fossa.
*-septal band

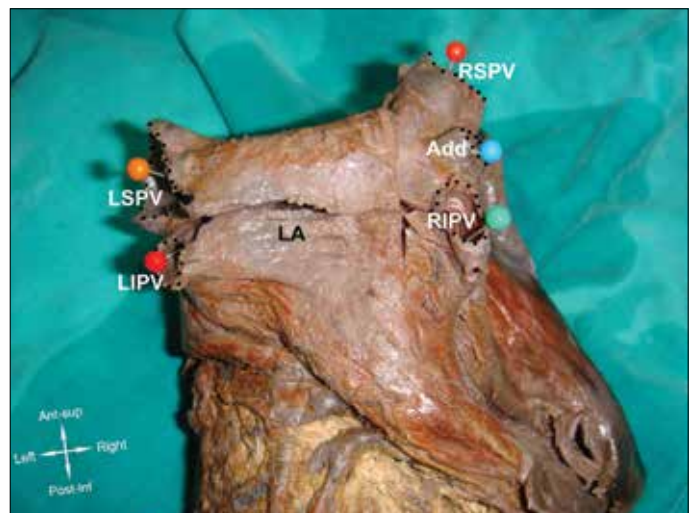


Figure 5. External view of the left atrium with unilateral additional vein on the right side

Add - additional vein; LA - left atrium; LIPV - left inferior pulmonary vein; LSPV - left superior pulmonary vein; RIPV - right inferior pulmonary vein; RSPV - right superior pulmonary vein

den Uijl et al. (6) determined that the enlargement of the left atrium in the anteroposterior direction was related to a greater risk of AF recurrence. In present study, LA size and its distances to neighbouring structures in normal population were given in the results.

LA roof pouch has also a clinical importance because of its relation with AF. Tops et al. (9) determined LA roof patients with AF. Lazoura et al. (10) compared the prevalence and mean length and width of LA accessory appendages and pouch between a group of patients with AF and group of patients in sinus rhythm by using cardiac computed tomography (10). They found no difference between two groups. The pouch in present study and the study of Lazoura et al. (10) were seen 8.9% and 20.5% in normal population respectively.

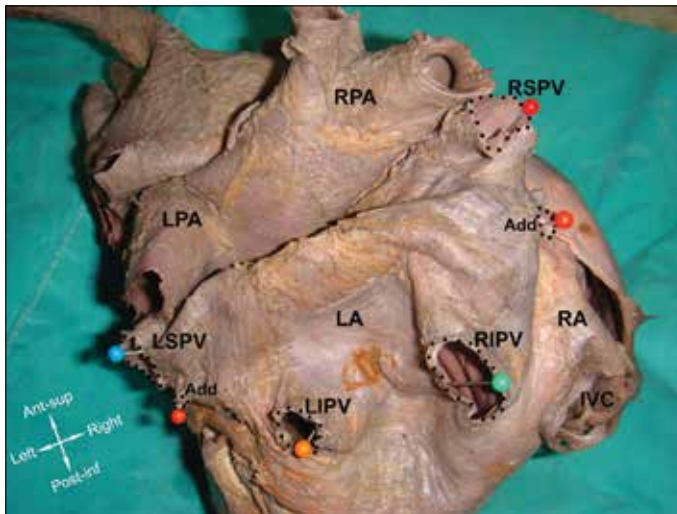


Figure 6. External view of the left atrium with additional vein on both side
Add - additional vein; IVC - inferior vena cava; LA - left atrium; LIPV - left inferior pulmonary vein; LPA - left pulmonary artery; LSPV - left superior pulmonary vein; RA - right atrium; RIPV - right inferior pulmonary vein; RPA - right pulmonary artery; RSPV - right superior pulmonary vein

Shizukuda et al. (11) reported a 75-year-old male with a history of persistent AF had an anomalous ridge on the left atrial side of the atrial septum. This ridge was formed along the superior edge of the oval fossa in the LA (11). This ridge was determined in four specimens in present study and they were along the anterior edge of the oval fossa.

Ho et al. (7) had a review about atrial structure and fibers. They explained that extensions of atrial myocardium onto pulmonary veins and superior vena cava were common (7). Wang et al. (12) used nine normal postmortem human hearts to explain architecture of atrial musculature. They described the left septoatrial bundle as a flattened muscle seen internally. It originated on the anteroinferior margin of the septum and then passed to the anterior base of the atrium. This band attached to the leaflet of mitral ring (12). This location of septal band was the same as described in present study. The probe-patent oval fossa was seen 21.4% of the specimens. This range was approximately 25-30% in the study of Ho et al. (7).

Su et al. (8) determined thin atrial wall areas with transillumination as in present study in the vicinity of the LAA. This areas could have the risk of perforation on the atrial wall (8). The thickness of these thin areas were about 1mm in both studies.

Recent studies in ablative therapy for AF created new interest in the pulmonary vein anatomy also (3). The present study demonstrated the LA and pulmonary vein openings in cadaver human hearts. To evaluate the left atrial pulmonary venous anatomy is requested prior to radiofrequency catheter ablation (RFCA) procedures in patients with refractory cardiac arrhythmias. Multidetector CT (MDCT) visualization or 3D gadolinium-enhanced magnetic resonance angiography are requested to plan and guide the procedure. It is known that the success of RFCA is highly dependent on the preprocedural understanding of 3D anatomy of the distal pulmonary veins at their entry into

the LA. Left atrial anatomy including atrial size and venous attachments are also important to identify stenoses, dissections and perforations (1, 2, 5, 6).

Neither fluoroscopy nor echocardiography can adequately demonstrate the anatomy of left atrium and distal pulmonary veins. 3D gadolinium-enhanced magnetic resonance angiography is a better method for demonstration but AF patients with pacemakers or defibrillators cannot undergo such imaging. Stanford et al. (2) suggested especially MDCT for visualization of this anatomy. We hypothesize that the anatomic studies on human cadaver hearts as the present study will also support this aim.

The anatomic route of catheter in RFCA: The RFCA procedure consists of placing catheter with an ablation electrode at its tip into the LA via femoral vein access. The anatomic way of specialized catheter after the femoral vein access is into the inferior vena cava and right atrium under fluoroscopic guidance; then, via a transseptal puncture, the catheter is advanced into LA. The pulmonary vein openings are identified by this method (2).

Anatomic studies demonstrated that LA and proximal parts of pulmonary vein anatomy was highly variable. A common ostium was most frequently found on the left-sided pulmonary veins, whereas an additional vein was most frequently found on the right side (5, 9). The common ostium was also seen on left side with a higher incidence in present study.

Stanford et al. (2) reported that pulmonary venous anatomy variants were present 30% of individuals. They also demonstrated that conjoined or common veins occurred more commonly on the left side (2). The results of present study about the variants of pulmonary veins were similar to results of Stanford et al. (2). We also determined the variant forms in present specimens was 26.8%.

The study of Ho et al. (13) demonstrated the common arrangement of four openings in 69% of 35 heart specimens, and 31% common vein opening on one or both side. Kaseno et al. (14) reported the typical pattern of four pulmonary veins with four separate ostia was in 76% of their patients. The common ostium was found on the left side in 8% of patients and right side in 0.76% of patients (14). A study by Marom et al. (15) also showed the presence of common ostium was in three patients (2%) on the right side as in present study.

Stanford et al. (2), Ho et al. (16) noted that the accessory veins were occurred more frequently on the right side, with separate drainage of the middle lobe or superior segment of the right lower lobe or superior segment of the right lower lobe. The results of present study related to the location side of accessory vein openings were different from study of Stanford et al. (2). There were equal number of openings both on left and right sides in present study (2, 16).

The complications of RFCA include endocardial scarring, pulmonary vein dissection and perforation. Because vagus nerve fibers within the walls of the pulmonary veins, bradyarrhythmias and asystole can occur during the procedure (2). We believe that a detailed anatomic knowledge with accurate mea-

surements about LA and pulmonary veins openings will help radiologists, cardiologists and surgeons for successful RFCA and other procedures. Understanding of the location and orientation of these structures based on anatomic studies will help to reduce risks of damage during the procedures.

Study limitations

The major limitation of present study was relatively small sample size. The other limitations were the limited medical records about the cadavers and using hearts from formalin fixed cadavers. The measurements can be different in vivo distances although the organs are not influenced formalin as much as skeletal muscles.

Conclusion

By means of the presented study, the significance of PV variants was emphasized. The pre-procedural imagings of LA and PV can offer safety during the interventional procedures.

Conflict of interest: None declared.

Peer-review: Externally peer-reviewed.

Authorship contributions: Concept - Z.A.A.İ., H.Ü., T.Ö.; Design - Z.A.A.İ., H.Ü.; Supervision - Z.A.A.İ., H.Ü., T.Ö.; Resource - Z.A.A.İ., H.Ü., T.Ö.; Material - Z.A.A.İ., H.Ü., T.Ö.; Data collection &/or processing - Z.A.A.İ., H.Ü.; Analysis &/or interpretation - Z.A.A.İ., H.Ü.; Literature search - Z.A.A.İ., H.Ü.; Writing - Z.A.A.İ., H.Ü.; Critical review - Z.A.A.İ., H.Ü., T.Ö.; Other - Z.A.A.İ., H.Ü., T.Ö.

References

1. Lacomis JM, Goitein O, Deible C, Schwartzman D. CT of the pulmonary veins. *J Thorac Imaging* 2007; 22: 63-76. [\[CrossRef\]](#)
2. Stanford W, Breen JF. CT evaluation of left atrial pulmonary venous anatomy. *Int J Cardiovasc Imaging* 2005; 21: 133-9. [\[CrossRef\]](#)
3. Park HC, Shin J, Ban JE, Choi JI, Park SW, Kim YH. Left atrial appendage: morphology and function in patients with paroxysmal and persistent atrial fibrillation. *Int J Cardiovasc Imaging* 2013; 29: 935-44. [\[CrossRef\]](#)
4. Wongcharoen W, Tsao HM, Wu MH, Tai CT, Chang SL, Lin YJ, et al. Morphologic characteristics of the left atrial appendage, roof, and septum: implications for the ablation of atrial fibrillation. *J Cardiovasc Electrophysiol* 2006; 17: 951-6. [\[CrossRef\]](#)
5. Köse S, Başarıcı İ, Kabul KH, Bozlar U, Amasyalı B. Catheter ablation of atrial fibrillation in a patient with unusual pulmonary vein anatomy involving right upper pulmonary vein. *Anadolu Kardiyol Derg* 2012; 12: 76-7.
6. den Uijl DW, Tops LF, Delgado V, Schuijff JD, Kroft LJ, de Roos A, et al. Effect of pulmonary vein anatomy and left atrial dimensions on outcome of circumferential radiofrequency catheter ablation for atrial fibrillation. *Am J Cardiol* 2011; 107: 243-9. [\[CrossRef\]](#)
7. Ho SY, Sánchez-Quintana D. The importance of atrial structure and fibers. *Clin Anat* 2009; 22: 52-63. [\[CrossRef\]](#)
8. Su P, McCarthy KP, Ho SY. Occluding the left atrial appendage: anatomical considerations. *Heart* 2008; 94: 1166-70. [\[CrossRef\]](#)
9. Tops LF, van der Wall EE, Schalij MJ, Bax JJ. Multi-modality imaging to assess left atrial size, anatomy and function. *Heart* 2007; 93: 1461-70. [\[CrossRef\]](#)
10. Lazoura O, Reddy T, Shriharan M, Lindsay A, Nicol E, Rubens M, et al. Prevalence of left atrial anatomical abnormalities in patients with recurrent atrial fibrillation compared with patients in sinus rhythm using multi-slice CT. *J Cardiovasc Comput Tomogr* 2012; 6: 268-73. [\[CrossRef\]](#)
11. Shizukuda Y, Muth J, Chaney C, Attari M. Anomalous ridge on the left atrial side of the atrial septum. *Ann Card Anaesth* 2012; 15: 161-2. [\[CrossRef\]](#)
12. Wang K, Ho SY, Gibson DG, Anderson RH. Architecture of atrial musculature in humans. *Br Heart J* 1995; 73: 559-65. [\[CrossRef\]](#)
13. Ho SY, Cabrera JA, Sánchez-Quintana D. Anatomy of pulmonary vein-atrial junction. In: Chen SA, Haissaguerre M, Zipes D, editors. *Thoracic Vein Arrhythmias: Mechanisms and Treatment*. New York: Blackwell; 2004.p.42-53. [\[CrossRef\]](#)
14. Kaseno K, Tada H, Koyama K, Jingu M, Hiramatsu S, Yokokawa M, et al. Prevalence and characterization of pulmonary vein variants in patients with atrial fibrillation determined using 3-dimensional computed tomography. *Am J Cardiol* 2008; 101: 1638-42. [\[CrossRef\]](#)
15. Marom EM, Herndon JE, Kim YH, McAdams HP. Variations in pulmonary venous drainage to the left atrium: implications for radiofrequency ablation. *Radiology* 2004; 230: 824-9. [\[CrossRef\]](#)
16. Ho SY, Anderson RH, Sánchez-Quintana D. Atrial structure and fibres: morphologic bases of atrial conduction. *Cardiovasc Res* 2002; 54: 325-36. [\[CrossRef\]](#)