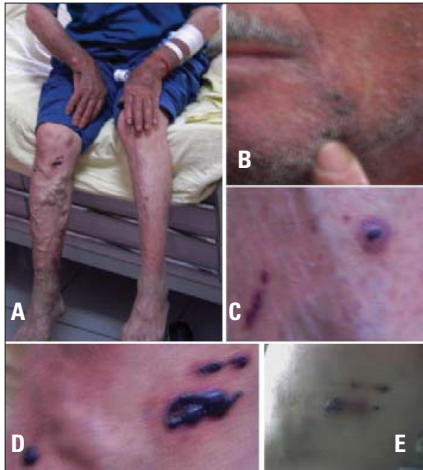

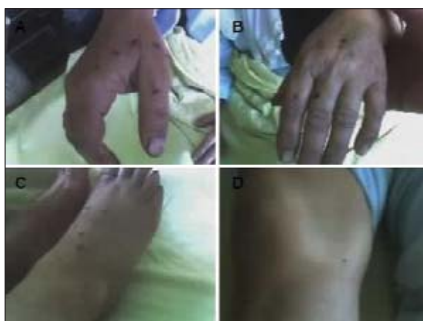## Warfarin induced benign acral cutaneous lesions in two cardiac patients with decreased protein C and S activity

*Protein C ve S aktiviteleri düşük olan iki kalp hastasında görülen warfarin'e bağlı selim uzuv derisi döküntüleri*

We have presented two cardiac patients with protein C and S deficiency who were admitted with benign warfarin related cutaneous lesions. First case was a 60-year-old man. He was admitted with a



**Figure 1.** Cutaneous lesions on the upper and lower limbs distal to the ankle and elbow joints in Case 1 (A). Lesion on the left side of the cheek (B). Red discoloration around the vesicles on the focused lesions of the lower extremity (C, D). The largest lesion on the right leg (D), like other lesions, was greatly improved after 9 days (E)



**Figure 2.** Smaller and mostly maculopapules lesions located on the hands (A, B) and the feet (C) (Case 2). Few lesions are seen on the right leg (D)

transient ischemic attack. An anticoagulant treatment was begun with 2.5 mg warfarin once a day. After 3 days, he was re-admitted with development of skin lesions, which were painless, papular and vesicular or bullous, 2 to 25 mm in diameter, dark purple in color, and involving specifically upper and lower limbs distal to the ankle and knee joints (Fig. 1). Gross hematuria also occurred on the 4th day of hospitalization due to coagulopathy. Second case was a 51-year-old woman with rheumatic heart disease, which was treated with mitral commissurotomy 8 years ago. She complained on numbness on both arms for one hour. Warfarin 5 mg once a day was administered together with enoxaparine. On the 4th day, small dark purple lesions appeared mainly on the skin of hands and feet (Fig. 2). Pathological examination of the lesions has shown capillary dilatation with mild perivascular lymphocytic infiltration and subcorneal hematoma. There was spontaneous and substantial healing of the skin lesions during the next few days in both cases. We suggested "atypical warfarin induced skin necrosis" for the definition of the lesions. However, we are not sure that these lesions might be a precursor of typical warfarin induced skin necrosis. The treatment of these benign acral cutaneous lesions might be discontinuation of warfarin treatment and initiation of heparin.

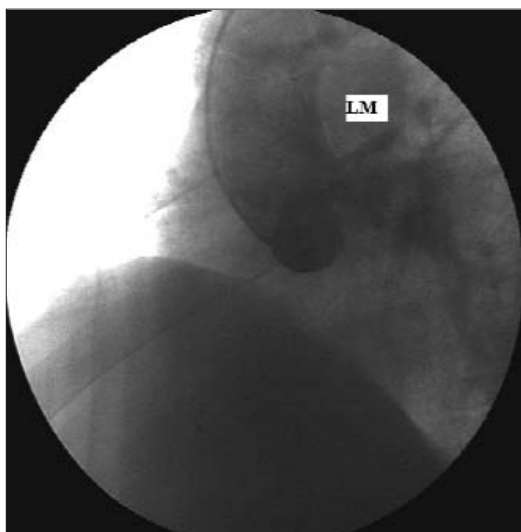**Mutlu Vural, Servet Usta\*, Rabia Kaya\*\***  
From Clinics of Cardiology, \*Dermatology and \*\*Pathology,  
Kırşehir State Hospital, Kırşehir, Turkey

**Address for Correspondence/Yazışma Adresi:** Dr. Mutlu Vural  
Bayar cad. Pınar sok. Çatalpınar Sitesi B8/27 Kozyatağı, İstanbul, Turkey  
Mobile: +90 505 385 66 09 E-mail: heppikalp@yahoo.com

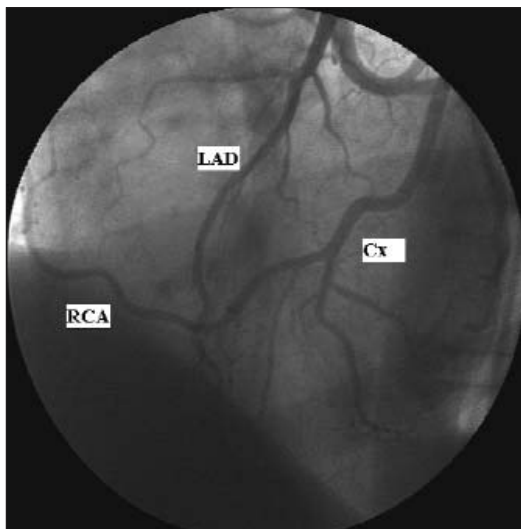
## Right coronary artery originating from distal circumflex artery in a patient with single coronary artery

*Tek koroner arterli bir hastada, distal sirkumfleks arterden çıkan sağ koroner arter olgusu*

A 46-year-old male patient admitted to our hospital with the complaint of 10-minute-lasting retrosternal, squeezing chest pain which appearing during exercise. Patient did not have any atherosclerotic risk factor except smoking. Blood pressure was 130/70 mm/Hg and pulse, 80 beats/min. Cardiovascular and other physical examinations were normal. Basal electrocardiogram, telecardiogram and the echocardiography were within normal limits. Treadmill exercise-stress test showed 1mm ST depression in leads V-4-6, DII, DIII and aVf leads. On coronary angiography, right coronary artery was not able to be cannulated at its normal location. Then aortography showed a solitary coronary artery arising from left aortic sinus (Fig. 1). On selective left coronary angiography, left anterior descending, circumflex artery and the their branches were in normal origin and distribution. Circumflex artery was dominant and posterior descending artery was originated from it. Right coronary artery arose from the distal circumflex artery and followed the course, retrogradely, of the right coronary artery distribution (Fig. 2). There was no obstructive lesion of the coronary arteries.



**Figure 1. Aortography view of left main artery as a single coronary ostium**



**Figure 2. Coronary angiography view of single coronary artery and right coronary artery originating from distal circumflex artery**

LAD- left anterior descending artery, LM- left main coronary artery, , Cx- circumflex artery

Single coronary artery is a rare abnormality in coronary circulation and is associated with other congenital cardiac malformations such as bicuspid aorta, transposition of the great vessels and coronary arteriovenous fistulae. Among general population, such an anomaly is detected in 0.04% of people undergoing coronary angiography. Patients with coronary abnormality exhibiting abnormal origin are though usually asymptomatic they sometimes are presented with ischemia and sudden death. In our case, there was no any other accompanying cardiac abnormality and it was an example of type L-1 in according to Lipton angiographic classification.

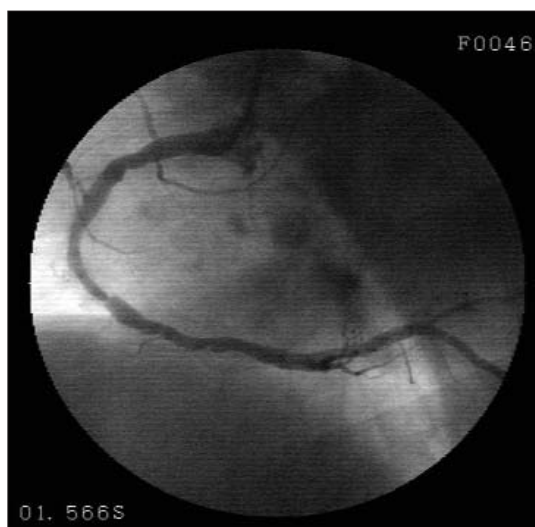
**Turgut Karabağ, Abdullah İçli, Halil Kahraman**  
**Department of Cardiology, Büyükşehir Hospital, Konya, Turkey**

**Address for Correspondence/Yazışma Adresi:** Turgut Karabağ  
Sezin Kardiyoloji Merkezi, Meram Yeni Yol No:166 42070 Meram, Konya, Turkey  
Phone: + 90 332 323 33 06 Fax: + 90 332 324 20 17 E-mail: turgutkarabag@yahoo.com

## Successful reimplantation of prematurely displaced stent to the target lesion without balloon inflation during percutaneous intervention to the right coronary artery

*Sağ koroner artere perkütan girişim sırasında serbest kalan stentin hedef lezyona balon şişirilmeden başarılı bir şekilde yerleştirilmesi*

A 62-year-old man with type2 diabetes mellitus was admitted for coronary angiography due to typical angina provoked by effort. On coronary angiography dominant right coronary artery (RCA), 50-60% narrowing beyond the right ventricular branch, extensive consecutive narrowings of 90% in acute marginal branch were detected (Fig. 1). Guiding catheter was inserted to the right coronary ostium and the direct stent was advanced to proximal to the RCA; however, attempt to advance it distally was unsuccessful. During withdrawal, balloon displaced from the stent. The system completely disengaged while attempting to reposition the balloon in the stent. The stent was entrapped proximal to RCA (Fig. 2). When the first guidewire was inserted, it was noticed to be lying outside the stent. Hence, a second guidewire was advanced to pass through the stent and to inflate the original balloon; however, upon failure to reposition the balloon into the stent, a balloon with lower diameter and length was used. This balloon was not able to drive the stent towards the target lesion due to insufficient diameter. Thus, original balloon was used to push the stent from the proximal tip and the lesion was negotiated by the stent (Fig. 3). Stent was deployed in the target lesion with a low-profile balloon to provide predilation after which original balloon was inflated (Fig. 4) to an optimal pressure to ensure total dilation (Fig. 5).



**Figure 1. A lesion extending from ventricular branch of right coronary artery to crux cordis, causing severe narrowing in mid portions**