

The X-mark signature of pulmonary veins in an infant's heart

We present here the case of an infant with interesting pulmonary venous anatomy in which pulmonary veins drain into systemic veins via 2 separate obstructed vertical veins (VVs). The 2-month-old female patient presented with severe cyanosis and respiratory distress. An echocardiographic study revealed right atrial isomerism, complete atrioventricular septal defect, double outlet right ventricle, pulmonary stenosis, a single left-sided superior caval vein (SVC), and supracardiac obstructed total anomalous

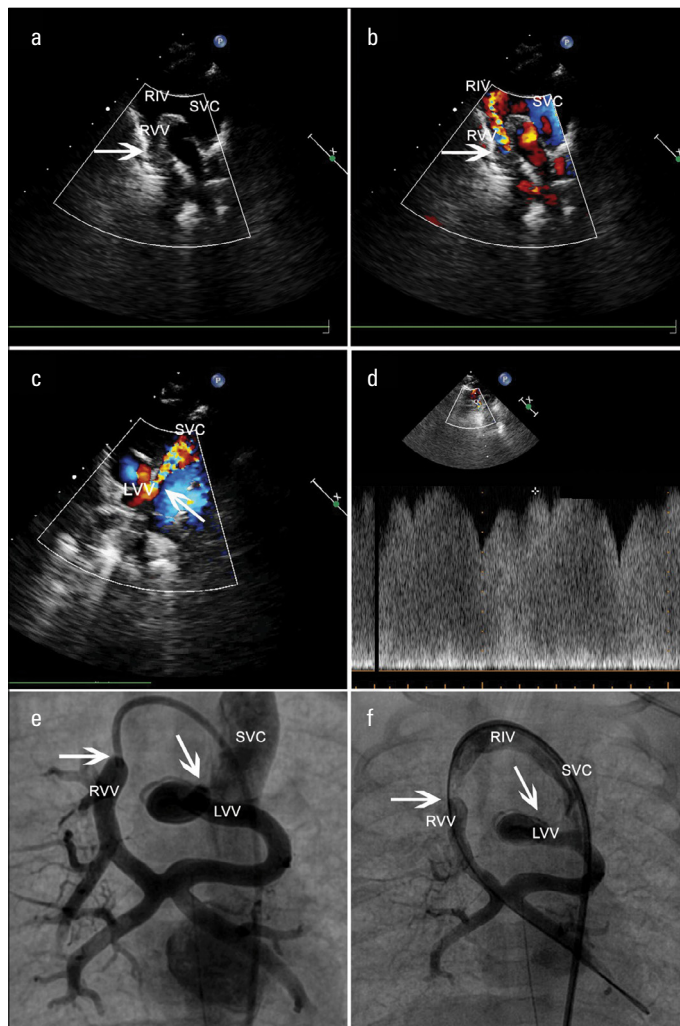


Figure 1. a-f. (a, b) Suprasternal echocardiographic 2-D and colored Doppler views demonstrating the continuation of the right vertical vein (RVV) draining into the right innominate vein (RIV), which in turn drains into the left-sided superior caval vein (SVC). White arrows point out the obstruction sites. (c) Suprasternal echocardiographic colored Doppler view demonstrating the left vertical vein (LVV) draining into the left-sided superior caval vein (SVC). White arrows point out the obstruction sites. (d) The pulse-wave Doppler gradient (30 mm Hg) from the obstruction site. (e, f) The anteroposterior contrast injections to the right vertical vein (RVV) demonstrating the merging of the right and left pulmonary veins forming an X figure behind the left atrium and drainage of RVV to RIV and the tortuous LVV to the left-sided SVC. White arrows point out the obstruction sites.

ous pulmonary venous connection (TAPVC). Pulmonary veins on both sides drained into the right innominate vein (RIV) and left-sided SVC via 2 separate right- and left-sided VVs obstructed at their entrance to RIV and left-sided SVC, respectively (Fig. 1a-d). She was taken to the catheterization laboratory under emergency conditions for stent implantation to the stenotic VVs to relieve the obstruction (Fig. 1e, f and Video 1). A 6×12-mm Omnilink RADIX 2 stent was placed to the right-sided VV of the patient, and the gradient of the obstruction decreased from 27 mm Hg to 9 mm Hg and the oxygen saturation improved from 55% to 80%.

There is a considerable variability reported about the pulmonary to systemic venous connection in all forms of TAPVC, especially in heterotaxy syndromes. However, to our knowledge, the left and right lower veins draining into a confluence from which the left and right vertical veins arise and take the left and right upper veins, respectively, is a rare entity. Being aware of this entity for accurate diagnosis by echocardiography and emergent transcatheter or surgical manipulations to relieve the obstruction is crucial for the outcome.

Video 1. The anteroposterior contrast injections to the right vertical vein (RVV) demonstrating merging of the right and left pulmonary veins forming an X figure behind the left atrium and drainage of RVV to the right innominate vein (RIV) and the tortuous left vertical vein (LVV) to the left-sided superior caval vein (SVC). White arrows point out the obstruction sites.

Pelin Ayyıldız, İbrahim Cansaran Tanıdır, Erkut Öztürk, Alper Güzeltaş
Department of Pediatric Cardiology, İstanbul Mehmet Akif Ersoy Thoracic and Cardiovascular Surgery, Research and Training Hospital; İstanbul-Turkey

Address for Correspondence: Dr. Pelin Ayyıldız

İstasyon Mah. Turgut Özal Bulvarı No:11

Halkalı Küçükçekmece- İstanbul-Türkiye

Phone: +90 212 692 20 00-4065

E-mail: pelinhoglu2@yahoo.com

©Copyright 2015 by Turkish Society of Cardiology - Available online at www.anatoljcardiol.com
 DOI:10.5152/AnatolJCardiol.2015.6707

A man with a pellet gunshot wound

A 44-year-old male was admitted to the emergency department with a pellet gunshot wound 1 day ago. He was conscious and had ecchymosis in the back skin and presented with backache, palpitation, and short breath. His whole-body X-ray (Fig. 1) image showed grainy high-density shadows in the chest and abdomen. A computed tomography (CT) scan revealed those high-density shadows in areas of the lower lobe of the left lung, descending aorta, post-mediastinum, lower esophagus, left twelfth ante-rib, post-duodenum, adjacent lower thoracic vertebrae, back skin, and soft tissues (Fig. 2). Furthermore, a CT scan found an ascending aortic aneurysm with a diameter of 4.69 cm. Because of hematomas in the post-mediastinum and some bullets adjacent to the descending aorta, surgery was necessary. We took out the bullets that were fatal to the aorta

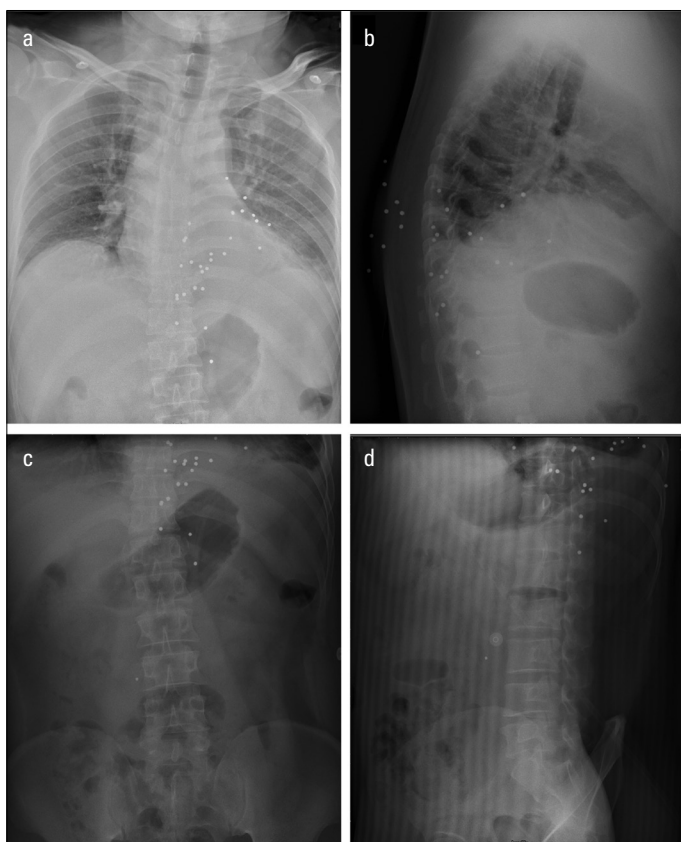


Figure 1. X-ray image showing grainy high-density shadows in the chest and abdomen

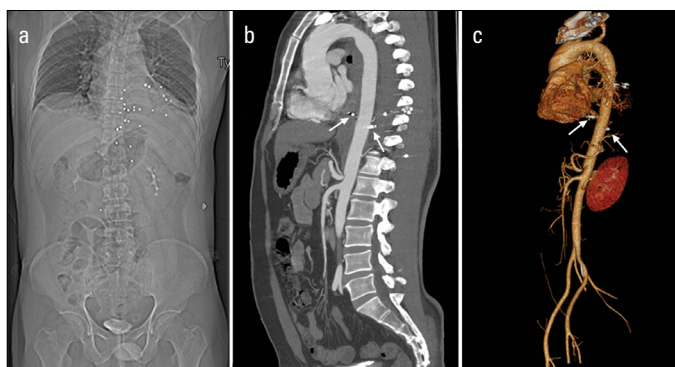


Figure 2. CT image revealing the sites of those pellets, especially those near the descending aorta (arrows)

without cardiopulmonary bypass and cleared the mediastinal hematomas. The patient was clinically well and was safely discharged.

Mengsi Li, Dongxu Li*, Qi An*

Departments of Nursing, *Cardiovascular Surgery, West China Hospital, Sichuan University; Sichuan-P.R. China

Address for Correspondence: Qi An, M.M.

No. 37 Guo Xue Xiang, Chengdu, Sichuan, 610041-P.R. China

Phone: +86 028 85422897

Fax: +86 028 85421833

E-mail: cardioanqi2013@163.com

©Copyright 2015 by Turkish Society of Cardiology - Available online at www.anatoljcardiol.com

DOI:10.5152/AnatolJCardiol.2015.6783