

Optical coherence tomography imaging of intrastent neointimal bridge caused by semicircumferential dissection after drug eluting balloon dilatation of instent restenosis of saphenous venous graft

During redilatation of a stent by a balloon, the dissection of the neointimal tissue commonly can be detected by IVUS or OCT, but the exact clinical relevance of the dissection in variable type is not known in the case of angiographically good result.

Sixty-two year old female patient had CABG operation in 1998 (LIMA-LAD, sequential SVG to the 2nd OM branch of the LCx and the PL of the RCA). Between 2006 and 2012 she had 5 PCIs with stent implantations and balloon redilatations in the sequential SVG (altogether 5 BM stents and 1 DES were implanted). The last intervention before the index procedure was performed under IVUS guidance 7 months ago with paclitaxel eluting balloon (DEB) (Pantera Lux, Biotronik) redilatation because of recurrent restenosis. IVUS images showed dissection of the intrastent tissue immediately after redilatation (Fig. 1A, Video 1. See corresponding video/movie images at www.anakarder.com).

The index procedure was indicated because of recurrent angina like symptoms. This case the coronary angiography showed only mild lumen narrowing inside the stents (Fig. 1B). OCT investigation detected a "bridge like" neointimal tissue in the previously dilated stent (Fig. 1C, Video 2. See corresponding video/movie images at www.anakarder.com). Careful analysis of the OCT images revealed that the intrastent tissue bridge not detected even by IVUS during the previous intervention, originated from circumferential intrastent dissection caused by the before DEB redilatation.

This case shows that the redilatation of instent restenosis of the SVG by DEB can be associated such a stable form of circumferential dissection of intrastent proliferation which does not limit the flow, furthermore functionally can serve as a "flow divider". The long term prognosis of this phenomenon is unknown.

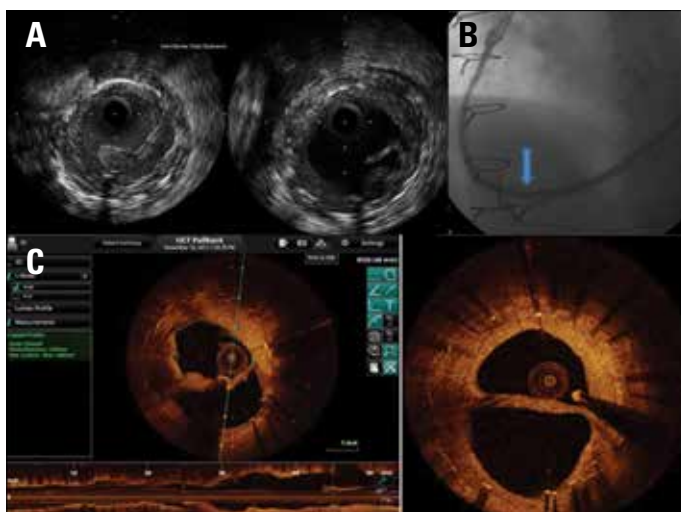


Figure 1. (A) left panel: native image, right- during intracoronary contrast injection, (B) sequential SVG to the PL and the OM branches; the arrow indicates the site of the before redilatation (C) OCT images of the SVG with the intrastent neointimal bridge

Zsolt Köszei, Tibor Szűk, Gusztáv Vajda, Frederick Marty¹, Csaba Jenei
 Institute of Cardiology, University of Debrecen, Debrecen-Hungary
¹St. Jude Medical Export GmbH; Vienna-Austria

Video 1. IVUS pullback immediately after the redilatation of the instent restenosis. During the investigation an intracoronary contrast injection delineated clearly the dissection of the intrastent tissue

Video 2. OCT pullback of the follow up catheterization

Address for Correspondence: Dr. Zsolt Köszei M.D., Ph.D., F.E.S.C.,
 Institute of Cardiology, University of Debrecen 4004, Móricz Zs. Krt. 22.
 Debrecen-Hungary

Phone: 36 30 2589442

E-mail: koszei@med.unideb.hu

Available Online Date: 04.02.2014

©Copyright 2014 by AVES - Available online at www.anakarder.com

DOI:10.5152/akd.2014.5200

Aortic saddle embolism caused by right ventricle thrombus in a 2-year-old girl with Ebstein anomaly and Glenn shunt

A 2-year-old girl with Ebstein anomaly who had undergone Glenn operation presented with sudden onset of bilateral lower limb ischemia with severe pain and color changes (Fig. 1A). Transthoracic echocardiography showed an Ebstein anomaly and thrombus in the right ventricle. Arterial Doppler signals were inaudible but venous Doppler signals were audible in the both of the limbs. Multislice computed tomography showed obstruction at the iliac bifurcation of the aorta due to a saddle thrombus and a huge thrombus in the apex of right ventricle. In addition, there were occlusions in the right anterior and posterior tibial artery and right peroneal artery, and in the left external iliac artery (Fig. 2, 3). After anticoagulation with intravenous heparin and urgent transfemoral thrombectomy distal perfusion and pulsation were completely restored in the left limb. However, pulsation did not return to normal in the dorsalis pedis and posterior distal arteries on the right side. Circulation of the right foot was not restored and gangrene developed (Fig. 1B). It was decided for amputation due to unsuccessful revascularization. However septicemia and pulmonary hemorrhage were developed and she died prior to amputation.

Sudden occlusion of the aorta is very rare especially in childhood and it usually occurs at its bifurcation and results in major threat to leg or patient survival, despite extensive collateralization. Prognosis in arterial occlusion is time dependent. The early recognition, supportive care, and prompt diagnosis are essential elements of management.

Kadir Babaoğlu, Murat Deveci, Şadan Yavuz*, Gürkan Altun,
 Yonca Anık**

Departments of Pediatric Cardiology and *Cardiovascular Surgery,
 **Radiology, Faculty of Medicine, Kocaeli University; Kocaeli-Turkey