

Surgery for the failing heart after myocardial infarction

Miyokard infarktüsü sonrası gelişen kalp yetersizliğinde cerrahi

Constantine L. Athanasuleas, Gerald D. Buckberg¹

Department of Cardiothoracic Surgery, School of Medicine, University of Alabama, Birmingham, Alabama

¹Division of Cardiothoracic Surgery, David Geffen School of Medicine, University of California Los Angeles, Los Angeles, California, USA

ABSTRACT

Function follows form and this maxim provides an understanding of the pathophysiology of congestive heart failure following myocardial infarction. The heart fails as it enlarges and becomes more spherical. Surgical methods to treat dilated ischemic cardiomyopathy have evolved and been applied to thousands of patients worldwide. Known as "surgical ventricular restoration", or SVR, the operation reduces left ventricular volume and restores the ventricle towards a more conical normal shape. Global systolic function is improved. Mechanical synchrony is restored. Arrhythmias are largely abated. Neurohumoral mediators that stimulate continued ventricular enlargement are largely reduced. Finally, there is marked and sustained symptomatic improvement of congestive heart failure post-infarction patients after SVR.

(*Anadolu Kardiyol Derg 2008; 8: Suppl 2; 93-100*)

Key words: Surgical ventricular restoration, myocardial infarction, chronic heart failure, outcomes

ÖZET

Fonksiyon, formu izler ve bu özdeyiş, miyokard enfarktüsü sonrası gelişen konjestif kalp yetersizliği patofizyolojisini anlamamızı sağlar. Kalp genişlediği ve daha küresel bir şekil aldığı zaman yetersiz kalır. Dilate iskemik kardiyomyopati hastalığını tedavi etmek için cerrahi yöntemler zaman içinde gelişti ve dünya çapında binlerce hastaya uygulandı. Ventrikülün cerrahi onarımı veya SVR olarak bilinen operasyon, sol ventrikül hacmini düşürür ve daha koni biçiminde normal bir şekle doğru ventrikülü onarır. Global sistolik fonksiyon iyileşir. Mekanik senkronizasyon onarılır. Aritmi büyük ölçüde azalır. Ventrikül genişlemesini devam ettiren nörohormonal mediyatörler normal düzeylere döner. Sonunda, SVR'den sonra postenfarktüs konjestif kalp yetersizliği olan hastalarda hastaneye yeniden yatışta önemli azalma ile beraber belirgin ve sürekli semptomatik iyileşme belirlendi. (*Anadolu Kardiyol Derg 2008; 8: Özel Sayı 2; 93-100*)

Anahtar kelimeler: Ventrikülün cerrahi onarımı, miyokard infarktüsü, kronik kalp yetersizliği, sonlanım noktaları

Introduction

Congestive heart failure (CHF) is an epidemic in the industrial world and consumes a major portion of the health care costs of many nations. Coronary artery disease continues to be the major cause of heart failure followed by valvular heart disease. The majority of heart failure cases is caused by coronary artery disease, and a major proportion of these is associated with prior myocardial infarction (1). Drug therapy has improved and heart failure clinics are very influential in reducing acute hospital visits, but the outcome of class III and IV heart failure secondary to ischemic disease continues to be poor. Destination therapy with ventricular assist devices is costly and the long-term results,

though improving, are still rather dismal. Cardiac transplantation, another alternative, is both costly and limited by the donor sources.

Increasingly, the standard of care in the treatment of patients with acute myocardial infarction is prompt restoration of blood flow to the infarct-related coronary artery. This is achieved by pharmacologic means or more commonly by acute percutaneous stenting interventions. Despite these efforts, many patients develop progressive dilation of the ventricle leading to congestive heart failure. In this section, we shall elucidate the interaction of form with function and offer surgical approaches in the treatment of heart failure in patients with dilated left ventricles following anterior myocardial infarction, the so-called "surgical ventricular restoration" (SVR) operation.

Address for Correspondence/Yazışma Adresi: Constantine L. Athanasuleas, M.D. Professor of Surgery, Department of Cardiothoracic Surgery University of Alabama, School of Medicine 1900 University Boulevard, THT-720 Birmingham, AL 35294, USA Phone: +1 205 934 2536 Fax: +1 205 502 6040 E-mail: cathanasuleas@mac.com

©Telif Hakkı 2008 AVES Yayıncılık Ltd. Şti. - Makale metnine www.anakarder.com web sayfasından ulaşılabilir.

©Copyright 2008 by AVES Yayıncılık Ltd. - Available on-line at www.anakarder.com

Shape, size, and function

The normal heart is a conical structure as first described by Hippocrates and Galen. A helical spiral at the cardiac apex was noted several hundred years ago and thought to be responsible for the force of ventricular ejection. Exactly how the spiral architecture of the myocardium relates to function has been revealed by Francisco Torrent-Guasp who systematically dissected mammalian hearts and linked form with function (2). His work, dating back to the 1950's, has become the basis of how the heart functions in both health and disease. He spatially unfolded the intact heart by macroscopic dissection, demonstrating a muscular band that begins at the pulmonary artery and ends at the aorta. This band contains a myocardial fold that separates the heart into two simple loops called the "basal" and "apical" loops. The structural components include a horizontal or transverse fiber orientation for the basal loop that surrounds the right and left ventricles, and a change in fiber direction through a spiral fold in the ventricular band to form a ventricular helix that now contains obliquely oriented fibers. These form descending and ascending segments of the apical loop with an apical vortex. These components are shown in Figure 1. The helical architecture of the normal heart has been confirmed by strain relationships using magnetic resonance imaging (MRI), corrosion casts showing spiral architecture, and by sonomicrometry. Each pattern reflects the normal oblique fiber orientation that conveys maximum force during ejection and suction (3).

The mechanism of normal myocardial contractility described the Torrent-Guasp model also explains myocardial dysfunction in diseased states. His model asserts that myocardial shape is the major determinant of global systolic ejection. The normally oriented oblique myocardial fibers produce an ejection fraction of approximately 60%. The infarcted dilated ventricle becomes spherical and the myocardial fibers become transversely oriented (Fig. 2). When this occurs, the ejection fraction falls sharply to about 30%, even when the intrinsic fiber shortening of the myocytes remains normal (4). This architectural disadvantage

limits deformation (twisting) that is visible at operation or by MRI and speckle echocardiography, negatively impacting the natural increment of strain development from mid-wall to apex (5). This further impairs sequential contraction efficiency and reduces ventricular function by producing mechanical dyssynchrony (6). Left ventricular and global ventricular dilation are the morphological consequences seen in congestive heart failure patients due to ischemic or non-ischemic causes. In ischemic disease, there is necrosis of myocardium that leads to remodeling. In non-ischemic disease, there is also a component of scar formation that is not necessarily uniform. The treatment of acute myocardial infarction by early reperfusion by thrombolysis or angioplasty has largely been successful in ameliorating left ventricular enlargement, but is not totally successful. Important data regarding this finding came years ago from the GUSTO study in which ventricular volumes were measured by right anterior oblique (RAO) ventriculography shortly after successful thrombolysis of an occluded coronary artery (7). Despite successful reperfusion of the infarct-related artery, 17% of patients had a left ventricular end-systolic volume index (LVESVI) greater than 40 ml/m² (normal LVESVI is 25 ml/m²). Progressive congestive heart failure and death rates were correlated with increasing ventricular volumes above this value. These findings were confirmed in another study that documented early LVESVI greater than 50 ml/m² in 20% of patients after successful recanalization of the infarct-related artery. In such patients, ventricular dilation over three years led to congestive heart failure by progressive dysfunction of the remote non-infarcted myocardium (8). Interestingly, LVEVSI, not ejection fraction, most closely predicts outcome in dilated cardiomyopathy, a fact poorly appreciated by most cardiologists in clinical practice (Fig. 3, 4) (9). Moreover, for a given ejection fraction, there may be a wide range of ventricular volume in ischemic cardiomyopathy (Fig. 5).

Increased ventricular size after infarction has other deleterious effects on myocardial function that intensifies congestive heart failure. Mitral leaflet coaptation is reduced as the papillary muscles widen, causing tethering of the mitral apparatus. The

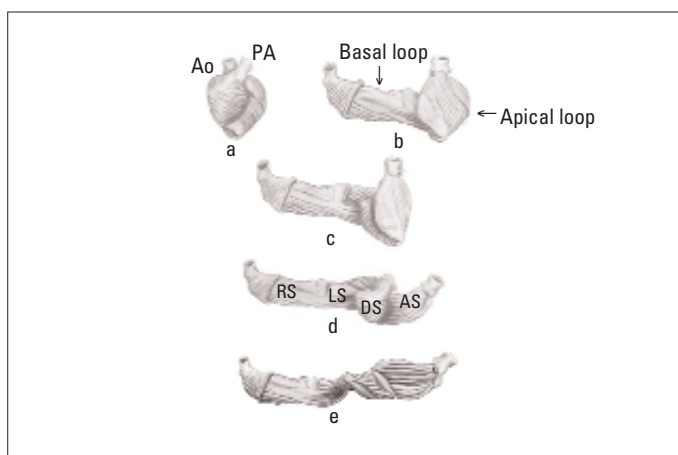


Figure 1. The myocardial band of Torrent-Guasp: a) the intact heart, b) partially unfolded, showing the transverse fibers of the basal loop, and oblique fibers of apical loop, c) further unfolding showing basal loop surrounding left ventricle, d) unfolding of apical loop, now displaying the right and left segments (RS, LS) of basal loop and descending and ascending segments (DS, AS) of apical loop

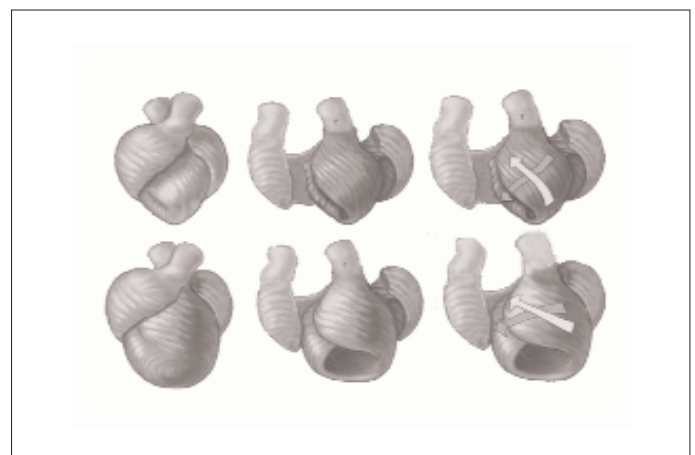


Figure 2. Geometric changes from normal heart (above) dilated heart (below). Note that normal heart has oblique apical loop fibers coursing at 60°, and how the dilated heart after infarction (below) develops increased sphericity that results in realignment of apical loop fibers in a more transverse direction to more closely resemble horizontal apical loop fibers

ensuing mitral regurgitation raises ventricular volume reducing forward cardiac output. Increased ventricular size also promotes ventricular dysrhythmias and can cause dyssynchronous mechanical contraction. This may be a contributing factor in sudden death (10, 11).

Principles of surgical therapy

The goals of surgery are reduction in volume and restoration of shape toward normalcy. These are based on the principle outlined above, namely that form defines function. Surgical ventricular restoration refers to operations that treat patients with ventricular dilation and congestive heart failure after myocardial infarction. These include the classic left ventricular aneurysmectomy, either by plication or by endoaneurysmorrhaphy, described years ago and applied to thinned transmural scars resulting from coronary occlusions. In this era, such pathology is

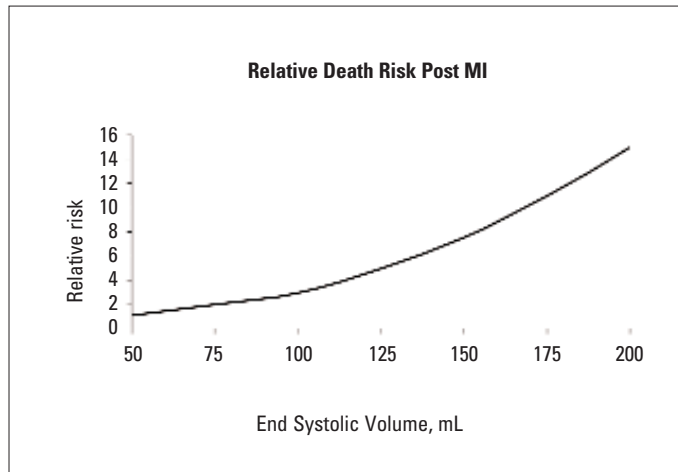


Figure 3. The risk of death after infarction is related to ventricular volume
MI - myocardial infarction (Modified from Reference No. 9)

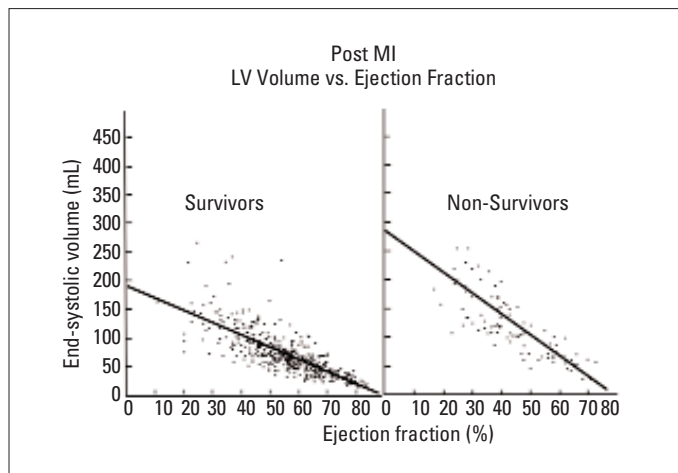


Figure 4. Comparison of ejection fraction and end systolic volume in survivors and non- survivors in White et al. study (9). Note higher volumes in non-survivors at the same ejection fraction, so that survival is related to volume rather than ejection fraction

LV- left ventricular, MI – myocardial infarction
(Reproduced from Reference No.9 with permission of LWW. Copyright 1987 American Heart Association)

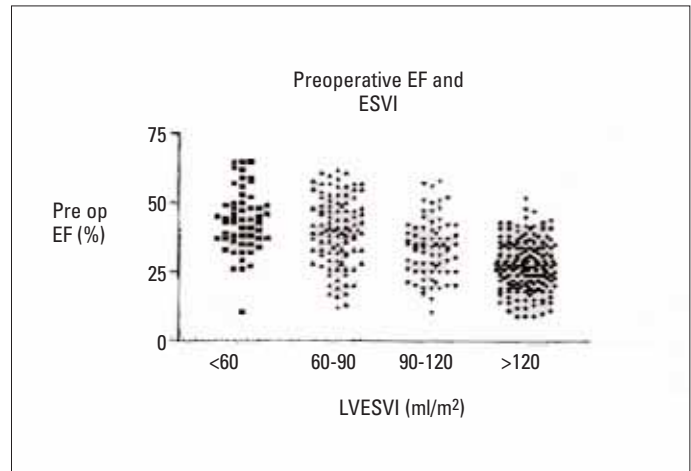


Figure 5. Ejection fraction in dilated cardiomyopathy is not directly related to ventricular volume as shown in this display of volume ranging from 60-120 ml/m². Note wide variation in volume at ejection fraction of 25%

EF - ejection fraction, LVESVI - left ventricular end-systolic volume
(Data from Dor V. The endoventricular circular patch plasty ("Dor procedure") in ischemic akinetic dilated ventricles. Heart Fail Rev 2001; 6: 187-93.)

rarely seen, since infarction is treated early and aggressively by coronary revascularization, either by thrombolysis or percutaneous intervention. Hence, the morphologic appearance of the post-infarct segment is not one of dyskinesia, but rather akinesia. Vincent Dor first described intraventricular infarct exclusion for the akinetic ventricle, recognizing that the adverse physiologic and hemodynamic consequences of ventricular dilation in the presence of akinesia or dyskinesia were the same (12, 13). During SVR, the infarcted segment of the left ventricle is excluded, usually with an intraventricular patch, thereby creating a smaller and more elliptical ventricular chamber (Fig. 6).

Surgical ventricular restoration should not be confused with partial left ventriculectomy, the so-called "Batista procedure", in which the lateral wall was resected to reduce ventricular volume in patients with dilated cardiomyopathy whose etiology was either ischemic or non-ischemic. This was a non-selective resection, and in cases of non-ischemic cardiomyopathy, often removed the segment of ventricle that was functional. Partial left ventriculectomy has largely been abandoned in the treatment of ischemic cardiomyopathy due to poor long-term outcomes (14).

Surgical ventricular restoration is not an isolated procedure. In fact, it usually is performed concomitantly with coronary bypass grafting and mitral valve repair when there is a significant functional mitral regurgitation. Attempts to treat ischemic mitral valve regurgitation at the annular level (ring annuloplasty) is not as predictable or durable as once thought, because the mechanism of such mitral regurgitation is related to the interaction of the mitral apparatus and the ventricle (15). Surgical ventricular restoration treats the three "Vs" of congestive heart failure: vessels, valve, and ventricle.

Preoperative evaluation

Candidates for the SVR operation typically have a history of remote infarction months to years prior to operation and symptoms of advanced congestive heart failure (NYHA class III or IV). Electrocardiography confirms prior infarction in all cases.

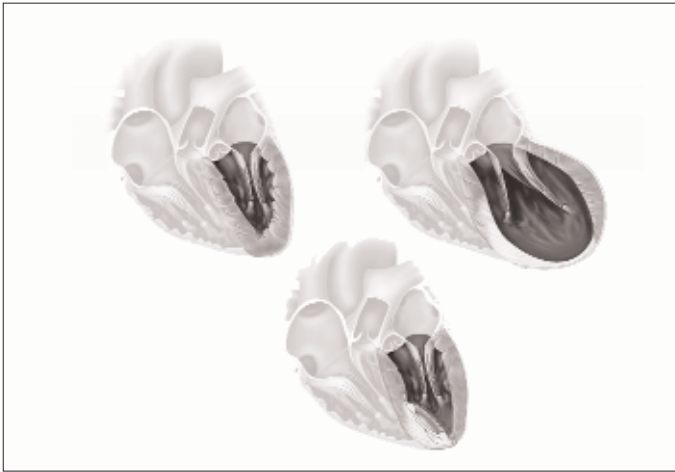

Figure 6. The normal elliptical shape of the heart (upper left) becomes spherical after infarction with scar shown in white shading (upper right). Lower image shows that surgical ventricular restoration reduces ventricular volume and restores ellipticity by placement of an intraventricular patch that excludes the scarred segment

Such patients may or may not have angina, but since coronary artery disease is the major causative factor, coronary angiography is essential. Evaluation of left ventricular size and function is crucial in assessing operability and determining adjunctive procedures. This is done with echocardiography, ventriculography or cardiac magnetic resonance imaging (CMR). Each method has advantages and limitations.

Echocardiography is readily available. It can be used to confirm ventricular enlargement by measurement of the short axis, calculate systolic ejection fraction, and determine diastolic function. Clinicians often report left ventricular end-diastolic dimension (LVEDD). This dimension is often misleading because it measures the distance between the bases of the papillary muscles. Anterior infarction often results in non-homogeneous structural changes and myocardial damage may occur distal to the traditional point of measurement. Consequently, LVEDD can be normal, even in the presence of a large akinetic or dyskinetic anteroseptal wall as a result of anterior myocardial infarction. Left ventricular end-diastolic dimension is more useful during the later stages of ventricular remodeling in ischemic cardiomyopathy after global dilation occurs and in non-ischemic cardiomyopathy with global dilation. The extent of regional asynergy of the infarcted segment can be visualized, as can the wall motion and thickness of the remote non-infarcted segments. An asynergic (non-contracting region with either akinesia or dyskinesia) area greater than 35% warrants intervention. After anterior myocardial infarction, the finding of normal motion and thickening of the lateral and inferior walls (remote muscle) is important in determining operability. Exact left ventricular volume determination by echocardiography is not very reliable and alternative methods are discussed below.

Ventriculography in the RAO view confirms asynergy of the anterior and apical segments after anterior infarction, but does not reveal septal or lateral wall function. These segments are best viewed in the left anterior oblique (LAO) view. Data from both views are used to determine left ventricular volume. If only a RAO view is available, volume will generally be underestimated, but

will at least confirm significant enlargement. Left ventricular end-systolic volume index greater than 60 ml/m² is a generally agreed threshold for surgical intervention.

If there is akinesia or severe hypokinesia of the remote non-infarcted segments due to ischemia or prior infarction, then myocardial viability tests are needed to determine the degree of reversible function. Dobutamine echocardiography is used for evaluation of viability. While thallium scintigraphy may be useful, it is limited because this test does not determine transmurality of the infarcted region. A major thickness of ventricle may be scar, but the veneer of normal epicardium may take up thallium and lead to false conclusions. Cardiac magnetic resonance imaging with delayed gadolinium enhancement is the most predictive test of viability and reversibility of function in hypokinetic segments following infarction (Fig. 7). Cardiac MRI allows determination of regional wall thickening and accurate calculation of global systolic ejection fraction. It is also the most accurate method of measuring ventricular volumes.

The preoperative workup is not complete without assessment of mitral valve function. Late failure of SVR is related to untreated mitral regurgitation at the initial operation (16). Global left ventricular enlargement can cause mitral regurgitation that occurs at rest or with exertion. The associated anatomic changes include annular dilatation, decreased leaflet coaptation, and widening of the papillary muscle insertion sites due to scar. The mitral valve function should be determined preoperatively by history, physical examination and echocardiography. We recommend mitral repair if there is 2 to 4+ mitral regurgitation, or if the mitral annulus exceeds 35 mm in diameter even in the absence of mitral regurgitation. In such cases, there is usually limited leaflet coaptation that may be functionally significant causing congestive symptoms with exercise. The vast majority of mitral interventions during SVR are mitral valve repair with annuloplasty. However, excessive scarring involving the inferior or lateral walls may warrant mitral valve replacement with preservation of the subvalvular apparatus.

SVR: the operation

Ventricular restoration requires sternotomy and cardiopulmonary bypass. In the majority of cases, coronary bypass and mitral valve repair with annuloplasty is done by conventional means with cardioplegic protection of the myocardium. The ventricular portion of the operation then follows. Some surgeons do this part of the operation with the heart arrested, and others prefer to allow the heart to beat. The empty, vented open heart allows for precise visual and palpable identification of the contracting and non-contracting segments. In either case, an encircling suture is placed in the myocardium at this juncture and tightened. This forms a ledge, or platform for the placement of an endovascular patch (Dacron or bovine). The residual myocardium is closed over this patch to aid in hemostasis. Alternately, some surgeons prefer to isolate the scarred segment by a series of circular sutures to reduce the ventricular volume. Postoperative management is routine and includes early use of beta-blockers and angiotensin-converting enzyme inhibitors. Oral anticoagulation is indicated if mitral valve repair is done, as usual, for three months. Aspirin is also prescribed if concomitant coronary bypass is performed.

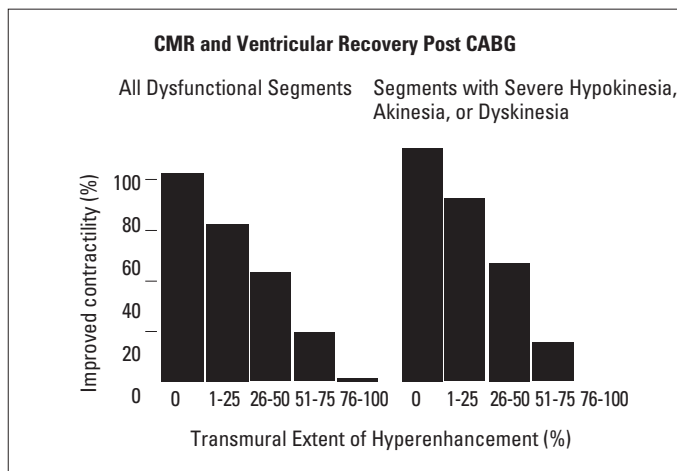


Figure 7. Cardiac magnetic resonance imaging is a reliable viability test. The transmural extent of hyperenhancement with gadolinium predicts recovery of contractility after revascularization. Note marginal recovery if transmural state of hyperenhancement is >50%

CABG-coronary artery bypass surgery, CMR-cardiac magnetic resonance imaging (Reproduced from Kim RJ, Wu E, Rafael A, Chen EL, Parker MA, Simonetti O, et al. The use of contrast-enhanced magnetic resonance imaging to identify reversible myocardial dysfunction. *New Engl J Med* 2000; 343: 1445-53, with permission of Massachusetts Medical Society. Copyrighted © 2000 Massachusetts Medical Society.)

Outcome of SVR surgery

Dor's experience in treating congestive heart failure by ventricular volume reduction inspired a multinational study of ventricular restoration (17). A collaborative group of cardiologists and cardiac surgeons (the RESTORE Group) from four continents (USA, Europe, Asia, South America) applied SVR in 1198 patients between 1998 and 2003 (30). Patients were included in the registry if SVR was performed for the following: prior anterior myocardial infarction with significant ventricular dilation (LVESVI ≥ 60 ml/m²), and a regional asynergic (non-contractile) area of $\geq 35\%$. Surgical ventricular restoration was most often done as a concomitant procedure: 90% received coronary bypass grafting and mitral valve repair was required in about 20%.

In the RESTORE registry, 86% of patients had NYHA class III/IV symptoms of CHF preoperatively. Such patients have a high mortality with medical therapy, or with surgical revascularization without left ventricular restoration, where late deaths are attributable mainly to CHF. Echocardiography, ventriculography or cardiac magnetic resonance angiography were used to confirm the asynergic area and calculate the ejection fraction. Left ventricular end-systolic volume was determined by ventriculography or CMR in all cases.

Hospital mortality after SVR was 5.3%, and increased as preoperative ventricular volume rose: 2.3% if LVESVI was < 60 ml/m², 5.7% if LVESVI was 60-90 ml/m², 8.1% if LVESVI was 90-120 ml/m² and 8.4% if LVESVI was >120 ml/m². These findings are comparable to recently reported mortality rates (5.5%-11%) in ischemic patients with left ventricular dysfunction (EF <35%) undergoing coronary artery bypass grafting alone. The addition of mitral valve repair influenced early outcome. Hospital mortality was 8.7% with mitral repair vs. 4.0% without repair (p<0.001). Perioperative mechanical support with intra-aortic balloon

pumping was uncommon (<9%). Global systolic function improved postoperatively as ejection fraction (EF) increased from 29.6 \pm 11.0% preoperatively to 39.5 \pm 12.3% postoperatively (p<0.001). Left ventricular end-systolic volume decreased from 80.4 \pm 51.4 ml/m² preoperatively to 56.6 \pm 34.3 ml/m² postoperatively (p<0.001).

The overall five-year probability of survival after SVR was 68.6 \pm 2.8% and confirms Dor's extensive experience. A detailed analysis of these findings has been reported for each volume subset (17). Multivariate analysis of SVR demonstrated that major risk factors were age, preoperative EF, LVESVI, and NYHA functional class.

The RESTORE data further emphasized the importance of measuring LVESVI as a surrogate marker of left ventricular function. Ejection fraction and LVESVI are not directly related, as there is a wide variation in volume for a given EF (33). Patients with preoperative LVESVI ≤ 80 ml/m² had long-term survival of 79.4 \pm 3.3% as compared to 67.2 \pm 3.2% for those with larger hearts. Preoperative NYHA functional class was also predictive of outcome with decreased five-year survival in patients with preoperative NYHA class IV symptoms (49.7 \pm 5.8% vs. 69.9 \pm 4.7% in class III). These predictors of long-term outcome after SVR are similar to those previously reported (18). A small number of patients (9%) with functional class I symptoms underwent SVR as an adjunct to coronary artery bypass surgery (CABG) because of ventricular dilation (LVESVI >60 ml/m²), which has been shown to be a precursor of late development of CHF and early death (7).

The experience of many other centers has confirmed the findings of the RESTORE group. The cumulative experience now includes seven thousand cases, and is increasing daily (12, 17-27) (Fig. 8). Despite this wide experience, only one study has matched patients with depressed systolic function treated by CABG alone vs. CABG and SVR (28). In this study, operative results were similar, but functional class, readmissions to the hospital for heart failure, and short-term survival were better in the SVR plus CABG group. The ultimate prospective trial to evaluate CABG vs. SVR plus CABG is an ongoing study called the STITCH trial, sponsored by the National Institute of Health in the USA. Whatever the upcoming results may be, these must be compared to the RESTORE data, which serve as a benchmark for surgical efficacy (29).

Physiologic and clinical effects of SVR

There are many measures of ventricular function in ischemic cardiomyopathy. One, which has received much attention, is asynchrony seen so often in diseased dilated hearts. Cardiac resynchronization therapy (CRT) has emerged as a major industry. Expensive implantable devices abound, but are ineffective in about a fourth of patients and investigators are still searching for criteria that identify failure of this treatment. An intriguing finding after SVR is the effect on ventricular synchrony. A recent analysis of 30 consecutive patients undergoing SVR showed that preoperative LV contraction was highly asynchronous, because pressure/volume (P/V) loops displayed abnormal isometric phases with a right shifting (6). Moreover, endocardial time motion was either early or delayed at the end-systolic phase as demonstrated by the pressure/length (P/L) loops, which were markedly abnormal in size, shape, and

SVR Experience 7251 patients						
Author	Year	Number of Patients	Operative Mortality, %	EF Change, %	LVESVI Change, %	5. Year Survival, %
RESTORE Athanasuleas (17)	2004	1198	5.3	10	29	68
Dor (12)	2004	1150	12			
Menicanti (19)	2002	1161	4.7	7	33	63 (10 years)
Mickleborough (20)	2004	285	2.8	10	33	82
Di Donato (18)	2001	245	8.1	13	48	82
Cirillo (21)	2004	69	4.3	15	47	
Calafiori (22)	2003	50	8			
Marchenko (23)	2005	66				60
Kalkat (24)	2006	102	7			65
Sartipy (25)	2005	101	7.9			
Bechtel (26)	2004	147	4.1			78
STS Database (27)	2002-2008	2677	7 (2008)			

Figure 8. SVR experience results in many worldwide centers demonstrating number of patients, survival and changes in ejection fraction and end systolic volume index

EF-ejection fraction, LVESVI-left ventricular end-systolic volume index, SVR-surgical ventricular restoration

orientation. Surgical ventricular restoration shifted the P/V loops leftwards towards normal and the P/L loops almost normalized demonstrating cardiac resynchronization (Fig. 9). Analysis of individual myocardial segments by the centerline method showed a remarkable return of synchrony following SVR (Fig. 10, 11) (6). Hemodynamic measurements after SVR indicated improved systolic function (EF increased from $30 \pm 13\%$ to $45 \pm 12\%$; $p=0.001$). Diastolic function also improved evidenced by a more rapid peak-filling rate.

Another intense focus of interest in the treatment of cardiomyopathy is that of arrhythmias. Implantable defibrillators have been routine in clinical practice and are used in patients with prior infarctions and EF below 35% (the MADIT criteria) (30). This treatment was stimulated by the SAVE (Survival and Ventricular Enlargement Trial) trial, which showed a correlation between ventricular arrhythmia and increased ventricular size and shape (31). Interestingly, SVR, by reducing ventricular size, also treats ventricular arrhythmias. In a subset of patients studied in the RESTORE group, investigators examined 382 patients with electrophysiological testing (32). They found a clear relationship between ventricular volume and arrhythmia (Fig. 12). Spontaneous ventricular arrhythmias were more common in the most dilated hearts (LVESVI $>120 \text{ ml/m}^2$), inducible events were more frequent if LVESVI was $100-120 \text{ ml/m}^2$, and no arrhythmias were induced if LVESVI was $<100 \text{ ml/m}^2$ (32). Surgical ventricular restoration reduced inducible ventricular tachycardia from 41% (144/352) preoperatively to 8% (26/307) at early study, and 8% (14/177) one year later (Fig. 13). Cardiac mortality was low at five years and not different between groups with and without evidence of spontaneous or inducible preoperative arrhythmias. If SVR had not been performed, many of these patients whose ejection fractions were below 35% might have otherwise undergone defibrillator placement as the MADIT criteria suggest. Very few patients (26 of 382) had postoperative induced arrhythmia by paired ventricular stimulation and were successfully treated with amiodarone.

Another salutary effect of SVR is its effect on the neurohumoral axis that aggravates and furthers heart failure. Norepinephrine, angiotensin II, and plasma renin activity fall after

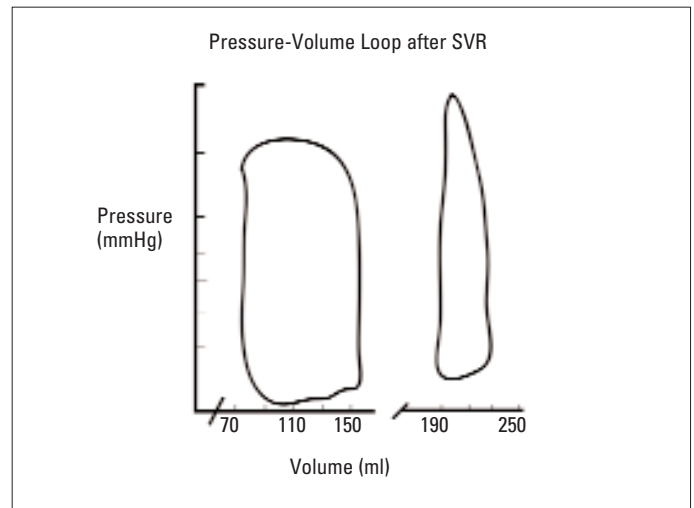


Figure 9. On the right is a preoperative P-V loop and on the left the P-V loop after SVR. Note normalization following rebuilding a conical chamber from the spherical form in heart failure patient

SVR-surgical ventricular restoration

(Reproduced from Reference N6 with permission of LWW. Copyright © 2004 American Heart Association, Inc.)

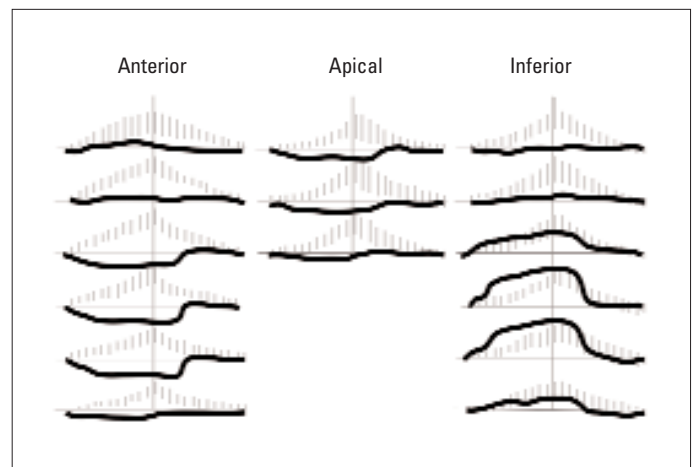


Figure 10. Myocardial segments analyzed by the centerline method. The center of each tracing represents the end of systole. The grey areas show the expected pattern in the normal heart and the black lines display dyssynchrony of anterior, apical and inferior segments in a patient with anterior myocardial infarction and scar

(Reproduced from Reference N6 with permission of LWW. Copyright © 2004 American Heart Association, Inc.)

operation as a consequence of the reduced ventricular stretch and this finding persists after one year (Fig. 14) (33). The full extent of this recovery may be delayed for over four months because of the turnover of collagen.

As we have seen, SVR reduces LV volume, changes LV shape, and improves global systolic function. Why this happens is postulated as follows: myocardial oxygen consumption (MVO₂) is closely related to wall tension, which in turn, is related to the radius of the ventricle. If the ventricle is spherical, then the ventricular volume (V) is related to radius (r) as follows: $V = 4/3\pi r^3$. Substituting this relationship into the LaPlace

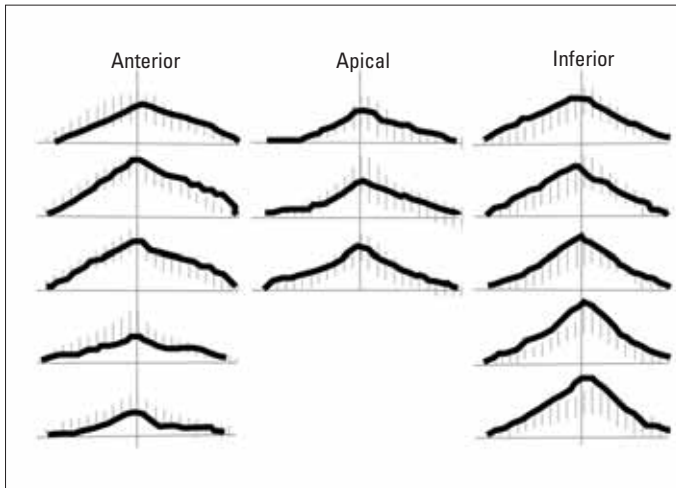


Figure 11. After SVR, ventricular synchrony is restored in all myocardial segments in this patient. Note how the black lines now mirror the normal pattern in the grey background

SVR - surgical ventricular restoration

(Reproduced from Reference N6 with permission of LWW. Copyright © 2004 American Heart Association, Inc.)

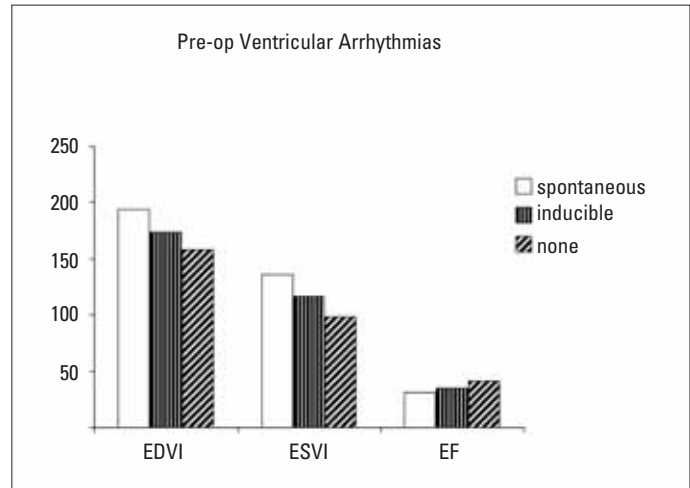


Figure 12. Preoperative ventricular arrhythmia following anterior infarction is related to ventricular volume and ejection fraction. Note that spontaneous arrhythmias are more common with larger volumes, inducible event at lesser volumes, and least events occur in smallest volumes

(Reproduced with kind permission from Springer Science+Business Media: Reference N 32. Copyright 2005 Springer Science + Business Media, Inc.)

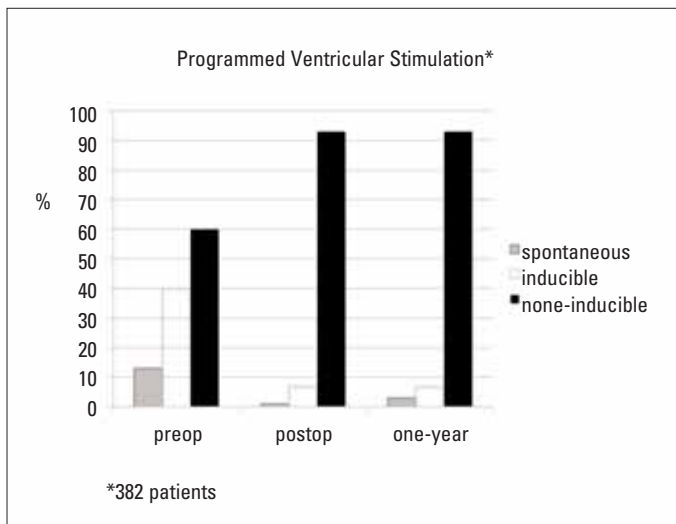


Figure 13. Electrophysiologic testing after SVR shows a reduction in arrhythmogenesis. Note that only 7% developed inducible arrhythmia following volume and shape rebuilding. A defibrillator was needed in only one patient in this 382 cohort of SVR patients

SVR – surgical ventricular restoration

(Data from Reference N 30)

relationship, tension (T) is related to $P \cdot 3 \cdot \sqrt{V}$. However, if the ventricle is cylindrical, then tension is reduced by its relation to the square of the radius: $P \cdot 2 \cdot \sqrt{V}$. Deformation increases and efficiency improves as the ventricle anisotropically thickens and the chamber dimension narrows towards the apex. Recovery of remote muscle function has been demonstrated after SVR by magnetic resonance tagging; circumferential shortening and deformation improved (34).

The final barometer of CHF treatment is clinical improvement. The five-year data from the RESTORE registry markedly improved

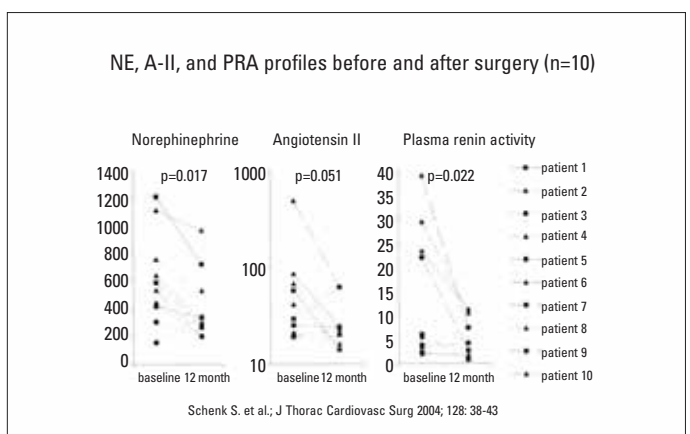


Figure 14. SVR reduces neurohumoral substances (norepinephrine, angiotensin II and plasma renin activity) that are responsible for per-sistent remodeling

A-II-angiotensin II, NE-norepinephrine, PRA -plasma renin activity, SVR-surgical ventricular restoration (Reproduced from reference N33, Copyright © 2004 by The American Association for Thoracic Surgery with permission from Elsevier)

NYHA functional class and resulted in a very low readmission rate for heart failure. Others have shown functional improvement after SVR by the six-minute walking test and improvement in quality of life by objective scoring (35). These findings are sustainable up to two years after operation and are consistent with those after heart transplantation.

Conclusion

Ventricular scar post-infarction is the “culprit lesion” that initiates and perpetuates a cascade of neurohumoral mediators in the heart leading to progressive left ventricular dysfunction and clinical symptoms of congestive heart failure. The morphological consequence of increased ventricular sphericity and volume are

treated by surgical ventricular restoration, an operation that reduces LV volume while reshaping the ventricle toward a more conical structure. Global systolic and diastolic ventricular function is improved, remote non-infarcted muscle function is enhanced, synchrony is restored, adverse neurohumoral mediators are turned off, and arrhythmogenesis is largely abated. The worldwide experience with SVR is now extensive and shows excellent functional and long-term outcomes. Cardiologists are encouraged to view these positive results in their evaluation of patients with dilated left ventricles and heart failure following myocardial infarction.

References

1. Gheorghiade M, Bonow RO. Chronic heart failure in the United States: a manifestation of coronary artery disease. *Circulation* 1998; 97: 282-9.
2. Torrent-Guasp F, Ballester M, Buckberg GD, Carreras F, Flotats A, Carrio I, et al. Spatial orientation of the ventricular muscle band: physiologic contribution and surgical implications. *J Thorac Cardiovasc Surg* 2001; 122: 389-92.
3. Buckberg GD. Basic science review: the helix and the heart. *J Thorac Cardiovasc Surg* 2002; 124: 863-83.
4. Ingels NB, Jr. Myocardial fiber architecture and left ventricular function. *Technol Health Care* 1997; 5: 45-52.
5. Bogaert J, Maes A, Van de Werf F, Bosmans H, Herregods MC, Nuyts J, et al. Functional recovery of subepicardial myocardial tissue in transmural myocardial infarction after successful reperfusion: an important contribution to the improvement of regional and global left ventricular function. *Circulation* 1999; 99: 36-43.
6. Di Donato M, Toso A, Dor V, Sabatier M, Barletta G, Menicanti L, et al. Surgical ventricular restoration improves mechanical intraventricular dyssynchrony in ischemic cardiomyopathy. *Circulation* 2004; 109: 2536-43.
7. Migrino RQ, Young JB, Ellis SG, White HD, Lundergan CF, Miller DP, et al. End-systolic volume index at 90 to 180 minutes into reperfusion therapy for acute myocardial infarction is a strong predictor of early and late mortality. The Global Utilization of Streptokinase and t-PA for Occluded Coronary Arteries (GUSTO)-I Angiographic Investigators. *Circulation* 1997; 96: 116-21.
8. Gaudron P, Eilles C, Kugler I, Ertl G. Progressive left ventricular dysfunction and remodeling after myocardial infarction. Potential mechanisms and early predictors. *Circulation* 1993; 87: 755-63.
9. White HD, Norris RM, Brown MA, Brandt PW, Whitlock RM, Wild CJ. Left ventricular end-systolic volume as the major determinant of survival after recovery from myocardial infarction. *Circulation* 1987; 76: 44-51.
10. Babuty D, Lab MJ. Mechanoelectric contributions to sudden cardiac death. *Cardiovasc Res* 2001; 50: 270-9.
11. Buckberg GD. Sudden cardiac death after heart failure; symptomatic versus disease treatment? An editorial comment. *Heart Fail Rev* 2004; 9: 347-51.
12. Dor V, Sabatier M, Montiglio F, Civaia F, DiDonato M. Endoventricular patch reconstruction of ischemic failing ventricle. a single center with 20 years experience. advantages of magnetic resonance imaging assessment. *Heart Fail Rev* 2004; 9: 269-86.
13. Dor V, Sabatier M, Montiglio F, Coste P, Di Donato M. Endoventricular patch reconstruction in large ischemic wall-motion abnormalities. *J Card Surg* 1999; 14: 46-52.
14. Ascione R, Lim KH, Chamberlain M, Al Ruzzeh S, Angelini GD. Early and late results of partial left ventriculectomy: single center experience and review of the literature. *J Card Surg* 2003; 18: 190-6.
15. Gillinov AM. Is ischemic mitral regurgitation an indication for surgical repair or replacement? *Heart Fail Rev* 2006; 11: 231-9.
16. Di Donato M, Sabatier M, Dor V, Gensini GF, Toso A, Maioli M, et al. Effects of the Dor procedure on left ventricular dimension and shape and geometric correlates of mitral regurgitation one year after surgery. *J Thorac Cardiovasc Surg* 2001; 121: 91-6.
17. Athanasuleas CL, Buckberg GD, Stanley AW, Siler W, Dor V, Di Donato M, et al. Surgical ventricular restoration in the treatment of congestive heart failure due to post-infarction ventricular dilation. *J Am Coll Cardiol* 2004; 44: 1439-45.
18. Di Donato M, Toso A, Maioli M, Sabatier M, Stanley AW, Jr., Dor V. Intermediate survival and predictors of death after surgical ventricular restoration. *Semin Thorac Cardiovasc Surg* 2001; 13: 468-75.
19. Menicanti L, Castelvechio S, Ranucci M, Frigiola A, Santambrogio C, de Vincentiis C, et al. Surgical therapy for ischemic heart failure: single-center experience with surgical anterior ventricular restoration. *J Thorac Cardiovasc Surg* 2007; 134: 433-41.
20. Mickleborough LL, Merchant N, Ivanov J, Rao V, Carson S. Left ventricular reconstruction: Early and late results. *J Thorac Cardiovasc Surg* 2004; 128: 27-37.
21. Cirillo M, Amaducci A, Brunelli F, Dalla Tomba M, Parrella P, Tasca G, et al. Determinants of postinfarction remodeling affect outcome and left ventricular geometry after surgical treatment of ischemic cardiomyopathy. *J Thorac Cardiovasc Surg* 2004; 127: 1648-56.
22. Calafiore AM, Gallina S, Di Mauro M, Pano M, Teodori G, Di Giammarco G, et al. Left ventricular aneurysmectomy: endoventricular circular patch plasty or septoexclusion. *J Card Surg* 2003; 18: 93-100.
23. Marchenko AV, Cherniavsky AM, Volokitina TL, Alsov SA, Karaskov AM. Left ventricular dimension and shape after postinfarction aneurysm repair. *Eur J Cardiothorac Surg* 2005; 27: 475-80.
24. Kalkat MS, Dandekar U, Smallpeice C, Parmar J, Satur C, Levine A. Left ventricular aneurysmectomy: tailored scar excision and linear closure. *Asian Cardiovasc Thorac Ann* 2006; 14: 231-4.
25. Sartipy U, Albage A, Lindblom D. The Dor procedure for left ventricular reconstruction. Ten-year clinical experience. *Eur J Cardiothorac Surg* 2005; 27: 1005-10.
26. Bechtel JM, Tolg R, Robinson DR, Graf B, Richardt G, Kraatz EG, et al. Results of endoaneurysmorrhaphy: does the location of the aneurysm matter? *Cardiovasc Surg* 2003; 11: 453-8.
27. Society for Thoracic Surgery National Database Executive Summary 2008. Available at: URL: http://www.sts.org/documents/pdf/ndb/Spring_2008_STSTHOR-ExecutiveSUMMARY.pdf
28. Prucz RB, Weiss ES, Patel ND, Nwakanma LU, Baumgartner WA, Conte JV. Coronary artery bypass grafting with or without surgical ventricular restoration: a comparison. *Ann Thorac Surg* 2008; 86: 806-14.
29. Subramanian H, Kunadian B, Dunning J. Is it worth performing surgical ventricular restoration in patients with ischemic cardiomyopathy and akinetic but non-aneurysmal segments in the left ventricle? *Interact Cardiovasc Thorac Surg* 2008; 7: 702-7.
30. Huang DT, Sesselberg HW, McNitt S, Noyes K, Andrews ML, Hall WJ, et al. Improved survival associated with prophylactic implantable defibrillators in elderly patients with prior myocardial infarction and depressed ventricular function: a MADIT-II substudy. *J Cardiovasc Electrophysiol* 2007; 18: 833-8.
31. St John Sutton M, Lee D, Rouleau JL, Goldman S, Plappert T, Braunwald E, et al. Left ventricular remodeling and ventricular arrhythmias after myocardial infarction. *Circulation* 2003; 107: 2577-82.
32. Di Donato M, Sabatier M, Dor V, Buckberg G, and the RESTORE Group. Ventricular arrhythmias after left ventricular remodeling: surgical ventricular restoration or ICD? *Heart Fail Rev* 2004; 9: 299-306.
33. Schenk S, McCarthy PM, Starling RC, Hoercher KJ, Hail MD, Ootaki Y, et al. Neurohormonal response to left ventricular reconstruction surgery in ischemic cardiomyopathy. *J Thorac Cardiovasc Surg* 2004; 128: 38-43.
34. Kramer CM, Magovern JA, Rogers WJ, Vido D, Savage EB. Reverse remodeling and improved regional function after repair of left ventricular aneurysm. *J Thorac Cardiovasc Surg* 2002; 123: 700-6.
35. Sartipy U, Albage A, Lindblom D. Improved health-related quality of life and functional status after surgical ventricular restoration. *Ann Thorac Surg* 2007; 83: 1381-7.