

subendocardium or subepicardium. The most commonly affected sites are left ventricle, right atrium and interatrial septum. The tumor in our case is located in the interventricular septum on the right ventricle side. Magnetic resonance signal characteristics of lipomas are quite specific; lipomas have high signal intensity on T1 and T2 weighted images and their signal are suppressed by fat suppression sequence and by this way cardiac MRI become diagnostic in this case. We described the rare case of a patient with right ventricular. This case underlines the usefulness of MRI for the evaluation of cardiac tumors, particularly lipomas.

**İlkay Erdoğan, Dursun Alehan, Tuncay Hazırolan\*, Mithat Haliloğlu\***  
From Departments of Pediatric Cardiology and \*Radiology, Faculty of Medicine, Hacettepe University, Ankara, Turkey

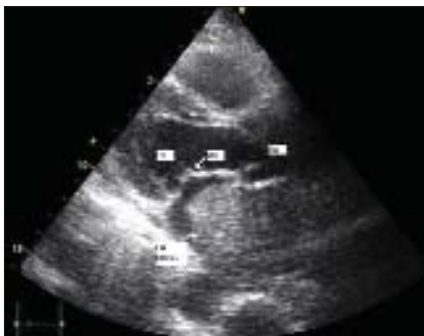**Address for Correspondence/Yazışma Adresi:** Dr. İlkay Erdoğan  
Hacettepe Üniversitesi, Çocuk kardiyolojisi, Ankara, Türkiye  
Phone: +90 312 475 74 03 Fax: +90 312 311 23 98  
E-mail: ilkayoerdogan@hotmail.com

## Giant metastatic left atrial tumor leading to pulmonary edema

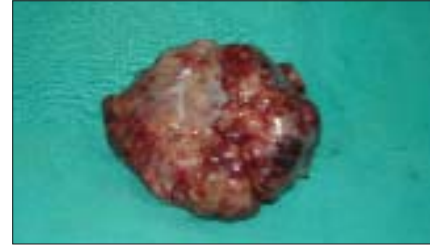

*Akciğer ödemeine yol açan dev sol atriyal metastatik tümör*

A 52-year-old male patient was referred to our hospital with complaints on worsened shortness of breath and cough. His general examination showed orthopnea and pain with palpation of right upper quadrant, bilateral jugular venous distension and diffuse crepitation rales in both lungs. His personal history revealed cigarette smoking for 30 years. Transthoracic and transesophageal echocardiographic examinations showed a partially mobile homogeneous mass with occasional lobulations completely occupying the left atrium (Fig. 1, Video 1. See corresponding video images at [www.anakarder.com](http://www.anakarder.com)). Other heart cavities were in normal size and their functions were normal. On his physical examination blood pressure was 120/80 mmHg, heart rate 100/min and first heart sound was decreased. Telecardiography showed presence of infiltration occupying half of his right lung and cardiothoracic index was increased in favor of the heart. His coronary angiography was normal. Upon worsening of his general condition, he has been referred for urgent surgical operation. During the surgery, a gray-white colored, lobulated, encapsulated mass (6 x 5 x 3 cm) completely occupying the left atrium was excised (Fig. 2). Pneumonectomy was not performed. During the surgery it was observed that the mass was organized and no embolism was present. No complications associated with the mass occurred during and after excision. Pathologic examination of the mass led to a diagnosis of metastatic carcinoma of pulmonary vein origin. Follow-up echocardiography at the



**Figure 1. Echocardiography view of the left atrial mass**



**Figure 2. Pathology specimen of left atrial mass, removed during surgery**

postoperative period showed normal findings except for an insignificant mitral regurgitation. The patient with no postoperational complications was discharged with a recommendation for follow-up by oncology outpatient clinic.

While pulmonary edema is a commonly encountered clinical condition, we believe that it is important to consider left atrial metastatic tumors.

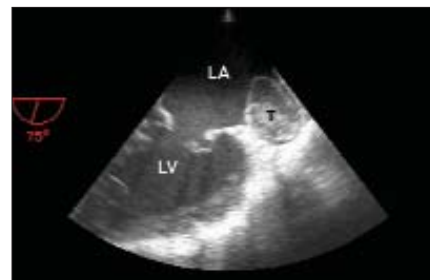
**Ibrahim Halil Kurt, Alaaddin Pekedis\***  
From Departments of Cardiology and \*Cardiovascular Surgery, Adana Numune Education and Research Hospital, Adana, Turkey

**Address for Correspondence/Yazışma Adresi:** Dr. Ibrahim Halil Kurt  
Department of Cardiology, Adana Numune Education and Research Hospital, Adana, Turkey  
Phone: +90 322 4583252 Fax: +90 3224595163 E-mail: ibrahimhalilkurt@gmail.com

## Ball thrombus in ligated left atrial appendage

*Bağlanmış sol atriyal apendiks içinde top trombüs*

A 40-year-old woman with paroxysmal atrial fibrillation was admitted to our hospital because of shortness of breath (NYHA III), palpitations and fatigue. Fifteen years earlier, the patient had been performed closed mitral commissurotomy. On physical examination, the blood pressure was 100/60 mm Hg and the heart rate was irregular at 95 beats/min. A 12-lead electrocardiogram showed atrial fibrillation. On admission, the patient had jugular venous distention to the angle of the jaw and trace peripheral edema. Full blood count and blood biochemistry were normal. As transthoracic echocardiography showed a suspect thrombus in the left atrium and severe mitral stenosis (mitral valve area=1.4 cm<sup>2</sup>, calculated by pressure half-time method), Transesophageal echocardiography (TEE) was performed. The TEE confirmed the presence of a



**Figure 1. Transesophageal echocardiography shows ball thrombus in ligated left atrial appendage.**

LA - left atrium, LV - left ventricle, T - thrombus

mobile thrombus (2.4x2.5 cm) in the left atrial appendage (Fig. 1). The patient underwent surgery, which included removal of the thrombus from the left atrium and replacement of mitral valve with a 27-mm bileaflet mechanical valve. The patient was discharged without any complication.

Ligation of the left atrial appendage (LAA) is commonly performed during mitral valve surgery because of the LAA is a frequent site of clot formation in patients with mitral valve disease, especially in those with atrial fibrillation. We have reported a case of ball thrombus developed in a mitral stenosis patient with ligated left atrial appendage.

**Şakir Arslan, Fuat Gündoğdu, Serdar Sevimli, Bilgehan Erkut\***  
From Departments of Cardiology and  
\*Cardiovascular surgery, Faculty of Medicine,  
Atatürk University, Erzurum, Turkey

**Address for Correspondence/Yazışma Adresi:** Dr. Şakir Arslan,  
Departments of Cardiology, Faculty of Medicine,  
Atatürk University Erzurum Turkey  
Phone: +90 4423166333 Fax: +90 442 316 63 33 E-mail: sarslan@atauni.edu.tr

Chiari network is a congenital remnant of the right valve of the sinus venosus and first described by Hans Chiari in 1897. Its prevalence is estimated to be around 2% in the general population. Although Chiari network is often considered clinically insignificant it may be associated with persistence of patent foramen ovale, formation of atrial septal aneurysm, catheter entrapment, paradoxical embolism, infective endocarditis and atrial tachyarrhythmias. It also poses diagnostic difficulties during echocardiography where it could be confused with right atrial thrombi, tumors, right heart vegetations, flail tricuspid leaflet, or a ruptured chordae tendinae.

**Lütfü Bekar, Orhan Önal, Fatih Altunkaş, Hasan Atmaca,  
İlksen Atasoy, Köksal Ceyhan**  
Department of Cardiology, Faculty of Medicine,  
Gaziosmanpaşa University, Tokat, Turkey

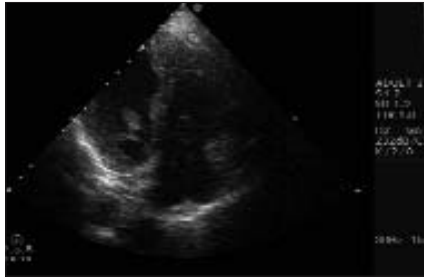
**Address for Correspondence/Yazışma Adresi:** Orhan Onalan, MD  
Department of Cardiology, Faculty of Medicine, Gaziosmanpaşa University,  
60100 Tokat, Turkey  
Phone: +90 356 2291469 Fax: +90 356 2291654 E-mail: oonalan@gmail.com

## A prominent Chiari network prolapsing into right ventricle

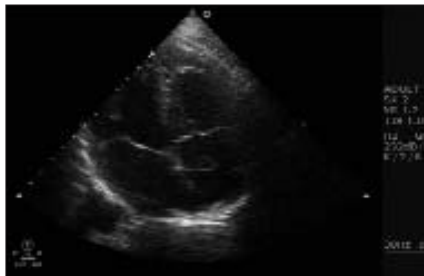


*Sağ ventriküle prolabe olan belirgin Chiari ağı*

A 42 years old male patient was referred to our clinic for palpitations. Physical examination revealed a low intensity systolic murmur at the mitral valve area. His heart rate was 65 beats/min and his blood pressure was 130/80 mm Hg. Electrocardiography showed sinus rhythm and normal axis. Echocardiography revealed a freely mobile, thin, filamentous structure in the right atrium, moving rapidly in and out of the right ventricle through the tricuspid orifice (Fig.1, 2, Video 1. See corresponding video/movie images at [www.anakarder.com](http://www.anakarder.com)).



**Figure 1. Echocardiographic view of Chiari network prolapsing through tricuspid orifice into right ventricle**



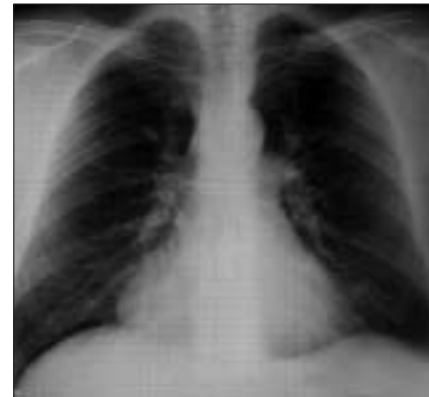**Figure 2. Echocardiographic view of Chiari network in right atrium**

## Management of an enlarging pericardial cyst

*Büyümüş perikardiyal kistin tedavisi*

A 37- year old man was referred to our institution from another hospital. On his examination, an abnormal structure adjacent to the right cardiac border was detected on plain chest roentgenogram (Fig. 1). Computerized tomography (CT) revealed a round, homogenous mass with dimensions of 4x6 cm, which was adjacent to the right cardiac border (Fig. 2). Echocardiography demonstrated a cystic mass adjacent to the right atrium. According to these results; the mass was considered as a benign pericardial cyst and routine follow-up was decided. The patient was invited for medical evaluation in every three months. At the second year of follow-up, CT and echocardiography showed a gradual enlargement in the mass size up to 6 x 8.5 cm. The patient was found to have effort related angina, along with the mild compression of the mass on right atrium, which was detected by echocardiography. As a result; surgical excision of the mass was planned to relieve his symptoms and to rule out malignancy.

The patient underwent operation. Following median sternotomy, the mass was explored. It was a cystic structure, filled with clear yellow fluid and attached to the right side of the pericardium with a generous fat pad.



**Figure 1. Chest X-ray image of a mass at the right cardiophrenic sinus**