

A rare radiodiagnostic finding: Porcelain atrium

A 76-year-old male patient was admitted to our hospital for further cardiac evaluation for shortness of breath. His history revealed a mitral valve replacement via a left atrial (LA) approach 25 years ago for severe rheumatic mitral stenosis, diabetes mellitus, and persistent atrial fibrillation. There was no evidence of LA calcification at that time. Physical examination revealed crackles in both lung bases. Electrocardiography revealed atrial fibrillation rhythm with a ventricular rate of 78 beats/min. Chest radiography showed diffuse calcified outline of the LA wall (Fig. 1). Transthoracic echocardiography revealed a normally functioning prosthetic mitral valve and LA and left ventricular enlargement. Ejection fraction was 30%, subsequently, computed tomography (CT) of the thorax to delimit this finding was obtained, which confirmed calcification outlining the LA free wall. CT revealed extensive and diffuse calcification of the LA free wall, except in the interatrial septum, which has been described as a "porcelain atrium" (Fig. 2). Under conservative management including medications with diuretics and vasodilators, his symptoms improved.

Massive calcification of the LA wall, also known as "porcelain atrium" or "mold-like calcification," is a rare condition commonly associated with long-standing rheumatic valve disease or extensive rheumatic pancarditis. The interatrial septum is often spared. Complete calcification of the LA wall including the interatrial septum is termed as "coconut atrium." Although without immediate consequences, it predisposes to atrial fibrillation, embolization, and pulmonary congestion due to noncompliance of the LA. Familiarity with radiographic features of this unique

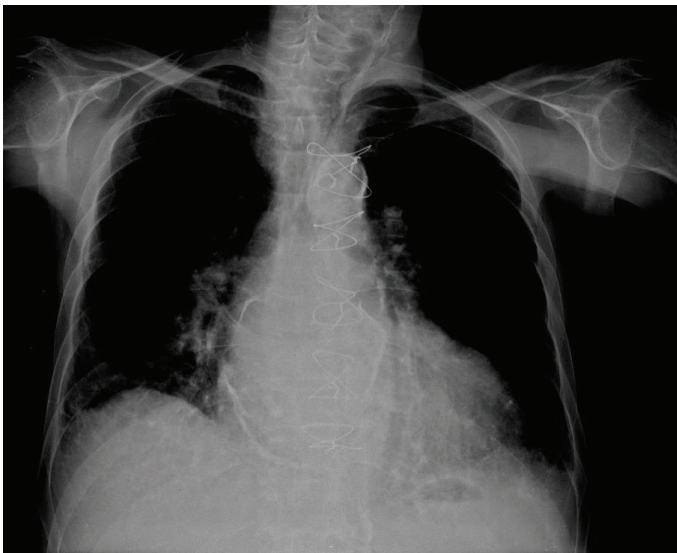


Figure 1. Chest radiography showing diffuse calcified outline of the left atrial wall

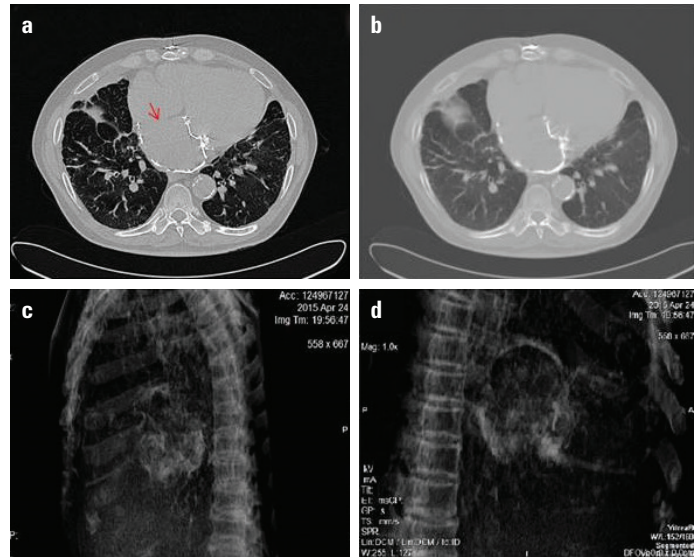


Figure 2. Multislice contrast-enhanced computed tomography (CT) of the thorax. Axial (a and b) and sagittal (c and d) images showing extensive and diffuse calcification outlining the LA free wall, except in the interatrial septum (red arrow)

distribution of calcium in the correct clinical setting will allow prompt recognition when interpreting chest X-rays and CT images. Present findings suggest that a long-standing rheumatic inflammation resulted in LA calcification after mitral valve replacement.

Yalçın Velibey, Sinan Şahin*, Tolga Sinan Güvenç, Özlem Yıldırım Türk

Departments of Cardiology and *Radiology, Siyami Ersek Thoracic and Cardiovascular Surgery Center, Training and Research Hospital, İstanbul-Turkey

Address for Correspondence: Dr. Yalçın Velibey

Dr. Siyami Ersek Hastanesi, Tıbbiye Cad. No:25

Üsküdar / İstanbul-Türkiye

Phone: +90 216 444 52 57

Fax: +90 216 337 97 19

E-mail: dr_yalchin_dr@yahoo.com.tr

©Copyright 2017 by Turkish Society of Cardiology - Available online at www.anatoljcardiol.com

DOI:10.14744/AnatolJCardiol.2017.8115

A rare cause of pericardial tamponade: Chylopericardium 🎥

A 56-year-old woman presented at our emergency clinic with dyspnea. She had a history of lung carcinoma, which was diagnosed 2 weeks ago. She was advised chemotherapy, but she did not start the treatment. Her blood pressure, heart rate, respiration rate, and oxygen saturation were 95/55 mm Hg, 103 beats/min, 18 breaths/min, and 92%, respectively. Her physical examination

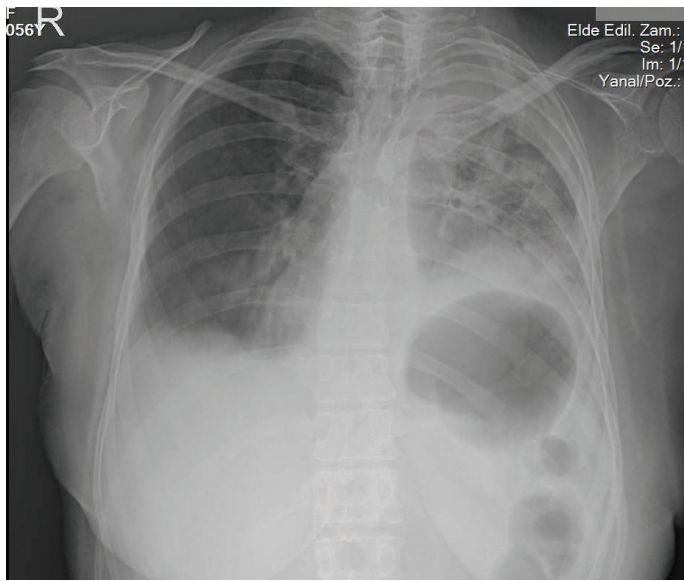


Figure 1. PA chest X-ray showed enlarged cardiac silhouette, blunted costophrenic sinuses, and consolidation of the left lung

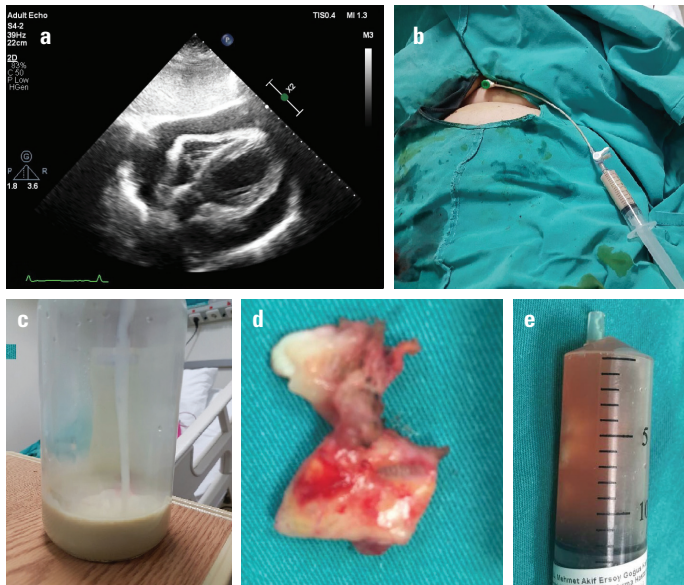


Figure 2. (a) Transthoracic echocardiography (subcostal view) showed massive pericardial effusion. (b) A 6F sheath was placed into the pericardial cavity via the subxiphoid approach. (c) A total of 300 mL of chylous effusion was drained. (d) 3x2 cm of thickened pericardium was excised during subxiphoid pericardiostomy. (e) Serous effusion was drained during subxiphoid pericardiostomy

revealed decreased breath sound at bases and decreased heart sounds. ECG showed sinus tachycardia. Chest X-ray revealed enlarged cardiac silhouette, blunted costophrenic sinuses, and consolidation of the left lung (Fig. 1). Echocardiography demonstrated massive pericardial effusion causing tamponade (Fig. 2A). Percutaneous drainage via subxiphoid puncture was attempted. After several failed punctures, a thick and white fluid was aspirated (Video 1). After confirmation of the intrapericardial position using agitated saline, a 6F sheath was placed (Fig. 2B), and 300 mL of fluid was drained (Fig. 2C). Biochemical evalua-

tion of the fluid revealed that the triglyceride level was above the highest limit. The patient was hemodynamically and clinically stable during 3 days of hospitalization. Ten days after discharge, the patient was readmitted to the emergency department due to dyspnea. Echocardiography showed pericardial effusion and tamponade. The cardiac team decided to perform a pericardial window (subxiphoid pericardiostomy). Surgery revealed a thickened pericardium and serous effusion (Fig. 2D and E). The patient died 2 months after the procedure due to pneumonia. Chylous pericardial effusion is the rarest cause of fluids causing tamponade. It usually occurs after surgery or trauma due to thoracic duct injury. In our case, we believe that the invasion of carcinoma in the thoracic duct or small lymphatic channels of the pericardium caused chylous effusion.

Video 1. A thick and white fluid was aspirated during puncture.

Semi Öztürk, Gündüz Durmuş, Hicaz Zencirkıran Ağuş*, Hatice Alıcı Koç, Mehmet Mustafa Can**
Department of Cardiology, Haseki Training and Research Hospital, İstanbul-Turkey
Department of *Cardiology, **Thoracic Surgery, Mehmet Akif Ersoy Thoracic and Cardiovascular Surgery Training and Research Hospital, İstanbul-Turkey

Address for Correspondence: Dr. Semi Öztürk
 Haseki Eğitim ve Araştırma Hastanesi
 Kardiyoloji Kliniği, Vatan Caddesi 29 Mayıs Sokak 34250
 Fatih, İstanbul-Türkiye
 Phone: +90 212 532 29 25, +90 212 531 51 04
 Fax: +90 212 589 62 29

E-mail: semi_ozturk@yahoo.com

©Copyright 2017 by Turkish Society of Cardiology - Available online at www.anatoljcardiol.com

DOI: 10.14744/AnatolJCardiol.2017.8166

Effusive constrictive pericarditis diagnosed with PET/CT and treated medically

An 80-year-old woman presented to the emergency department due to dyspnea for 3 weeks. She was admitted to the hospital with a diagnosis of massive pleural effusion. Thoracentesis revealed a transudative effusion. Adenosine deaminase level in the fluid was 12 U/L (normal range, 0–40 U/L), and erythrocyte sedimentation rate was 94 mm/h. Control chest X-ray examination revealed cardiomegaly (Fig. 1). Transthoracic echocardiography revealed hyperechogenic pericardial effusion (Fig. 2, Panels A and B; Videos 1 and 2). Inferior vena cava plethora with blunted respiratory response was present (Fig. 2, Panel C). Significant respiratory variation in mitral inflow was observed (Fig. 2, Panel D). PET/CT revealed 20 mm of pericardial effusion and increased FDG uptake in the pericardium with an SUVmax of 19.3 (Fig. 2, Panels