

# Left pericardial agenesis in a patient with sinus venosus type atrial septal defect

*Sinüs venozus tip atriyal septal defektli hastada sol perikardiyal agenezi*

*Zeynep Eyileten, Mehmet Arikbuka, Levent Yazıcıoğlu, Ümit Özyurda*

Department of Cardiovascular Surgery, School of Medicine, Ankara University, Ankara, Turkey

## Introduction

A congenital pericardial defect (CPD) is extremely rare anomaly and it maybe either complete or partial (1). Congenital pericardial defect was first described by the anatomist Realdus Columbus in 1559 (2). Left-sided defects are most common (86%), and they usually occur in male (3:1) (1-3). Most patients with CPD are asymptomatic. But symptoms may come up with life-threatening complications.

Although CPD is usually isolated, one third of all cases are associated with other cardiovascular or pulmonary congenital anomalies (eg. atrial septal defect, patent ductus arteriosus, mitral stenosis, tricuspid insufficiency, tetralogy of Fallot, bronchogenic cyst). We reported a case of congenital left pericardial agenesis associated with the secundum type atrial septal defect (ASD).

## Case report

A 34 years old man admitted to our department with palpitations, restlessness on exertion and chest pain which was triggered on in supine and left lateral decubitus positions and disappeared by turning to the right side. The pain became more frequent for two years. The history was not contributory. On physical examination; blood pressure was 110/75 mm Hg, pulse was 92 beats/min and regular; neither cyanosis nor pallor was noticed. The apical impulse was displaced to the left and was prominent. There was a grade 2/6 systolic ejection murmur along the left border of the sternum. The second heart sound was widely split and fixed. The lung examination was normal in auscultation. Minimal hepatomegaly was noted. Electrocardiogram revealed normal sinus rhythm, incomplete right bundle branch block and right axis deviation. Chest X-ray (Fig. 1) showed mild widening of the mediastinal shadow, left displacement of the heart and loss of the right heart border with a convex prominence of the left border of the heart and pulmonary vascular engorgement. The routine biochemical and whole blood count were in normal range.

With these findings ASD was suspected and color-flow Doppler echocardiography was performed. Transthoracic and transesophageal echocardiography revealed sinus venosus type

ASD. The size of the shunt, measured by ratio of pulmonary-to-systemic flow ( $Q_p/Q_s$ ) was 1.8. Right sided cavities and pulmonary artery were slightly enlarged. The mean pulmonary artery pressure was 45 mmHg on Doppler echocardiographic examination.

There was an abnormal anteroposterior cardiac movement within the thoracic cavity and paradoxical interventricular septal motion. There were neither valvular problems nor contractility anomalies.

Cardiac catheterization confirmed echocardiographic findings and coronary arteries were normal.

The initial diagnosis was sinus venosus type ASD and the patient was referred for operation. At operation, after median sternotomy agenesis of whole left pericardium was noted. Heart was slightly displaced to the left, pulmonary venous connection was normal (Fig 2, 3). The atrial septum was repaired primarily by cardiopulmonary bypass. We did not reconstruct the deficit of the pericardium because of the minimal possibility of cardiac displacement.

The postoperative course was uneventful and the patient was discharged on the 6th postoperative day in stable condition. There were no symptoms postoperatively at 6 months' follow-up.

## Discussion

A congenital pericardial defect is a rare clinical condition, most commonly involving the left pericardium (86%) (1-3). The anomaly is more common in male (3:1). In most cases, the anomaly had been found incidentally without any significant clinical symptoms. The reported incidence of isolated congenital pericardial defects in anatomopathologic series is 1/14000 (1).

The main cause of the left-sided defect is the premature atrophy of the left duct of Curvier, which leads to a deficiency in blood supply. This causes the persistence of the left pleuropericardial foramen (2).

Most patients especially with large pericardial defects are asymptomatic. The most common symptom is chest pain, which is typically precipitated by left lateral decubitus position and relieved by turning to the right (4). Sudden death may occur (1).

Chest pain symptoms are often attributed to coronary ischemia from the torsion of great vessels, herniation of cardiac structures through the pericardial defect and tension of the pleuropericardial adhesions (4). The reasons for sudden death maybe the herniation of the left ventricle, left appendage and the involvement of the left circumflex artery (1). Physical examination

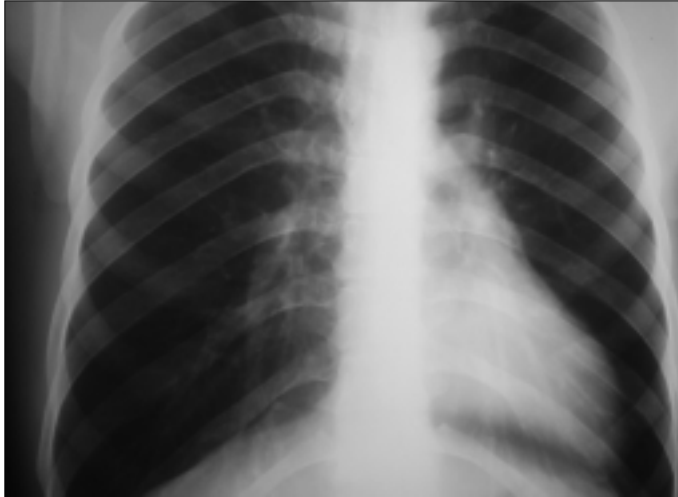


Figure 1. Preoperative chest X-ray of a patient with left ventricular pericardium agenesis

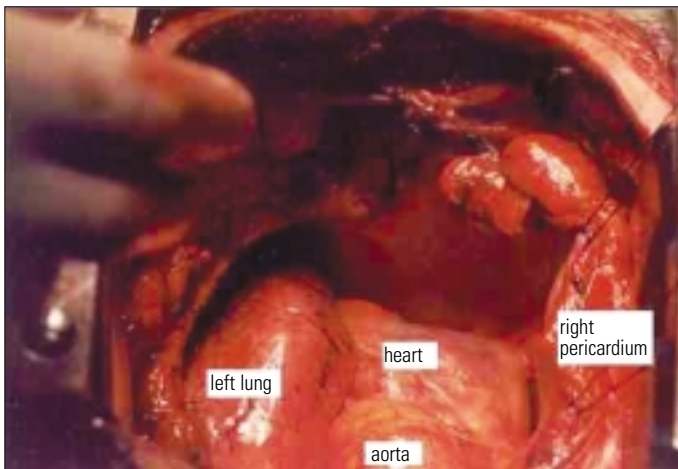


Figure 2. Left ventricular pericardium agenesis view from cranial side after sternotomy

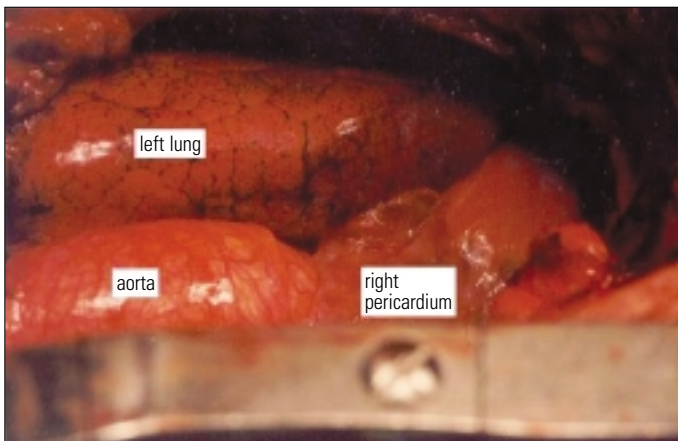


Figure 3. Left ventricular pericardium agenesis view from surgeon's side (right side of the patient)

reveals lateral displacement of the heart. On chest X-ray film; left lateral displacement of the heart, loss of the right heart border due to superimposing on the spine, the lung tissue interposing between the main pulmonary artery and the aorta, and the most common and diagnostic radiographic feature, irregular left heart border can be seen (4). On echocardiography, right ventricular dilatation and paradoxical septal motion are commonly seen, but ventricular function is usually normal (5). At cardiac catheterization, one can detect protruding of left atrial appendage through the defect (4,6). Magnetic resonance imaging is the most useful diagnostic test. It determines the extent of the defect, excludes herniation of cardiac structures and any additional defects (7,8). Video assisted thoracoscopy can also be helpful.

Congenital pericardial defects are usually isolated, but other congenital anomalies of heart and lung maybe seen in approximately one third of these patients (2). In this case, we present a rare case of left pericardial agenesis associated with sinus venosus type ASD.

In preoperative period, CPD was suspected from the echocardiographic findings. Since we would operate the patient for ASD repair, any additional test like magnetic resonance imaging to make distinct diagnosis was not performed.

If the patient is symptomatic or the defect is associated with other cardiac defects, surgery might be indicated. Because of the rarity of congenital pericardial defects and variability of their presentation, no standard surgical approach has been recommended. Surgical closure techniques of the defect consist of primary closure, patch closure, or widening of the defect depending on the anatomic size and location of the defect. If there is acute apical appendage strangulation, a left atrial appendectomy is also might be considered (4). Larger defects are typically well tolerated and repair can be technically difficult. Reconstruction is not recommended for such a large defect like in our case, because the heart typically adapts to the distorted anatomy and corrective attempts may result in unstable flow patterns (10).

## References

1. Rusk RA, Kenny A. Congenital pericardial defect presenting as chest pain. *Heart* 1999; 81: 327-8.
2. Lu C, Ridker PM. Echocardiographic diagnosis of congenital absence of the pericardium in a patient with VATER association defects. *Clin Cardiol* 1994; 17: 503-4.
3. Mashru MR, Amin SR, Desai AG, Daruwalla DF, Shah KD. Absent left pericardium. *J Assoc Physicians India* 1985; 33: 539-41.
4. Gatzoulis MA, Munk MD, Merchant N, Van Arsdell GS, McCrindle BW, Webb GD. Isolated congenital absence of the pericardium: clinical presentation, diagnosis, and management. *Ann Thorac Surg* 2000; 69: 1209-15.
5. Nicolosi GL, Borgioni L, Alberti E, Burelli C, Maffesant IM, Marino P, et al. M-Mode and two dimensional echocardiography in congenital absence of the pericardium. *Chest* 1982; 81:610-3.
6. Candan I, Erol C, Sonel A. Cross sectional echocardiographic appearance in presumed congenital absence of the left pericardium. *Br Heart J* 1986; 55: 405-7.
7. Schiavone WA, O'Donnell JK. Congenital absence of the left portion of parietal pericardium demonstrated by nuclear magnetic resonance imaging. *Am J Cardiol* 1985; 55: 1439-40.
8. Sechtem U, Tscholakoff D, Higgins CB. MRI of the normal pericardium. *Am J Roentgenol* 1986; 147: 239-44.
9. Sechtem U, Tscholakoff D, Higgins CB. MRI of the abnormal pericardium. *Am J Roentgenol* 1986;147: 245-52.
10. Firstenberg MS, Sai-Sudhakar CB, Raman SV, Michler RE. *Ann Thorac Surg* 2006; 81: 352-4.