

First experiences with the balloon-expandable Myval® transcatheter aortic valve from Turkey

Uğur Arslan, Güney Erdoğan, Melisa Uçar, Mustafa Yenerçağ

Department of Cardiology, University of Health Sciences, Samsun Training and Research Hospital; Samsun-Turkey

Introduction

Transcatheter aortic valve implantation (TAVI), first performed in inoperable patients with severe valvular aortic stenosis (AS), has become a surgical alternative even in low surgical risk patients based on the PARTNER-3 trial (1). TAVI valves can be classified into two categories: self-expandable and balloon-expandable. The experience of the operator and patients' clinical characteristics, such as aortoiliac-femoral access and distribution of calcium extending to left ventricular outflow tract (LVOT), are important for the choice of the valve. However, post-procedural aortic regurgitation and need for a permanent pacemaker are more commonly observed with self-expandable valves. Recent trials with the balloon-expandable SAPIEN 3 (Edwards Lifesciences, USA) valve have shown superior clinical results to the surgical aortic replacement and self-expandable valves (2). In our clinics, we prefer balloon-expandable valves because of its superiority, but in select cases which have extensive LVOT calcification and unsuitable peripheral access, the self-expandable Evolut-R (Medtronic, USA) valve is preferred.

The balloon-expandable Myval prosthetic valve (Meril Life Sciences, India), has been evaluated in the Myval-1 study (3) and has shown clinical efficacy and safety. In this study with 30 intermediate-to-high risk AS patients, all the procedures were successful with no paravalvular leaks or post-procedural permanent pacemaker implantations. A European Community mark has been given to this valve and Myval entered the market in Turkey earlier this year.

The structure of the Myval valve is like the SAPIEN-3 valve (Fig. 1a), but there are several differences which favor Myval. A

14-Fr expandable sheath is used during the insertion of the valve, which is smaller than the SAPIEN-XT or SAPIEN-3 entry system. Another difference is that it is crimped on the balloon catheter system, which may be an advantage because the SAPIEN valves are mounted on the balloon in the descending aorta. Sizes for larger aortic annuli (30.5 mm and 32 mm) are available for the

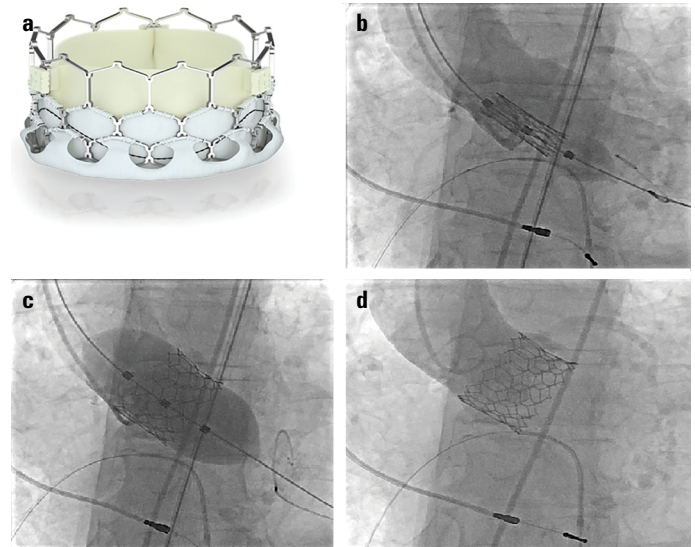


Figure 1. The Myval valve and its implantation procedure. (a) Structural appearance of the valve. (b) After positioning the aortic cusps in a straight line, valve is placed to the optimal position, then under rapid ventricular pacing, the balloon of the valve is inflated a bit and the dog-bone appearance occurs. Just at this time aortography is performed to prove the correct position of the valve. (c) The balloon is fully inflated still under rapid pacing. (d) After deflating the balloon, the valve is implanted to the correct position. In aortography, no aortic regurgitation is observed

Address for correspondence: Dr. Uğur Arslan, Sağlık Bilimleri Üniversitesi Samsun Eğitim ve Araştırma Hastanesi, Kardiyoloji Anabilim Dalı, Samsun-Türkiye
Phone: +90 532 603 99 83 E-mail: ugurarслан5@yahoo.com

Accepted Date: 28.08.2020 **Available Online Date:** 19.11.2020

©Copyright 2020 by Turkish Society of Cardiology - Available online at www.anatoljcardiol.com
DOI:10.14744/AnatolJCardiol.2020.93584



Myval valve. Intermediate sizes (21.5 mm, 24.5 mm, and 27.5 mm) are available which decrease the risk of annular rupture, a serious complication of balloon-expandable valves. These sizes are expected to be available in Turkey soon.

Balloon pre-dilatation is recommended before the Myval valve implantation. Because of our experience in SAPIEN XT and SAPIEN 3 valves, we do not routinely perform pre-dilatation when inserting the balloon-expandable valves. Direct TAVI has also been shown as effective and safe as TAVI procedures with pre-dilatation (4). Pre-dilatation is performed when the operator feels that the passage of the AL-1 or AL-2 diagnostic catheter through the aortic valve is difficult with the straight 0.035" wire.

In this article, we present our experiences with the first 9 TAVI procedures using the Myval valve in June and July 2020. The clinical, electrocardiographic, and procedural characteristics of the patients are summarized in Table 1. In all the patients, the TAVI procedure succeeded. The procedural technique is like the SAPIEN XT and 3 valve implantation (Fig. 1a-1d). Video 1 shows one TAVI procedure with the Myval valve. As we have mentioned, the differences were the lower profile sheath used for the entry and the valve itself, which is mounted on the balloon outside the body, not in the descending aorta. A marker can be placed in the middle of the valve between other two markers showing the proximal and distal edges of the valve. This marker helps align the valve to the aortic annulus, which should be at the level of the lower border of the non-coronary cusp).

Under mild or no sedation, our TAVI procedures were performed via 14Fr sheath using 2 ProGlide pre-closure systems (Abbott Vascular, USA). We performed these cases without pre-dilatation, and no difficulty was observed during the valvular passage and implantation. No death or cerebrovascular event was recorded during hospitalization. Post-procedural mean transvalvular gradient was 9±2 mm Hg. Mild paravalvular regurgitation was observed only in one patient. A permanent pacemaker was also implanted in one patient after the procedure. In this patient, when the straight 0.035" wire passed into the left ventricle, a complete atrioventricular block developed which had not resolved 48 hours after the procedure. In eight patients, the procedural time was less than one hour and in one patient, because of severe peripheral tortuosity, it was 110 minutes. Two patients were discharged on the second day, 6 patients on the third day, and only one patient on the fourth day after valvular implantation.

The development of this transcatheter Myval system is important because of the relatively lower cost when compared to the other balloon-expandable TAVI systems and its efficacy, which is comparable to the SAPIEN-3 valve (3). Longer term follow-up studies are needed to see the durability of the valve. However, Myval TAVI system is operator friendly because of the lower entry profile, which allows its use in patients with poor vascular access. The intermediate sizes are expected to decrease the risk of annular rupture.

Table 1. The clinical characteristics of 9 patients undergoing TAVI with Myval valve

Patients	Age	Sex	STS score	Aortic gradients (max-mean) (mm Hg)	AVA (cm ²)	Aortic annular area (mm ²)	Size of Myval Valve (mm)	Pre-dilatation	Post-dilatation	Post-imp. mean gradients (mm Hg)	Post-imp. AR	Baseline ECG	Post-procedural immediate ECG	Pre-discharge ECG	Complication
Patient 1	73	M	10.8	87/56	0.7	460	26	No	No	10	No	SR (QRS: 90 msec)	SR, incomplete LBBB (QRS: 110 msec)	SR (QRS: 90 msec)	No
Patient 2	71	M	10.2	74/46	0.8	730	29	No	No	10	No	SR, LVH voltage criteria	SR, LVH voltage criteria	SR, LVH voltage criteria	No
Patient 3	85	M	11.1	71/41	0.7	475	26	No	No	9	No	AF (QRS: 80 msec)	Complete AV block	Pace rhythm	AV block
Patient 4	81	M	10.3	99/55	0.7	660	29	No	No	8	No	SR, LBBB (QRS: 150 msec)	SR, LBBB (QRS: 160 msec)	SR, LBBB (QRS: 150 msec)	No
Patient 5	76	F	5.1	75/48	0.8	510	26	No	No	7	No	NSR	NSR	NSR	No
Patient 6	91	M	10.9	80/51	0.7	670	29	No	No	10	Mild	SR, LVH voltage criteria (QRS: 120 msec)	SR, LBBB (QRS: 160 msec)	SR, LVH voltage criteria (QRS: 120 msec)	No
Patient 7	72	M	10.7	70/45	0.9	485	26	No	No	9	No	SR, LVH voltage criteria (QRS: 110 msec)	SR, LVH voltage criteria (QRS: 110 msec)	SR, LVH voltage criteria (QRS: 110 msec)	No
Patient 8	78	F	11.7	72/45	0.8	370	23	No	No	8	No	Pace rhythm	Pace rhythm	Pace rhythm	No
Patient 9	78	M	8.1	100/60	0.6	565	29	No	No	10	No	SR, LVH voltage criteria (QRS: 110 msec)	SR, nonspecific IVCD (QRS: 130 msec)	SR, LVH voltage criteria (QRS: 110 msec)	No

STS - Society of Thoracic Surgeons, ECG - electrocardiogram, AVA - aortic valve area, AR - aortic regurgitation, SR - sinus rhythm, LBBB - left bundle branch block, LVH - left ventricular hypertrophy, AF - atrial fibrillation, AV - atrioventricular, IVCD - intraventricular conduction defect

Conclusion

In this article, we have presented our positive experience with the Myval valve. Long-term studies of this new valve are in progress. We believe that use of this valve will increase worldwide after these trials because of its ease of implantation and favorable hemodynamic profile.

Video 1. Implantation of the Myval valve to the aortic position

Conflict of interest: None declared.

Peer-review: Internally peer-reviewed.

Authorship contributions: Concept – U.A., G.E., M.U., M.Y.; Design – U.A., G.E., M.Y.; Supervision – U.A., M.Y.; Fundings – U.A., M.U.; Materials – U.A., G.E., M.U.; Data collection &/or processing – U.A., M.U.; Analysis &/or interpretation – U.A., G.E.; Literature search – U.A., M.Y.; Writing – U.A.; Critical review – U.A., G.E., M.Y.

References

1. Leon MB, Smith CR, Mack M, Miller DC, Moses JW, Svensson LG, et al.; PARTNER Trial Investigators. Transcatheter aortic-valve implantation for aortic stenosis in patients who cannot undergo surgery. *N Engl J Med* 2010; 363: 1597-607. [\[CrossRef\]](#)
2. Chamandi C, Puri R, Rodriguez-Gabella T, Rodés-Cabau J. Latest-Generation Transcatheter Aortic Valve Replacement Devices and Procedures. *Can J Cardiol* 2017; 33: 1082-90. [\[CrossRef\]](#)
3. Sharma SK, Rao RS, Chandra P, Goel PK, Bharadwaj P, Joseph G, et al.; Collaborators. First-in-human evaluation of a novel balloon-expandable transcatheter heart valve in patients with severe symptomatic native aortic stenosis: the MyVal-1 study. *EuroIntervention* 2020; 16: 421-9. [\[CrossRef\]](#)
4. Leclercq F, Robert P, Akodad M, Macia JC, Gandet T, Delseny D, et al. Prior Balloon Valvuloplasty Versus Direct Transcatheter Aortic Valve Replacement: Results From the DIRECTAVI Trial. *JACC Cardiovasc Interv* 2020; 13: 594-602. [\[CrossRef\]](#)