

Huge Pseudoaneurysm Presenting with Silent Myocardial Infarction and Stroke

A 51-year-old male patient, who had a short-term loss of consciousness, was admitted to the emergency department. The patient had right hemiparesis and a flattened right nasolabial sulcus. The initial troponin level was 31 ng/L, and it increased to 1502 ng/L in the second hour, revealing a giant 9 cm diameter pseudoaneurysm with a mobile thrombus on echocardiography (Figure 1). Bidirectional blood flow was detected within the aneurysm sac (Video 1). A small focal diffusion restriction at the vertex level in the right frontal lobe and diffuse cortical diffusion restriction in the bilateral posterior parietal lobes were observed (Figure 1). The patient was admitted to the coronary intensive care unit with a diagnosis of acute MI, acute ischemic cerebrovascular disease, and giant left ventricular pseudoaneurysm, and medical treatment was started. After 5 days of inpatient medical treatment, the patient was discharged.

Left ventricular aneurysms are rare, with an estimated incidence of <2% after acute myocardial infarction. Ventricular aneurysms most commonly occur after acute myocardial infarction. It can also be encountered in the postpartum period.¹ Locations of pseudoaneurysms vary according to etiology. Post-MI aneurysms are frequently located in the inferior or posterior lateral wall.² In our patient, it was located in the apical segment. Thrombus develops in 40–65% of left ventricular aneurysms due to stasis in the aneurysm sac.³ Diagnosis of a pseudoaneurysm may be difficult if not considered in patients with a previous acute myocardial infarction. Distinguishing between true and pseudoaneurysm is crucial for the choice of the treatment option.

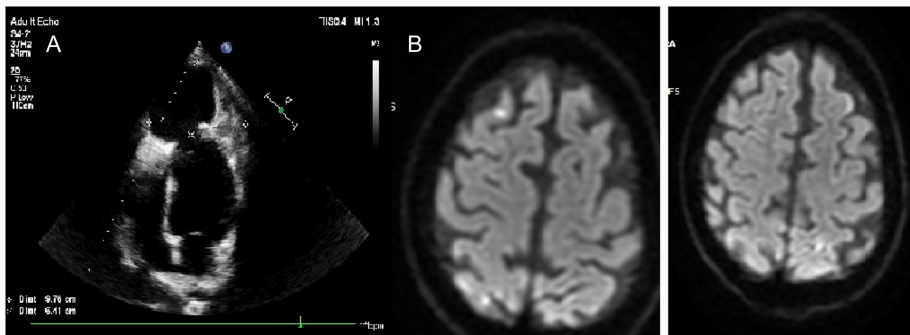


Figure 1. (A) A transthoracic echocardiography was performed in the emergency department, revealing a giant 9 cm diameter pseudoaneurysm with a mobile thrombus. (B) On diffusion-weighted magnetic resonance imaging, a small focal diffusion restriction at the vertex level in the right frontal lobe and diffuse cortical diffusion restriction in the bilateral posterior parietal lobes were observed.

E-PAGE ORIGINAL IMAGE



Muhammed İkbâl Şaşmaz¹

Bülent Demir¹

Mustafa Uçar²

Akkan Avcı¹

¹Department of Emergency Medicine, Celal Bayar University, Faculty of Medicine, Manisa, Türkiye

²Department of Cardiology, Celal Bayar University, Faculty of Medicine, Manisa, Türkiye

Corresponding author:

Akkan Avcı

✉ drakkanavci@gmail.com

Cite this article as: Şaşmaz Mİ, Demir B, Uçar M, Avcı A. Huge pseudoaneurysm presenting with silent myocardial infarction and stroke. *Anatol J Cardiol.* 2024;28(6):E-24-E-25.



Copyright©Author(s) - Available online at anatoljcardiol.com.
Content of this journal is licensed under a Creative Commons Attribution-NonCommercial 4.0 International License.

DOI:10.14744/AnatolJCardiol.2024.4431

Availability of data and materials: Data and materials are available from hospital automation information systems.

Informed Consent: Written informed consent was obtained from the patient for publication of this case and any accompanying images.

Declaration of Interests: The authors have no conflicts of interest to declare.

Funding: This research did not receive any specific grant from funding agencies in the public, commercial, or not-for-profit sectors.

Video 1: Bidirectional blood flow was detected within the aneurysm sac.

REFERENCES

1. Sharma A, Kumar S. Overview of left ventricular outpouchings on cardiac magnetic resonance imaging. *Cardiovasc Diagn Ther.* 2015;5(6):464-470. [\[CrossRef\]](#)
2. Yeo TC, Malouf JF, Oh JK, Seward JB. Clinical profile and outcome in 52 patients with cardiac pseudoaneurysm. *Ann Intern Med.* 1998;128(4):299-305. [\[CrossRef\]](#)
3. Incognito C, Parker J, Arustamyan M, Matta M, Posadas K, Lee R. Large left ventricular pseudoaneurysm presenting as an embolic stroke after a "silent" myocardial infarction. *Tex Heart Inst J.* 2023;50(2):e227922. [\[CrossRef\]](#)